



**NONRESIDENT  
TRAINING  
COURSE**

October 1999



---

# **Dental Technician, Volume 2**

**NAVEDTRA 14275**

Although the words "he," "him," and "his" are used sparingly in this course to enhance communication, they are not intended to be gender driven or to affront or discriminate against anyone.

## PREFACE

By enrolling in this self-study course, you have demonstrated a desire to improve yourself and the Navy. Remember, however, this self-study course is only one part of the total Navy training program. Practical experience, schools, selected reading, and your desire to succeed are also necessary to successfully round out a fully meaningful training program.

**THE COURSE:** This self-study course is organized into subject matter areas, each containing learning objectives to help you determine what you should learn along with text and illustrations to help you understand the information. The subject matter reflects day-to-day requirements and experiences of personnel in the rating or skill area. It also reflects guidance provided by Enlisted Community Managers (ECMs) and other senior personnel, technical references, instructions, etc., and either the occupational or naval standards, which are listed in the *Manual of Navy Enlisted Manpower Personnel Classifications and Occupational Standards*, NAVPERS 18068.

**THE QUESTIONS:** The questions that appear in this course are designed to help you understand the material in the text.

**VALUE:** In completing this course, you will improve your military and professional knowledge. Importantly, it can also help you study for the Navy-wide advancement in rate examination. If you are studying and discover a reference in the text to another publication for further information, look it up.

*1999 Edition Prepared by  
DTC(SW) J. Greg Longe and  
DTC(SW/AW) Cheral Wintling*

Published by  
NAVAL EDUCATION AND TRAINING  
PROFESSIONAL DEVELOPMENT  
AND TECHNOLOGY CENTER

**NAVSUP Logistics Tracking Number  
0504-LP-026-9060**

## **Sailor's Creed**

"I am a United States Sailor.

I will support and defend the  
Constitution of the United States of  
America and I will obey the orders  
of those appointed over me.

I represent the fighting spirit of the  
Navy and those who have gone  
before me to defend freedom and  
democracy around the world.

I proudly serve my country's Navy  
combat team with honor, courage  
and commitment.

I am committed to excellence and  
the fair treatment of all."

# CONTENTS

CHAPTER	Page
1. Dental Radiology. . . . .	1-1
2. Dental Examinations . . . . .	2-1
3. Preventive Dentistry. . . . .	3-1
4. Operative Dentistry. . . . .	4-1
5. Oral Surgery Assistance . . . . .	5-1
6. Periodontic Assistance . . . . .	6-1
7. Endodontic Assistance . . . . .	7-1
8. Prosthodontic Assistance . . . . .	8-1
9. Dental Treatment Room Emergencies . . . . .	9-1
10. Forensic Dentistry. . . . .	10-1
APPENDIX	
I. References Used to Develop This TRAMAN . . . . .	AI-1
INDEX. . . . .	INDEX-1

The Nonresident Training Course (NRTC) follows the Index

# INSTRUCTIONS FOR TAKING THE COURSE

## ASSIGNMENTS

The text pages that you are to study are listed at the beginning of each assignment. Study these pages carefully before attempting to answer the questions. Pay close attention to tables and illustrations and read the learning objectives. The learning objectives state what you should be able to do after studying the material. Answering the questions correctly helps you accomplish the objectives.

## SELECTING YOUR ANSWERS

Read each question carefully, then select the BEST answer. You may refer freely to the text. The answers must be the result of your own work and decisions. You are prohibited from referring to or copying the answers of others and from giving answers to anyone else taking the course.

## SUBMITTING YOUR ASSIGNMENTS

To have your assignments graded, you must be enrolled in the course with the Nonresident Training Course Administration Branch at the Naval Education and Training Professional Development and Technology Center (NETPDTC). Following enrollment, there are two ways of having your assignments graded: (1) use the Internet to submit your assignments as you complete them, or (2) send all the assignments at one time by mail to NETPDTC.

**Grading on the Internet:** Advantages to Internet grading are:

- you may submit your answers as soon as you complete an assignment, and
- you get your results faster; usually by the next working day (approximately 24 hours).

In addition to receiving grade results for each assignment, you will receive course completion confirmation once you have completed all the

assignments. To submit your assignment answers via the Internet, go to:

<http://courses.cnet.navy.mil>

**Grading by Mail:** When you submit answer sheets by mail, send all of your assignments at one time. Do NOT submit individual answer sheets for grading. Mail all of your assignments in an envelope, which you either provide yourself or obtain from your nearest Educational Services Officer (ESO). Submit answer sheets to:

COMMANDING OFFICER  
NETPDTC N331  
6490 SAUFLEY FIELD ROAD  
PENSACOLA FL 32559-5000

**Answer Sheets:** All courses include one “scannable” answer sheet for each assignment. These answer sheets are preprinted with your SSN, name, assignment number, and course number. Explanations for completing the answer sheets are on the answer sheet.

**Do not use answer sheet reproductions:** Use only the original answer sheets that we provide—reproductions will not work with our scanning equipment and cannot be processed.

Follow the instructions for marking your answers on the answer sheet. Be sure that blocks 1, 2, and 3 are filled in correctly. This information is necessary for your course to be properly processed and for you to receive credit for your work.

## COMPLETION TIME

Courses must be completed within 12 months from the date of enrollment. This includes time required to resubmit failed assignments.

## PASS/FAIL ASSIGNMENT PROCEDURES

If your overall course score is 3.2 or higher, you will pass the course and will not be required to resubmit assignments. Once your assignments have been graded you will receive course completion confirmation.

If you receive less than a 3.2 on any assignment and your overall course score is below 3.2, you will be given the opportunity to resubmit failed assignments. **You may resubmit failed assignments only once.** Internet students will receive notification when they have failed an assignment--they may then resubmit failed assignments on the web site. Internet students may view and print results for failed assignments from the web site. Students who submit by mail will receive a failing result letter and a new answer sheet for resubmission of each failed assignment.

## COMPLETION CONFIRMATION

After successfully completing this course, you will receive a letter of completion.

## ERRATA

Errata are used to correct minor errors or delete obsolete information in a course. Errata may also be used to provide instructions to the student. If a course has an errata, it will be included as the first page(s) after the front cover. Errata for all courses can be accessed and viewed/downloaded at:

<http://www.advancement.cnet.navy.mil>

## STUDENT FEEDBACK QUESTIONS

We value your suggestions, questions, and criticisms on our courses. If you would like to communicate with us regarding this course, we encourage you, if possible, to use e-mail. If you write or fax, please use a copy of the Student Comment form that follows this page.

## For subject matter questions:

E-mail: n313.products@cnet.navy.mil  
Phone: Comm: (850) 452-1001, Ext. 2169  
DSN: 922-1001, Ext. 2169  
FAX: (850) 452-1370  
(Do not fax answer sheets.)  
Address: COMMANDING OFFICER  
NETPDTC (CODE N313)  
6490 SAUFLEY FIELD ROAD  
PENSACOLA FL 32509-5237

## For enrollment, shipping, grading, or completion letter questions

E-mail: fleetservices@cnet.navy.mil  
Phone: Toll Free: 877-264-8583  
Comm: (850) 452-151/1181/1859  
DSN: 922-1511/1181/1859  
FAX: (850) 452-1370  
(Do not fax answer sheets.)  
Address: COMMANDING OFFICER  
NETPDTC (CODE N331)  
6490 SAUFLEY FIELD ROAD  
PENSACOLA FL 32559-5000

## NAVAL RESERVE RETIREMENT CREDIT

If you are a member of the Naval Reserve, you will receive retirement points if you are authorized to receive them under current directives governing retirement of Naval Reserve personnel. For Naval Reserve retirement, this course is evaluated at 9 points. (Refer to *Administrative Procedures for Naval Reservists on Inactive Duty*, BUPERSINST 1001.39, for more information about retirement points.)

## COURSE OBJECTIVES

In completing this nonresident training course, you will demonstrate a knowledge of the subject matter by correctly answering questions on the following subjects: dental radiology and examinations; preventive and operative dentistry; oral surgery, periodontic, endodontic, and prosthodontic assistance; dental treatment room emergencies, and forensic dentistry.





## Student Comments

**Course Title:** Dental Technician, Volume 2

**NAVEDTRA:** 14275 **Date:** \_\_\_\_\_

**We need some information about you:**

Rate/Rank and Name: \_\_\_\_\_ SSN: \_\_\_\_\_ Command/Unit \_\_\_\_\_

Street Address: \_\_\_\_\_ City: \_\_\_\_\_ State/FPO: \_\_\_\_\_ Zip \_\_\_\_\_

**Your comments, suggestions, etc.:**

<p><b>Privacy Act Statement:</b> Under authority of Title 5, USC 301, information regarding your military status is requested in processing your comments and in preparing a reply. This information will not be divulged without written authorization to anyone other than those within DOD for official use in determining performance.</p>
------------------------------------------------------------------------------------------------------------------------------------------------------------------------------------------------------------------------------------------------------------------------------------------------------------------------------------------------

NETPDTC 1550/41 (Rev 4-00)



# CHAPTER 1

## DENTAL RADIOLOGY

### INTRODUCTION

The purpose of dental radiography is to record images of a patient's oral structures on film by using X-rays. When the X-ray films are processed, the resulting radiographs provide the dental officer with a valuable diagnostic aid. In the case of death, radiographs can be used to aid in identification as discussed in chapter 10, "Forensic Dentistry."

The first section of this chapter covers the basic fundamentals of dental radiography. Included are the physics and biology of radiography.

Since X-radiation can be harmful, you must observe certain safety precautions when using an X-ray machine or working in an area where one is being used. These precautions are covered in the second part of this chapter.

The major portion of this chapter is devoted to explaining how to operate a dental X-ray machine, expose intraoral radiographs (radiographs taken inside the patient's mouth), process the X-ray films, and mount the finished radiographs.

The last part of this chapter covers the panoramic X-ray machine, which you will use to make extraoral radiographs (radiographs made outside the patient's mouth).

### FUNDAMENTALS OF DENTAL RADIOLOGY

Oral radiography is the art of recording images of a patient's oral structures on film by using X-rays (roentgen rays). The rays were recognition of Wilhelm Konrad Roentgen, a scientist, who first discovered X-rays in 1895. While experimenting with a device called a Crookes tube, which generated cathode rays, he noted that a photographic plate completely wrapped in black paper and lying near the tube was fogged when developed. He realized that some form of invisible ray, able to pass through the black paper, must be coming from the tube. Later, while in his darkened laboratory, he noticed that a fluorescent screen located six feet away was glowing. He knew that the cathode rays could travel only short distances outside the cathode tube and realized he was

observing a new, unknown ray, which he called an X-ray because the symbol "X" is used for the unknown in mathematics.

The first dental radiograph was taken the same year by Dr. Otto Walkoff. Within 10 years, radiographs were being used for diagnosis of medical and dental conditions, for X-ray therapy, and for scientific studies. Although technology over the years has made tremendous improvements in X-ray equipment, the basic concepts are the same.

Like visible light rays, X-rays are electromagnetic rays that travel in a wave motion. The measurement of this wave motion is called a wavelength. The basic difference between X-rays and other electromagnetic rays is in their wavelength. X-rays have an extremely short wavelength, which enables them to penetrate matter that usually absorbs or reflects light or other electromagnetic rays with longer wave-lengths.

Although X-rays share the properties of other electromagnetic rays, their action is considerably different. Some of the characteristics and properties of X-rays are:

- They travel in straight lines at the speed of light.
- They affect photographic film by producing a hidden image made visible by processing.
- They cause certain substances to fluoresce (glow).
- They cause irritation of living cells and, in large amounts, can cause necrosis (death) of the cells, a fact that necessitates caution in using X-rays.

X-rays are produced when a metal (tungsten) target is bombarded by a stream of electrons. The X-rays are emitted in the tubehead and directed by the tubehead cone through the subject, producing an image on the film.

The density of the X-ray image is controlled by four factors: kilovoltage (kVp), exposure time, milliamperage (mA), and target-film distance (TFD). All of these factors are interrelated and may be varied by the operator. The procedures for setting these factors will be discussed later.

## RADIATION SAFETY

Proper safety precautions must be observed by all persons working in or near an area where X-rays are being generated. X-rays can be dangerous. Long term overexposure to radiation may result in loss of hair, redness and inflammation of the skin, blood count change, cell atrophy (wasting away), ulcerations, sterility, genetic damage, cancer, leukemia, and death.


There are safety measures designed to protect the patient and the health care team from the dangers of overexposure to radiation and the operation of X-ray equipment. You must observe these safety measures when working in radiology. Your command will have instructions and standard operating procedures (SOP) for the operation of dental radiographic (X-ray) units and equipment. You will be required to read these procedures if you are newly assigned to the radiology department. There are other numerous responsibilities that include providing radiology support for oral diagnosis, log maintenance, infection control, testing for quality control, and processor maintenance.

### PATIENT PROTECTION

A number of precautions are taken to prevent the patient from being exposed to inappropriate diagnostic radiation. The decision to order dental radiographs is determined by the dental officer on a case by case basis for each patient. **Only** a dental officer is authorized to order and diagnostically interpret dental radiographs.

Perhaps the most important safety measure is the responsibility of the assistant: **When taking radiographs, you should always have patients wear lead aprons and thyroid collars to shield their reproductive organs and thyroid glands. There is only one exception to this rule; when obtaining a panorex radiograph, the thyroid collar is not used since it blocks part of the X-ray beam.** In addition, always ask a female patient whether or not she is pregnant or if pregnancy is questionable, before taking radiographs. If she is pregnant, consult the dental officer.

Other radiation safety measures include X-ray machines that have built-in safeguards that filter out harmful radiation and restrict the central X-ray to the smallest possible area. Fast film is used to shorten exposure time; and only essential radiographs are taken on patients.



DTV2f101

Figure 1-1.—Environmental dosimetry radiation film badge.

### ASSISTANT PROTECTION

When you work near a source of radiation, your X-ray department will be issued an environmental dosimetry radiation film badge (fig. 1-1).

Appropriately placed environmental film badges are used to monitor stray radiation that may occur in and around the X-ray department. The badges are placed in the X-ray room behind the technicians protective lead-lined barrier or at least 6 feet from the tube head and never in the direct line of radiation during exposure. These film badges contain X-ray sensitive film in a light-tight packet. The film packets are collected every 6 to 7 weeks. After collection, the film is sent to the radiation detection laboratory for processing and evaluation. Any abnormally high readings (i.e., greater than 0.010 REM [Radiological Equivalent Mammel]) shall be referred to the Radiation Health Office for investigation.

When you take radiographs on a patient, observe the following precautions to avoid unnecessary exposure to radiation:

- NEVER stand in the path of the central X-ray beam during exposure.
- NEVER hold the X-ray film packet in the patient's mouth during exposure.
- NEVER hold the tube head or the tube head cylinder of the X-ray machine during exposure.
- ALWAYS stand behind a lead-lined screen during an exposure.

### X-RAY FILM LOG

Another portion of radiation safety is to account for all radiographs that are taken. An X-ray film log

shall be maintained in all X-ray rooms and will contain the following information:

- Column 1: Patient's Name
- Column 2: Patient's SSN
- Column 3: Patient's Unit
- Column 4: Rank/Rate/Retired/Dependent/etc.
- Column 5: Number of X-ray exposures and type: bitewing, periapical, occlusal, panograph
- Column 6: kVp, mA, exposure time
- Column 7: Reason retake X-ray required (if applicable)

When stating the reason for a retake X-ray, be specific on the nature of the retake, for example: conecut, elongated, foreshortened, dark image, etc.

### DENTAL X-RAY MACHINES

The most commonly used X-ray machine is the wall-mounted dental X-ray unit (fig. 1-2). Because the

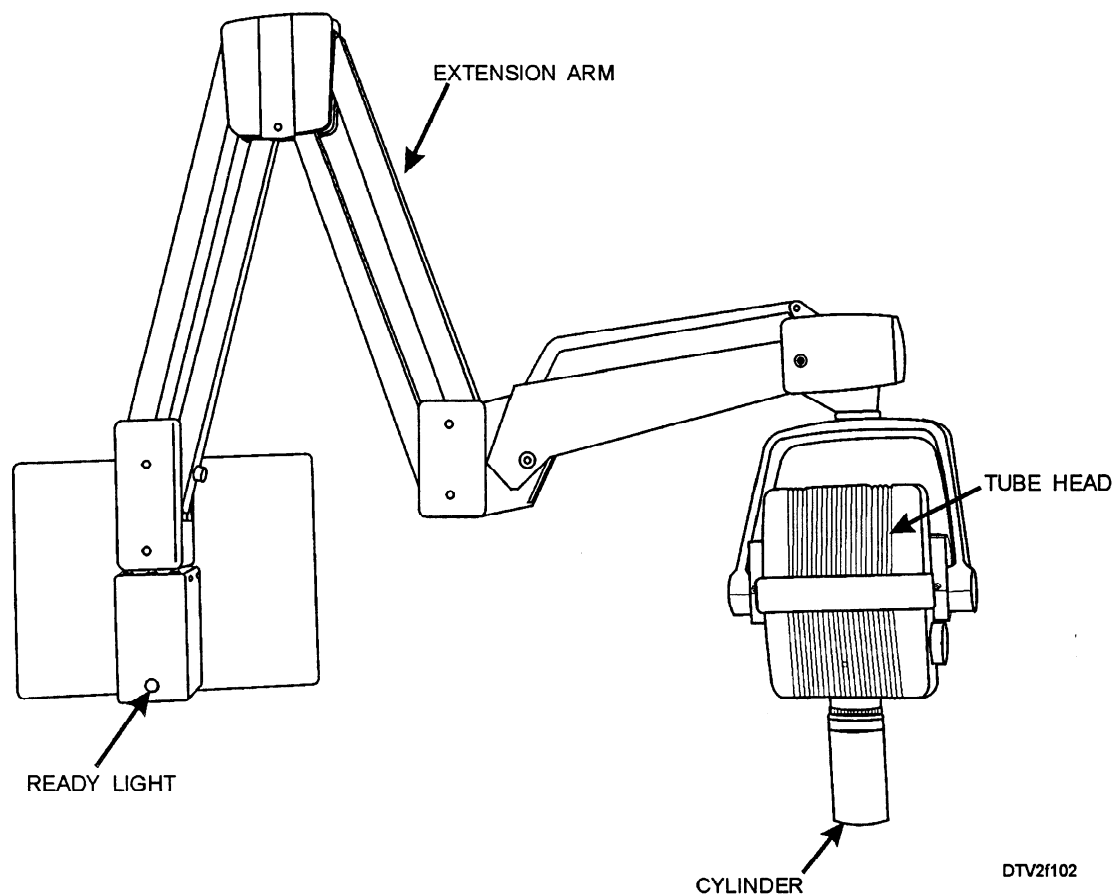
basic components and operating techniques of all dental X-ray machines are similar, we will only discuss the wall-mounted unit. The component parts of the wall-mounted machine discussed here are the tube head, cylinder, extension arm, ready light, and a separate control panel.

### TUBE HEAD

The tube head (fig. 1-3) contains the X-ray tube and other components necessary for generating X-rays. When an exposure is made, X-rays pass through an aluminum filter that screens out unnecessary radiation. Angulation scales are on both sides of the tube head for precise positioning technique.

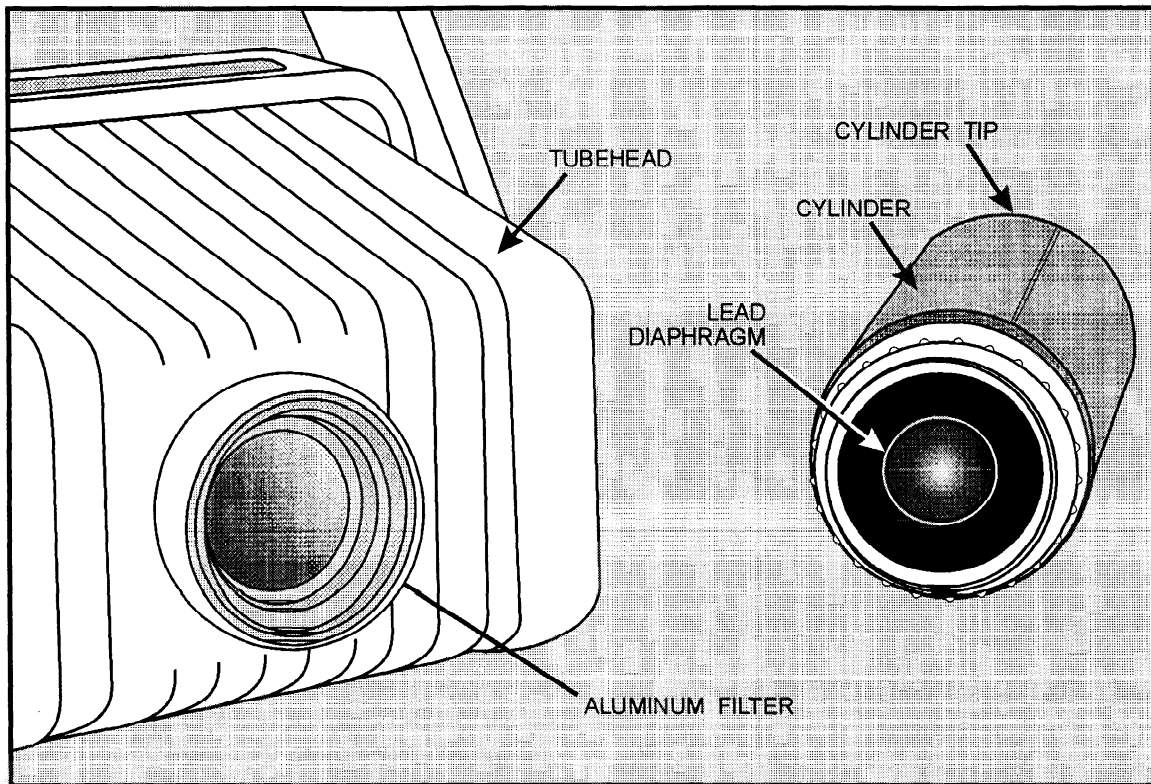
### CYLINDER

The cylinder (or cone) is affixed to the tube head and is used to align the tube head with the patient and the X-ray film. It is open-ended and composed of lead laminated material that establishes the minimum distance from the X-ray source to the patient's skin.



DTV2f102

Figure 1-2.—Wall-mounted X-ray machine.



DTV2f103

Figure 1-3.—Tube head and cylinder (short cone).

The X-ray beam passes from the aluminum filter through an opening in a lead diaphragm, which restricts the beam to 2.6 inches at the cylinder tip. There are two commonly used cylinder lengths. A tube head with an X-ray source to cylinder end distance of 8 inches is referred to as a "short cone" machine, while a tube head with an X-ray source to cylinder end distance of 16 inches is referred to as a "long cone" machine. It is essential that the technician knows the X-ray source to cylinder end distance in order to set the appropriate exposure settings.

The tube head is attached to an extension arm. The extension arm is movable, allowing you to adjust the position of the tube head for each patient.

### CONTROL PANEL

The operational controls on the control panel are covered in the discussion on the operational check.

### OPERATIONAL CHECK (WITHOUT PATIENT)

At the beginning of each workday, you should activate the X-ray machine to ensure that it is working properly. This operational check is conducted without

a patient in the chair. In order to check the machine, you must be thoroughly familiar with its operation. Read the manufacturer's instructions carefully.

Throughout this discussion of the operational check, refer to figure 1-4. The steps of procedure are:

1. Energize the control panel. The control panel shown in figure 1-4 has three push buttons in the upper left corner. By depressing either the 10 mA or the 15 mA pushbutton, you will energize the machine and select the milliamperage setting at the same time. Once the button is depressed the "power on" light will glow amber, indicating that the system is turned on. (A setting of 10 mA is normally used for intraoral radiographs.)

**NOTE:** Some machines have separate master on/off switches. On these machines, you should FIRST activate the master switch, and then select the milliamperes (10 mA or 15 mA) setting. A 10 mA setting is used for most dental radiographs. Some units use a combination master on/off switch and mA selector to energize the machine.

2. Set the tube head selector. On units with multiple tube head capabilities, depress the pushbutton that corresponds to the tube head to be used, normally

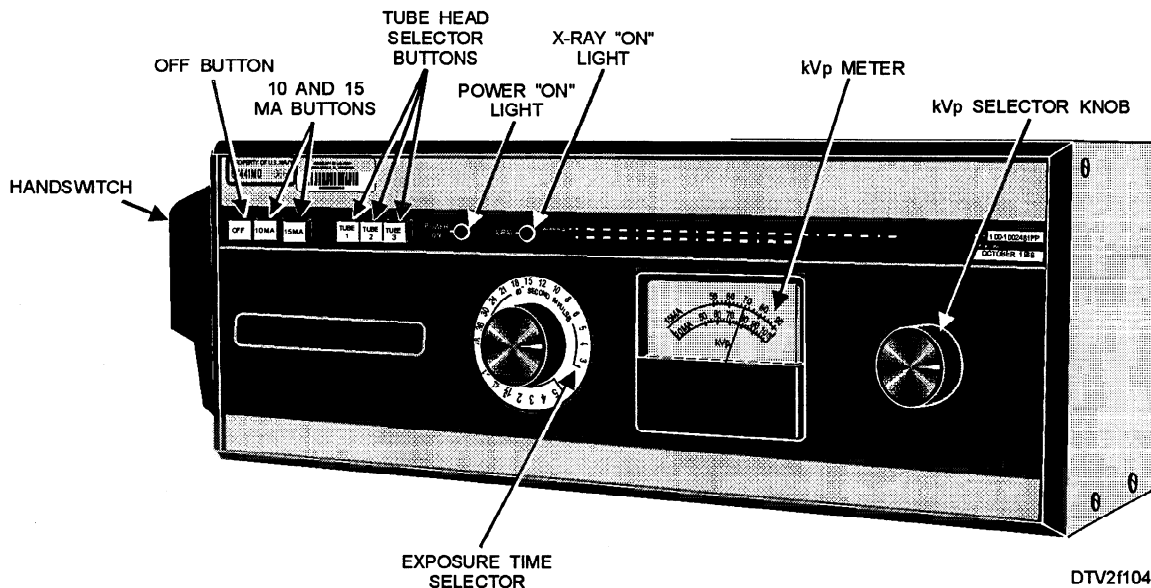


Figure 1-4.—Control panel for wall mounted X-ray machine.

tube 1. The depressed button and a lamp on the selected tube head will glow.

3. Select the kilovoltage. Adjust the kilovoltage (kV) until the desired kilovolt peak (kVp) is registered on the kilovolt meter. The kVp setting will vary, depending on the patient's bonesize and density; specific settings will be given later in this chapter.

**NOTE:** Some X-ray machines shut off automatically if the setting exceeds 90 kVp. Refer to the manufacturer's instructions for resetting procedures.

4. Set the exposure time. Check the X-ray film manufacturer's recommended time setting for the type of film being used, the kVp and mA settings, and the film focal distance (FFD). The time settings may be in fractions of a second or impulses. An impulse equals 1/60 of a second. To protect the patient from needless exposure to radiation, use the minimum exposure time necessary to produce the desired results.

5. Check to see that the machine is emitting X-rays. Place an unexposed packet of X-ray film on the seat of the dental chair. Put a penny on top of the film packet and position the tube head. The tube head cylinder should be pointed down, 6 inches above and centered on the penny. When the tube head is correctly positioned, prepare to make the exposure.

**WARNING:** You must be behind a lead-lined shield or at least 6 feet from the tube head when making the exposure.

6. Make the exposure by depressing the exposure button located on the control panel. Exposure start is delayed approximately 1/2 second. If the machine is working correctly, you will hear a click and the tone signal, and the "X-ray" lamp on the control panel will glow. This indicates that an exposure is being made. **Do not release the exposure switch until the selected exposure time is completed.**

7. After making the exposure, process the X-ray film. If the processed film shows a light area where the penny was, the X-ray machine is working properly. Processing techniques will be discussed later in this chapter.

## MACHINE OPERATION (WITH A PATIENT)

Once the X-ray machine's operational readiness check has been completed, it is a simple matter to prepare it to take radiographs on a patient. Set the mA selector, the tube head selector (if necessary), the kVp selector, and the exposure time. Before you make the exposure, position the patient, the film packet, and the tube head cylinder. These patient positioning procedures are discussed later.

## SECURING THE X-RAY MACHINE

At the end of each work day, deactivate the off switch and secure the machine (e.g., the tube head extension arm should be completely folded to minimize the weight of the tube head on the arm and wall mounting plate).

## USER MAINTENANCE

An X-ray machine is very expensive. Do everything possible to keep it in good working order by following the user maintenance procedures contained in the manufacturer's instructions.

General user maintenance includes dusting the X-ray machine daily, and removing blood and debris from all surfaces using a cloth moistened with detergent solution. Follow disinfection procedures discussed later in the chapter.

**NOTE:** DO NOT use a wet cloth; moisture might enter the control panel causing an electrical short circuit that could cause severe damage to the machine and possible harm to the operator. DO NOT use cleaners or solvents.

Never attempt to repair the X-ray machine yourself. If it breaks down, report it to your supervisor. All repairs are the responsibility of the dental equipment repair technician.

## INTRAORAL RADIOGRAPHS

Intraoral radiographs are made with the X-ray film placed inside the patient's mouth. There are three types of intraoral radiographic examinations: periapical examination, interproximal (bitewing), and the occlusal.

To ensure diagnostic quality radiographs, you must properly align the X-ray film, the area to be X-rayed, and the tube head cylinder of the X-ray machine. Alignment can be accomplished by using either the parallel film placement technique (preferred method) or the bisecting angle technique. The following discussion provides detailed information on how to take periapical and interproximal (bitewing) radiographs, using both techniques. For the occlusal examination, you will use only the bisecting angle technique.

## INTRAORAL FILM

The X-ray films used for intraoral examinations differ in size, depending on the type of examination. Figure 1-5 compares the sizes of periapical, interproximal (bitewing), and occlusal film.

There are different speeds of film. The most commonly used is an ultraspeed film known as D speed film. Ektaspeed (or E speed) film requires less radiation per exposure than D speed film. Some commands are now using E speed film. The exposure

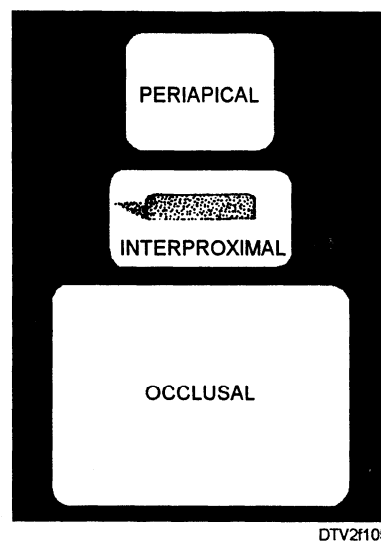


Figure 1-5.—Intraoral X-ray film.

times given in the following sections are for D speed film.

Intraoral film comes in film packets, with a lightproof and waterproof outer wrapper. Inside the wrapper, the film is sandwiched between black protective paper and backed with lead foil. Figure 1-6 shows a partially unwrapped periapical film.

## STORAGE

Intraoral film can be ordered through normal supply channels. It must be stored in a cool, dry area. In very hot or damp climates, the film should be refrigerated. Never store it near steam lines or radiators, and never store it near film processing

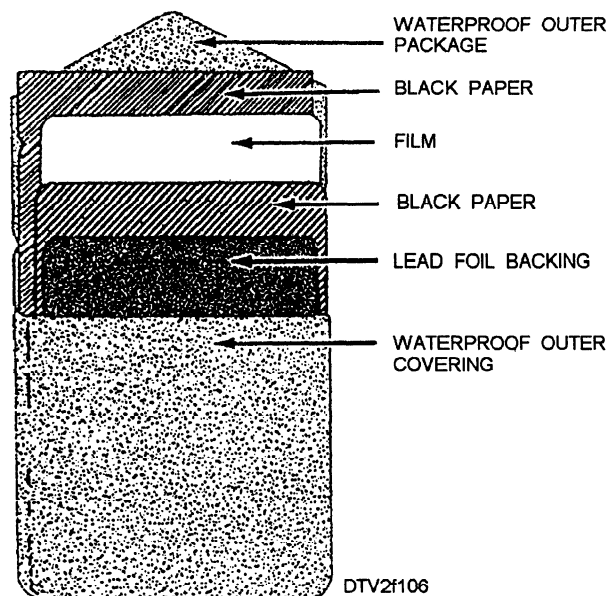


Figure 1-6.—Partially unwrapped periapical film.



solutions, since the escaping fumes could damage the film.

Because the unprocessed film is sensitive to X-rays, it must be stored in lead lined containers, as shown in figure 1-7 in the open and closed position. Remove only one film at a time from the lead film dispenser, make the exposure, and place the film in a clean paper cup or disposable container. Place the cup or disposable container in a lead container or behind a protective screen before making the next exposure. Repeat this procedure for each exposure. Maintain a minimum stock of film, and use the oldest film first so the stock is always fresh.

### PRECIOUS METALS RECOVERY PROGRAM (PMRP)

The precious metals recovery program is designated to save Department of Defense (DOD) money by recycling precious metals and using those funds to offset the cost of supplies for DOD activities. Both silver and lead are precious metals that are found

in the X-ray department. The silver is found in used fixer solutions and on dental films. The lead is found in X-ray packets. These precious metals should be saved and turned into the supply department following the guidelines in BUMEDINST 4010.3, "Precious Metals Recovery Program."

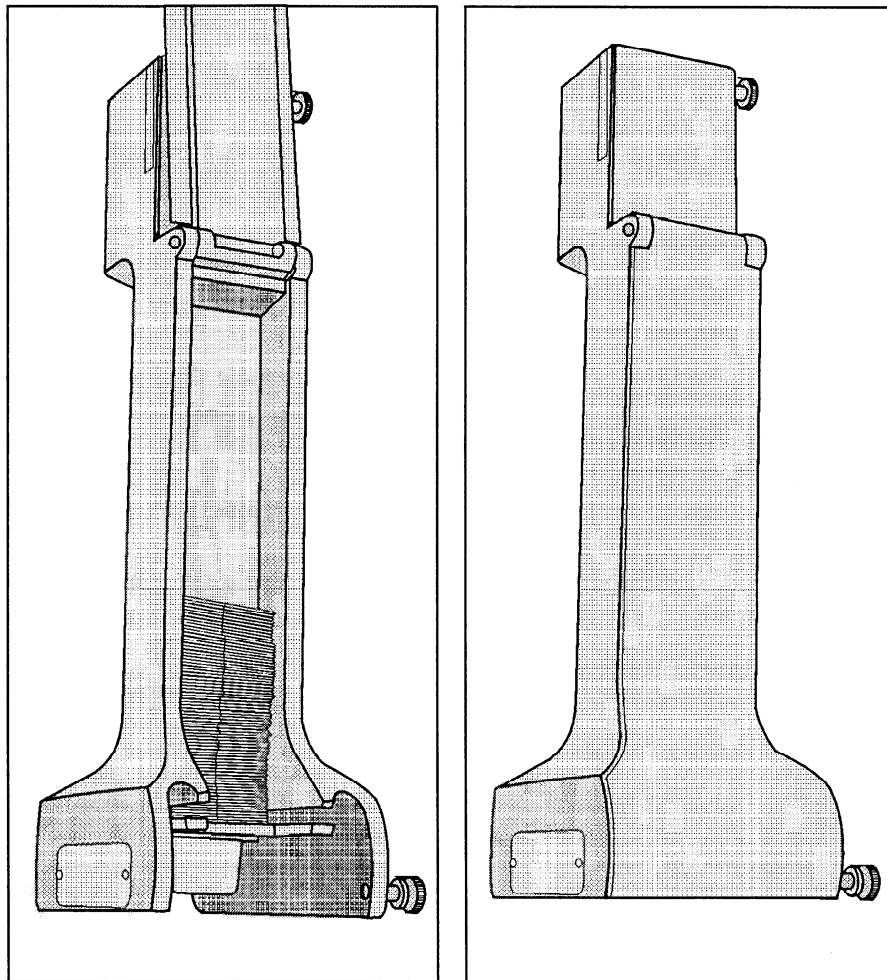
### ASSISTANT PREPARATION

To protect yourself and the patient from diseases, perform the handwashing and gloving procedures covered in *Dental Technician*, Volume 1, chapter 9, "Infection Control ."

### PATIENT PREPARATION

To properly prepare a patient for an X-ray procedure, you should employ the following techniques:

- Ensure all infection control procedures are followed.



DTV21107

Figure 1-7.—Lead lined container.

- Seat and position the patient. Positioning varies according to the type of radiographic examination and the film placement technique you are going to use. Specific positioning procedures will be discussed later.

- If the patient is a woman, ask her if she is pregnant. If she is or you suspect that she might be, consult the dentist.

- Ask the patient to remove eyeglasses, complete dentures, removable partial dentures, earrings, or any other objects about the head and neck.

- Explain the X-ray procedures to the patient. If the patient is nervous about being X-rayed, explain the safety precautions taken to prevent overexposure to radiation.

- **Drape the patient with a lead apron and thyroid collar.**

- Quickly examine the patient's mouth to determine its anatomy. Such things as a small mouth, an abnormally shallow vault, crooked teeth, and bony protrusions can affect the placement of the film packet. The patient's overall bone size and density will determine the kVp setting. For a patient with a normal bone size and density, use a kVp setting of 87; for a patient with a thick bone size and density, use a 90 kVp setting.

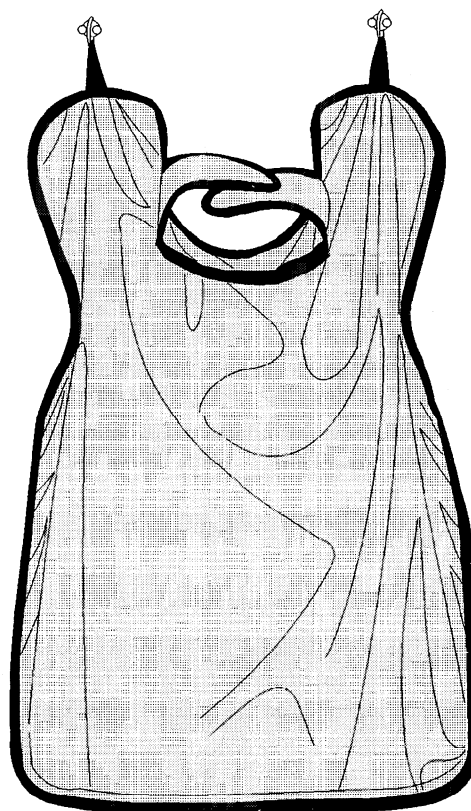
- Position the patient's head securely against the headrest.

- Place the film packet in the patient's mouth. Film placement procedures will be discussed later. Occasionally patients may gag when the film is placed in their mouth. The gagging reflex may be caused by nervousness, so remain calm and reassure the patient. You might recommend that patients breathe through their nose, since it is difficult to gag while doing so, having patients rinse out their mouth with cold water may also help or have patients concentrate on something other than gagging. Whatever technique you use you will have to be swift in placing the film and making the exposure because the chance of keeping the gag reflex from returning for an extended period is highly unlikely.

- After the X-ray procedure is completed, you must store the lead apron and thyroid collar properly to avoid damage as shown in figure 1-8.

## PERIAPICAL EXAMINATION

A periapical examination is conducted to obtain radiographs of the crowns, roots, and supporting



DTV2f108

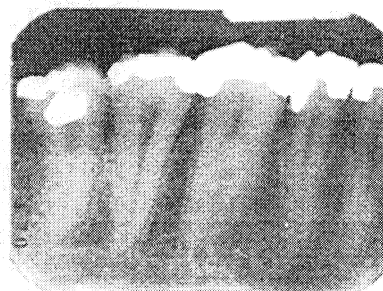
**Figure 1-8.—Properly stored lead apron with thyroid collar.**

structures of the teeth. Figure 1-9 shows a typical periapical radiograph.

There are two techniques available to take periapical radiographs: paralleling and bisecting-angle. Both techniques use the long axis of the tooth as a focal point. The paralleling technique is the preferred method and the bisecting-angle technique is used as an alternative. Film placement and techniques are discussed in the following sections.

## PARALLELING TECHNIQUE

When using the paralleling technique, you must center the X-ray film packet behind, and parallel with



DTV2f109

**Figure 1-9.—Typical periapical radiograph.**

the long axis of the tooth being X-rayed. A tube head with a 16-inch X-ray source to cylinder end distance (long cone) should be used with the paralleling technique. The tube head must be positioned so that the central X-ray beam is projected perpendicular to the tooth and the film packet. To properly position the film and the tube head, use paralleling devices.

There are two different paralleling devices. One is used for radiographs of the anterior teeth; the other is used for radiographs of the posterior teeth. Each paralleling device consists of a bite-block, an indicator rod, and locator ring (fig. 1-10). The bite-block has a slot and a film backing support to hold the X-ray film packet.

### Assembling The Anterior Device

Figure 1-11 shows a fully assembled anterior paralleling device. Refer to this figure during the following explanation on assembling the paralleling device:

- Grasp the periapical film packet between the thumb and first two fingers of your right hand. The printed surface of the packet should be facing you, and the side with the raised dot should be in the film positioning slot of the paralleling device.

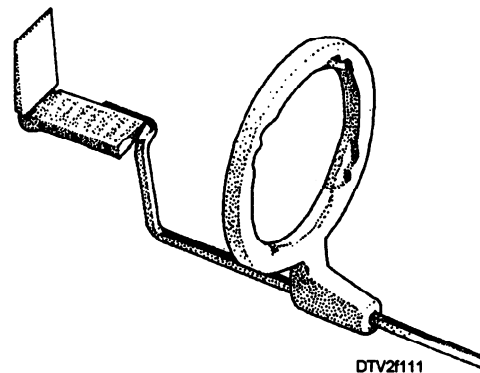


Figure 1-11.—Assembled anterior paralleling device.

- Hold the base of the anterior bite-block between the thumb and first two fingers of your left hand. Ensure that the plastic film support is pointed upward and the film positioning slot is away from you.
- Holding the film packet in position, press it against the plastic support and slide the film down into the positioning slot. The printed side of the packet should be facing the plastic support, and the raised dot should be located toward the positioning slot.
- The two prongs of the indicator rod are inserted into the openings in the bite-block.
- Slide the anterior locator ring onto the indicator rod. Look through the locator ring. If the bite-block and

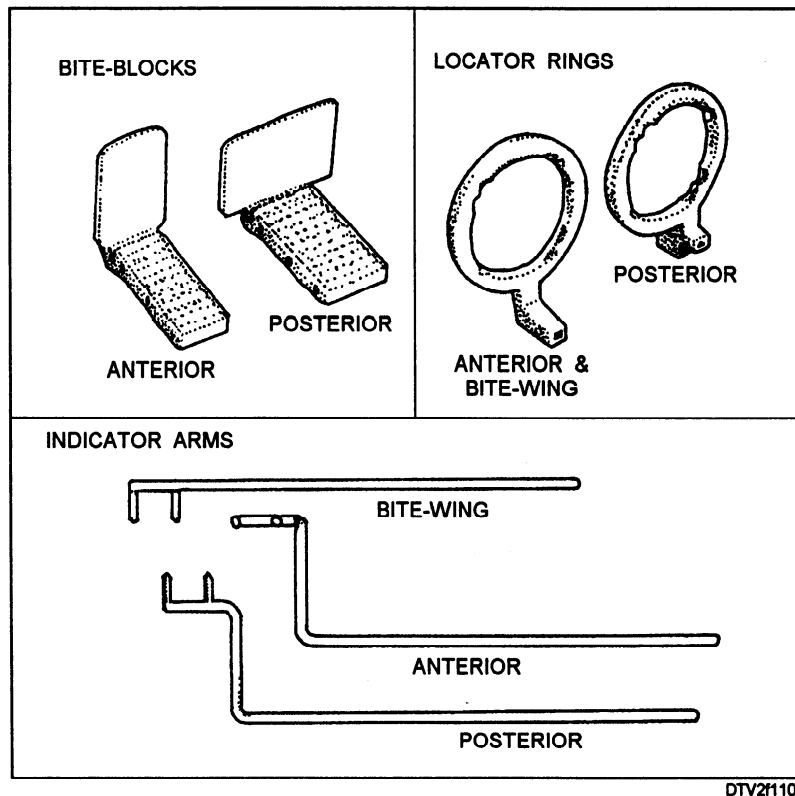


Figure 1-10.—Anterior and posterior paralleling devices.

film are centered in the locator ring, the device is properly assembled and ready for positioning in the patient's mouth.

### Assembling The Posterior Device

Figure 1-12 shows a fully assembled posterior paralleling device. Refer to this figure during the following discussion.

- Insert the film into the posterior bite-block as previously discussed.

**NOTE:** The posterior device shown in figure 1-11 is used for film placement in the right maxillary and left mandibular quadrants. You must reassemble the device, rotating the locator ring and the bite-block, before using it in the left maxillary or right mandibular quadrants. Only the posterior device must be reassembled in this manner, the anterior device **does not** require reassembly.

### Placing The Device

Once you have assembled the posterior paralleling device, place it in the patient's mouth. Be very careful not to injure the oral tissue. If the patient gags, use the remedies discussed earlier.

Guide the bite-block and the film packet into position, centering the packet behind the area being X-rayed. The film packet should be positioned far enough behind the tooth so it will be parallel to the long axis of the tooth.

After positioning the film packet, slide the locator ring down the indicator rod until the ring almost touches the surface of the patient's face. Then, position the tube head cylinder. The end of the cylinder should be parallel with the locator-ring, and its side should be parallel with the indicator rod.

Once these procedures have been accomplished, the film packet and the tube head are in proper alignment. You are now ready to expose the film.

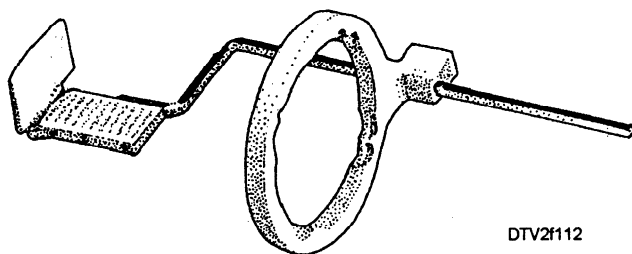


Figure 1-12.—Assembled posterior paralleling device.

## EXPOSURE ROUTINE FOR FULL MOUTH PERIAPICAL EXAMINATION

The full mouth periapical examination consists of 14 periapical radiographs (7 maxillary and 7 mandibular). The series includes the following films and sequence starting with the maxillary arch and proceeding to the mandibular arch:

1. Incisor area
2. Left cuspid area
3. Left bicuspid area
4. Left molar area
5. Right cuspid area
6. Right bicuspid area
7. Right molar area

## GUIDELINES FOR TAKING PERIAPICAL RADIOGRAPHS, PARALLELING TECHNIQUE

The following guidelines apply if you are taking either a full mouth series, or an individual periapical radiograph. For training purposes, infection control barriers are not used in the photographs in this section.

In most cases, the X-ray machine is set at 10 mA for dental radiographs. The kVp may vary, depending upon the thickness or the region being radiographed. If the area being radiographed is edentulous (no teeth present), reduce the recommended kVp by 5. When you are taking radiographs on a child, reduce the recommended kVp to 70. Always consult the dentist before taking radiographs on a child. Because of the different types of X-ray equipment in use, the exposure time selector you use may not have the settings suggested. Consult the film manufacturer's instructions regarding the desired time setting to use.

Before you perform an individual radiograph or a full mouth periapical examination, prepare the patient, using the procedures explained earlier. When you are using the parallel film placement technique, the position of the patient's head is not critical. But, it is best to adjust the head rest on the dental chair so that the patient's "plane of occlusion" is parallel with the floor and the "midsagittal plane" is perpendicular to the floor (fig. 1-13.)

It is important to properly position the paralleling devices and the tube head cylinder when using the paralleling placement technique.

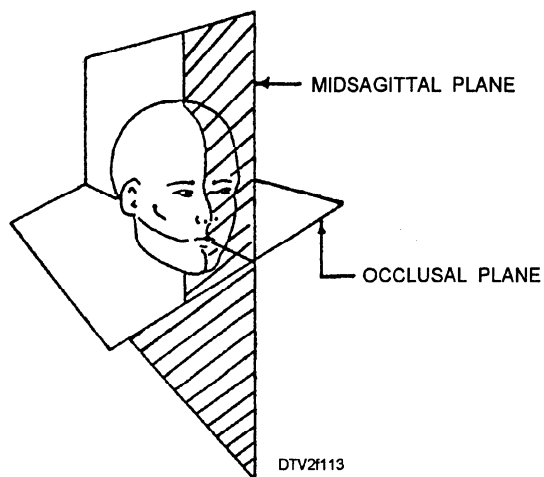


Figure 1-13.—Midsagittal and occlusal planes.

When taking a full mouth series or an individual periapical radiograph, follow the given guidelines for the specific area listed:

**NOTE:** After each exposure, put the exposed film in a clean paper cup or disposable container. Then place the cup or disposable container in a lead container or behind a protective screen.

- Maxillary Incisor Area

1. Set the exposure time selector to manufacturer's suggested impulses.
2. Prepare the anterior paralleling device.
3. Position the paralleling device with film in the patient's mouth. Center the film on the midline so that it is parallel with the long axis of the incisors (fig. 1-14).
4. Place a cotton roll under the bite-block. Have the patient close gently but firmly.
5. Adjust the locator ring and align the tubehead cylinder as previously described.
6. Make the exposure.

- Maxillary Cuspid Area

1. Set the exposure time selector to manufacturer's suggested impulses.
2. Prepare the anterior paralleling device.
3. Position the paralleling device with film in the patient's mouth. Center the film on the cuspid and parallel with the tooth's long axis (fig. 1-15).
4. Place a cotton roll under the bite-block and have the patient close.

5. Adjust the locator ring and align the tubehead cylinder.

6. Make the exposure.

- Maxillary Bicuspid Area

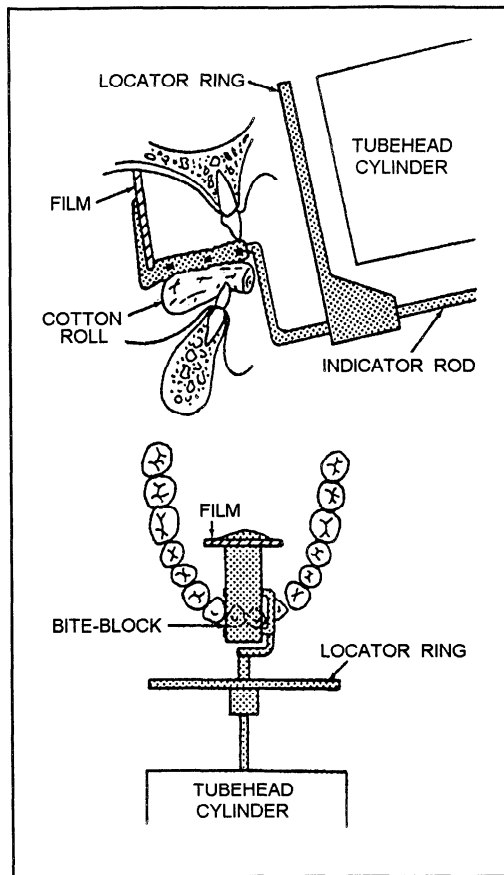
1. Set the exposure time selector to the manufacturer's suggested impulses.
2. Prepare the posterior paralleling device.
3. Position the paralleling device with film in the patient's mouth. Center the second bicuspid and parallel with the tooth's long axis (fig. 1-16).
4. Place a cotton roll under the bite-block and have the patient close.
5. Adjust the locator ring and align the tubehead cylinder.
6. Make the exposure.

- Maxillary Molar Area

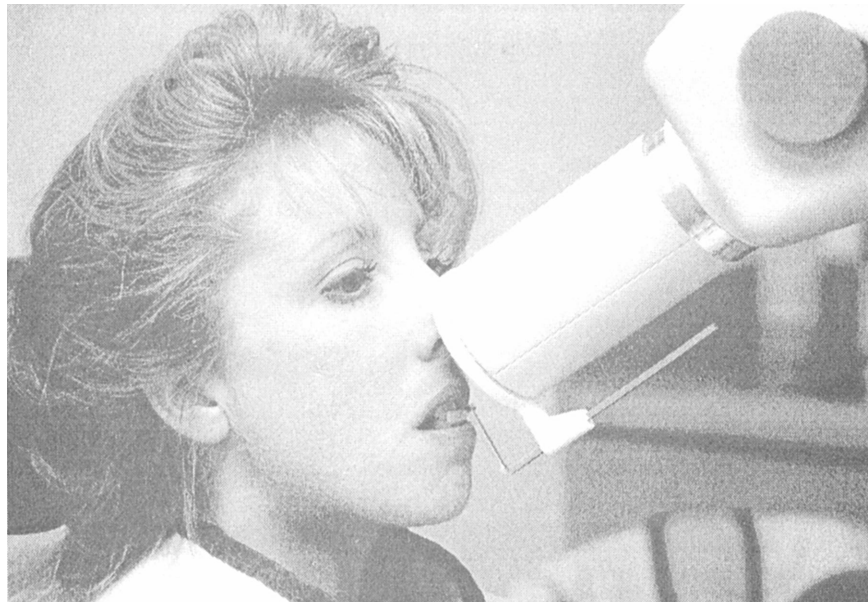
1. Set the exposure time selector to the manufacturer's suggested impulses
2. Prepare the posterior paralleling device.
3. Position the paralleling device with film in the patient's mouth. Center the film on the second molar, so the anterior edge of the film includes at least the distal half of the second bicuspid. The film should be parallel with the long axis of the molars (fig. 1-17).
4. Place a cotton roll under the bite-block and have the patient close.
5. Adjust the locator ring and align the tubehead cylinder.
6. Make the exposure.

- Mandibular Incisor Area

1. Set the exposure time selector to the manufacturer's suggested impulses.
2. Prepare the anterior paralleling device.
3. Position the paralleling device with film in the patient's mouth. Position the film packet so that it is centered on the midline and parallel with the long axis of the incisors (fig. 1-18).
4. Place a cotton roll on the upper surface of the bite-block and have the patient close.
5. Adjust the locator ring and align the tubehead cylinder.
6. Make the exposure.



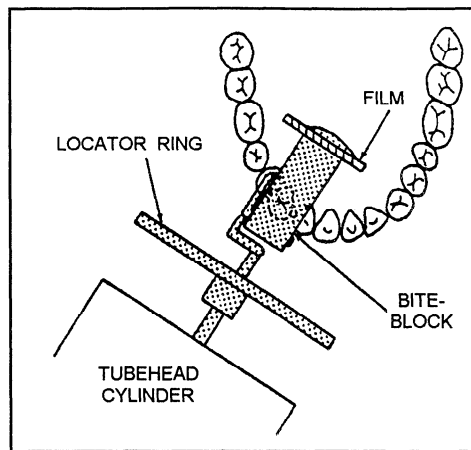
DTV2H14L



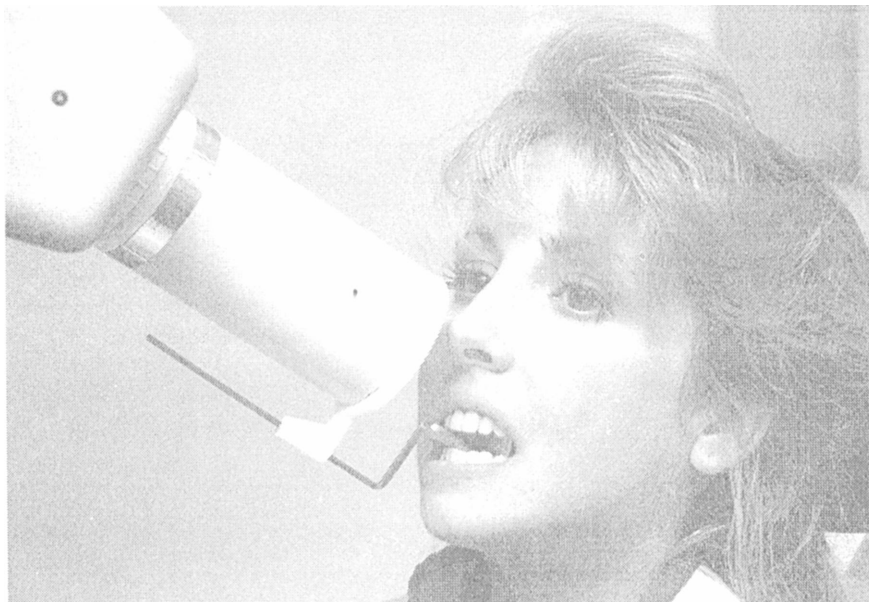
DTV2H14G

**Figure 1-14.—Film and cylinder placement: maxillary incisor area.**

- Mandibular Cuspid Area
1. Set the exposure time selector to the manufacturer's suggested impulses.
  2. Assemble the anterior paralleling device.
  3. Position the paralleling device with film in the patient's mouth. Center the film on the cuspid and parallel with its long axis (fig. 1-19).
  4. Place a cotton roll on the upper surface of the bite-block and have the patient close.



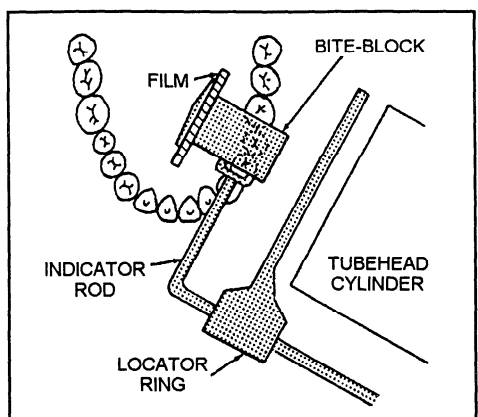
DTV2f115L



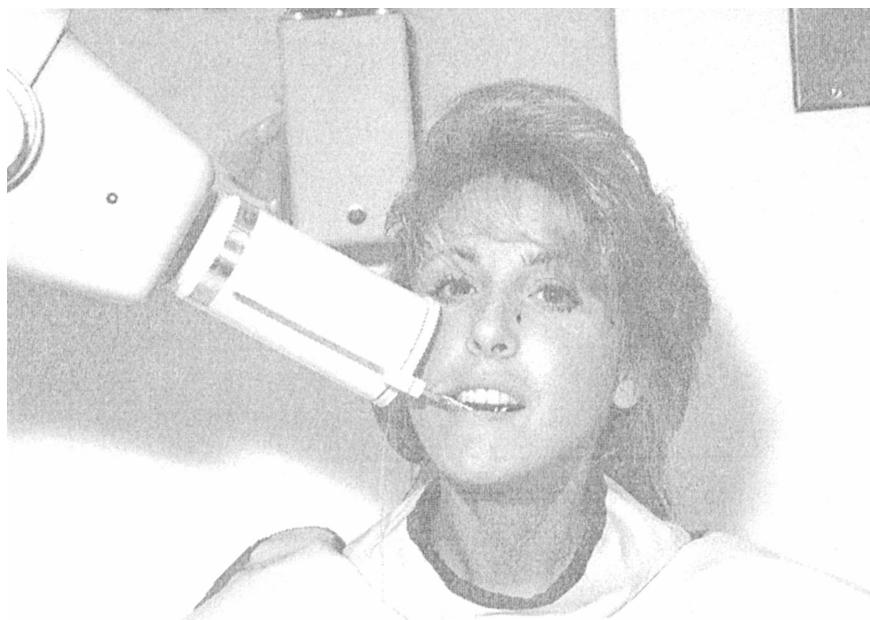
DTV2f115G

**Figure 1-15.—Film and cylinder placement: maxillary cuspid area.**

5. Adjust the locator ring and align the tubehead cylinder.
6. Make the exposure.
  - Mandibular Molar Area
    1. Set the exposure time to the manufacturer's suggested impulses.
    2. Assemble the posterior paralleling device.
    3. Position the paralleling device with film in the patient's mouth. Position the film packet. Center the film on the second molars, so the anterior edge of the film includes at least the distal half of the second bicuspid. The film should be parallel with the long axis of the molars (fig. 1-21).
    4. Place a cotton roll on the upper surface of the bite-block and have the patient close.
    5. Adjust the locator ring and align the tubehead cylinder.
  - Mandibular Bicuspid Area
    1. Set the exposure time to the manufacturer's suggested impulses.
    2. Assemble the posterior paralleling device.
    3. Position the paralleling device with film in the patient's mouth. Position the film packet so that it is centered on the second bicuspid and parallel with its long axis (fig. 1-20).
    4. Place a cotton roll on the upper surface of the bite-block and have the patient close.
    5. Adjust the locator ring and align the tubehead cylinder.



DTV2F116L



DTV2f116G

Figure 1-16.—Film and cylinder placement: maxillary bicuspid area.

#### 6. Make the exposure.

### VARIATION TO THE EXPOSURE FACTORS AND FILM ALIGNMENT

Some variations to the exposure factors and film alignment may be necessary for a specific area of the patient's anatomy.

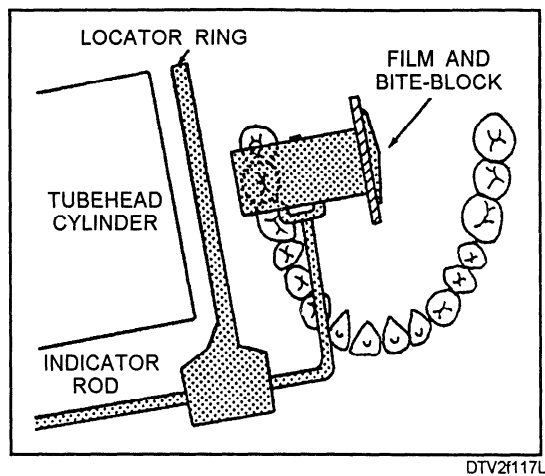
The dentist may request a radiograph of an impacted third molar. If so, you would prepare the paralleling device in the usual manner, placing the film packet off center in the backing support so the film extends posteriorly to cover the entire third molar area. When you place the paralleling device in the patient's mouth, position it so the anterior edge of the film includes the distal half of the first molar.

Use special film placement procedures when a patient has a low palatal vault or edentulous arches. Place one cotton roll on each side of the bite-block as shown in figure 1-22. This ensures that the X-ray film will be parallel with the long axis of the teeth being radiographed.

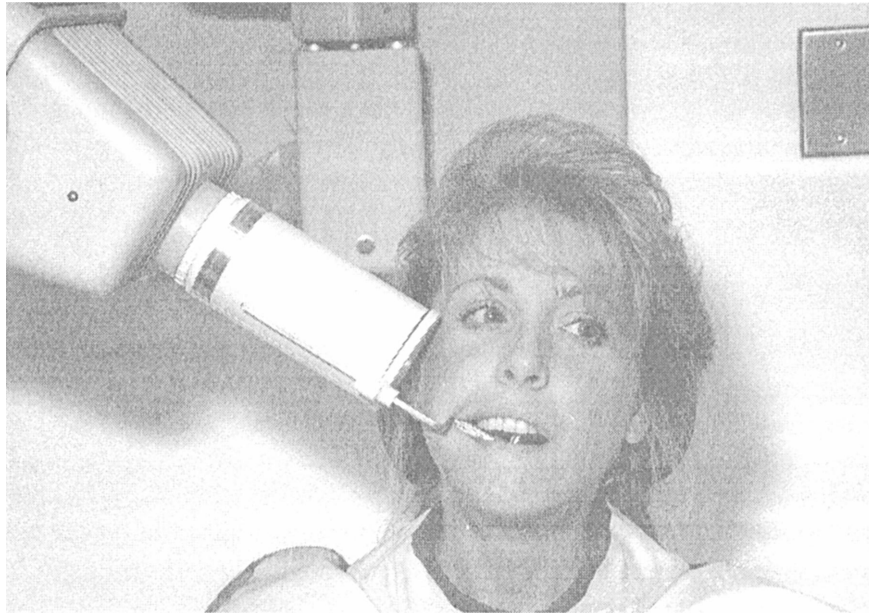### BISECTING-ANGLE TECHNIQUE

Use the bisecting-angle technique when paralleling devices are not available; or when a patient finds it painful or impossible to close on the bite-block; or when an X-ray is needed when a rubber dam is in place. This technique incorporates the use of a tube head with an X-ray source to cylinder end





DTV2117L



DTV2117G

Figure 1-17.—Film and cylinder placement: maxillary molar area.

distance of 8 inches (short cone). **The bisecting-angle technique is not recommended for routine use.**

Since paralleling devices are not used with the bisecting-angle technique, you must pay special attention to positioning the patient, the film packet, and the tube head.

### Positioning the Patient

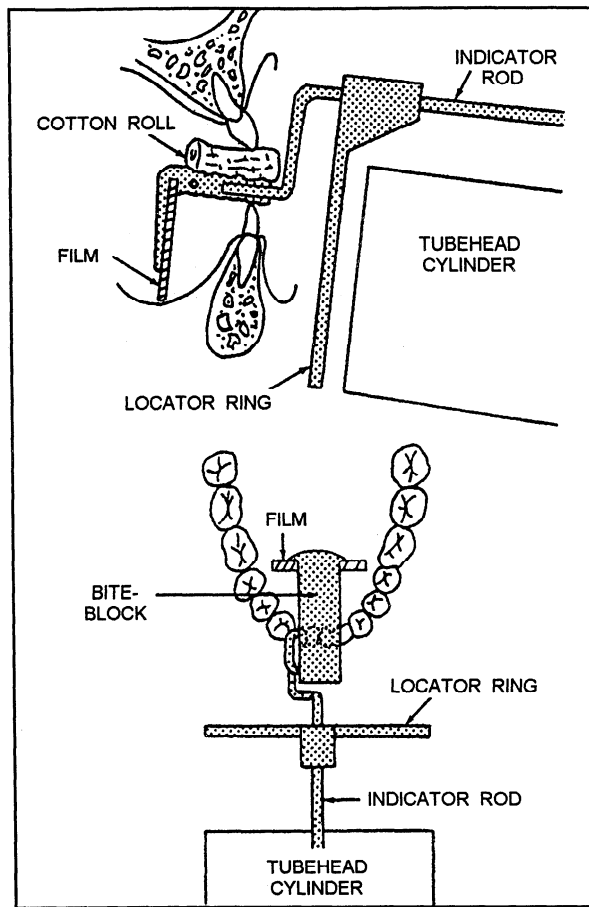
For all maxillary periapical radiographs, position the patient's head as shown in figure 1-23 from the ala of the nose (the outer portion of the nostril) to the tragus of the ear (a projection of the cartilage on the front center of the ear). This ala-tragus line should be parallel with the floor. The patient's head should also

be positioned so that the midsagittal plane is perpendicular to the floor.

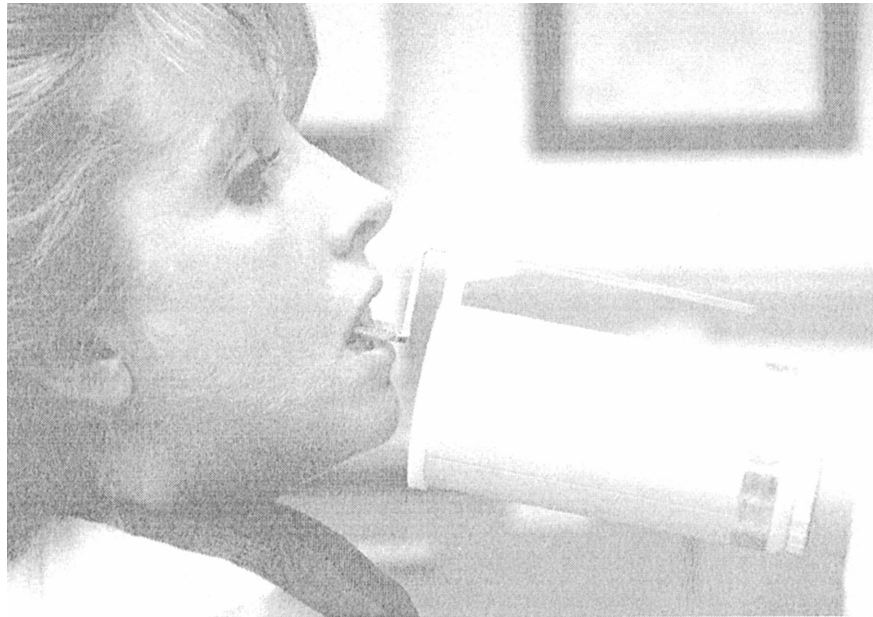For mandibular periapical radiographs, lower the headrest so the patient's head is positioned as shown in figure 1-24. The figure shows a line running from the corner of the patient's mouth to the tragus of the ear. This line should be parallel with the floor. Again, the mid-sagittal plane is perpendicular to the floor.

### Positioning the Film

Once the patient is positioned, insert the film packet in the patient's mouth with a pair of hemostats or other holding device. Never slide the packet in; this might irritate the oral mucosa or cause the patient to gag. Gently direct the holding device to the desired



DTV2f118L

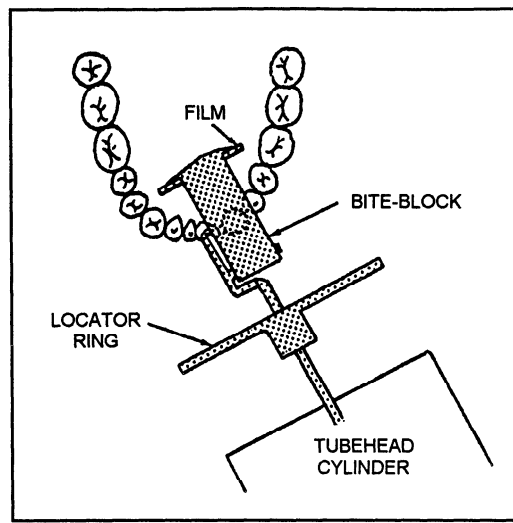


DTV2f118G

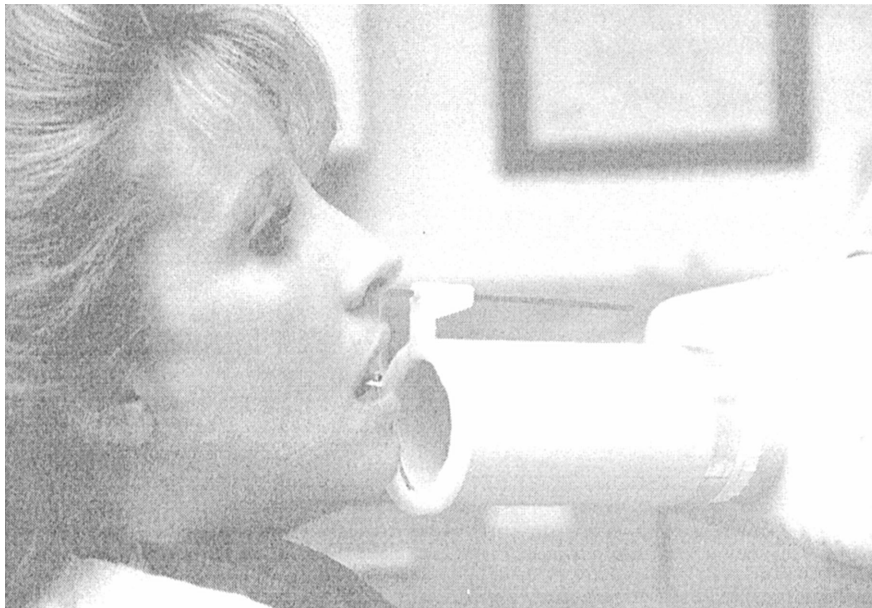**Figure 1-18.—Film and cylinder placement: mandibular incisor area.**

position. In order to adapt the packet to the area being radiographed and to relieve patient discomfort, it may be necessary to shape the packet. Do this by gently flexing the corners of the packet and holding it over the end of your thumb. Do not crease the packet.

Center the packet behind the tooth to be radiographed. The printed side of the packet should face away from the tooth, with the printed dot toward the occlusal surface. The film is held as close to the tooth as possible. At this point the long axis of the tooth



DTV2f119L



DTV2f119G

**Figure 1-19.—Film and cylinder placement: mandibular cuspid area.**

and the plane of the film should be nearly parallel. In order to project the proper image of the tooth onto the film, you must visualize an imaginary line bisecting the long axis of the tooth and the plane of the dental film (fig. 1-25). The central ray is then directed perpendicular (a 90° angle) to the bisecting line. This will project the proper dimensions of the tooth onto the film without elongation or foreshortening. If the anterior curvature of the patient's arch is narrow, insert a cotton roll between the packet and the teeth. This prevents the film from bending excessively and producing a distorted image.

Once the film packet is properly positioned, guide a free hand of the patient to the holding device. The

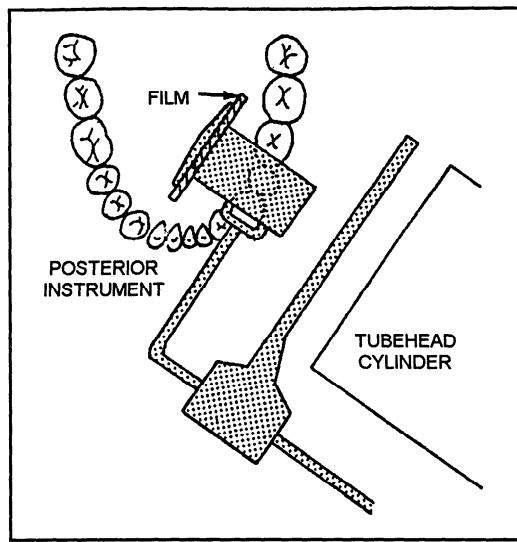
patient gently holds the device with the hand from the opposite side of the arch being radiographed.

**WARNING:** The assistant should never hold the film packet in position during an exposure.

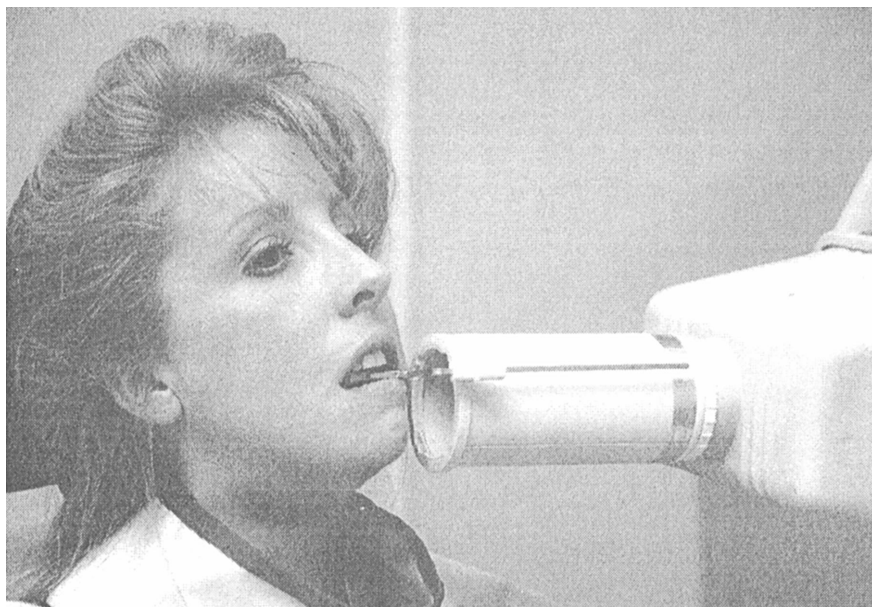Each time you take radiographs, use the standard film positions. This helps when comparing radiographs made at different times.

### **Positioning the Tube Head**

After the film is inserted in the patient's mouth, position the tube head so the end of the cylinder is near the area to be radiographed. Then, position the tube head for correct vertical and horizontal angulation



DTV2f120L



DTV2f120G

Figure 1-20.—Film and cylinder placement: mandibular bicuspid area.

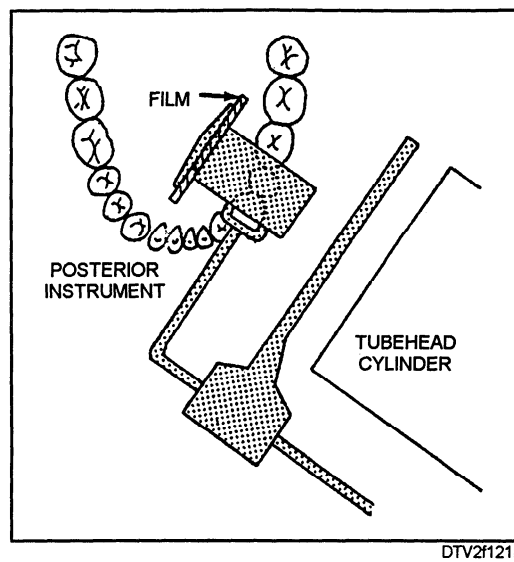
using anatomical landmarks on the patient's face. Tell your patient to maintain the position of the placement of the dental film and not to move while you expose the radiograph.

**VERTICAL ANGULATION.**—This is the up-and-down positioning of the tube head. A  $0^\circ$  vertical angulation indicates that the tube head is positioned with the cylinder parallel with the floor (fig. 1-26). Angling the tube head so the cylinder points upward from  $0^\circ$  will give you a minus (–) degree of vertical angulation. Angling the tube head so the cylinder points downward from  $0^\circ$  will give you a plus (+) degree of vertical angulation.

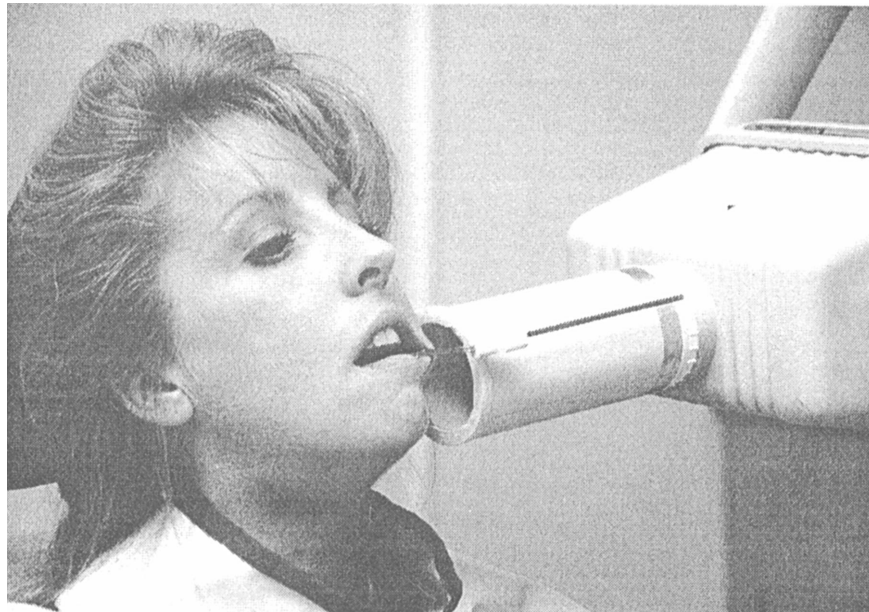Different areas of the mouth require different degrees of vertical angulation. The correct vertical angulation can usually be obtained by using the angles shown on the chart in figure 1-26. Notice the tube head is angled downward for maxillary radiographs, and usually angled upward for mandibular radiographs. The tube head may be horizontal ( $0^\circ$ ) when X-raying mandibular molars.

A wrong angulation results in a distorted radiograph. Too little vertical angulation elongates the radiographic image (fig. 1-27); too much vertical angulation foreshortens the image (fig. 1-28).

A standard vertical angulation cannot be used for all patients because of differences in their oral

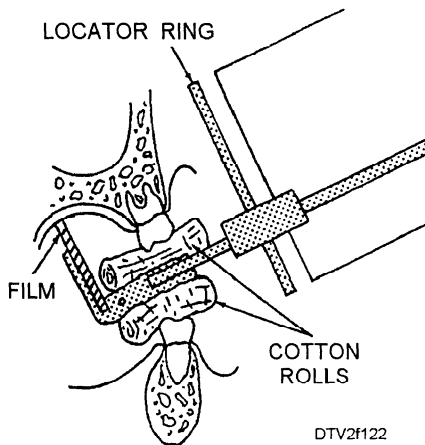


DTV2f121L



DTV2f121G

Figure 1-21.—Film and cylinder placement: mandibular molar area.



DTV2f122

Figure 1-22.—Film and cylinder placement: patients with low palatal vaults or edentulous arches.

structures. A patient may have an unusually high maxillary vault or an unusually deep palatal vault. In either case, you would decrease the standard vertical angulation by about 5°. On the other hand, for a patient with an unusually shallow vault, you would increase the angulation by about 5°. The more experienced you become in X-ray techniques, the easier it will be for you to determine when to alter standard vertical angulation to suit the needs of a particular patient.

After you have determined the correct vertical angulation for the area to be radiographed, adjust the tube head using the angle dial on the tube head as a reference.



DTV2f123

**Figure 1-23.—Ala-tragus line parallel with the floor.**



DTV2f124

**Figure 1-24.—Line from the corner of the mouth to the tragus parallel with the floor.**

When the tube head has been set for the proper vertical angulation, center the tube head cylinder on the area to be radiographed. The cylinder should almost touch the surface of the patient's skin. Then, position the tube head for correct horizontal angulation.

**HORIZONTAL ANGULATION.**—This is the side-to-side positioning of the tube head. Position the

tube head so the central X-ray beam is directed straight through the embrasures of the teeth being radiographed. If the horizontal angulation is faulty, the central ray will be directed at an angle to the embrasures. This will produce a faulty radiograph, with the images of the teeth overlapping one another. Figure 1-29 illustrates the correct and incorrect cylinder direction.

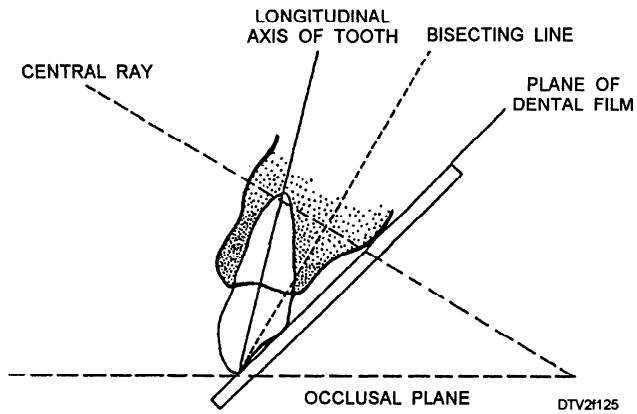
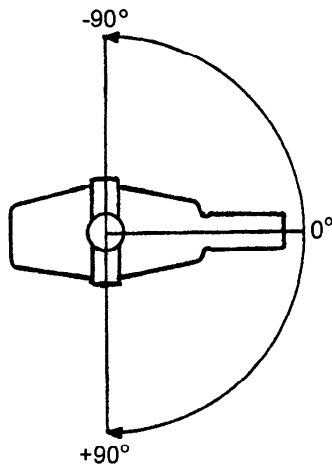


Figure 1-25.—Relationship of central ray, tooth, and film packet in bisecting-angle technique.

### GUIDELINES FOR TAKING PERIAPICAL RADIOGRAPHS, BISECTING-ANGLE TECHNIQUE

Take the same 14 radiographs using the same exposure sequence as that discussed for the paralleling technique. Complete the following steps:

1. Program the X-ray machine for the discussed mA and kVp settings. The exposure time varies, just as it did with the paralleling technique. Refer to the film



	Maxillary	Mandibular
Incisor	+40 to +45	Incisor -15 to -20
Cuspid	+45 to +50	Cuspid -20 to -25
Bicuspid	+30 to +35	Bicuspid -10 to -15
Molar	+20 to +25	Molar -5 to 0

Figure 1-26.—Average vertical angulation.

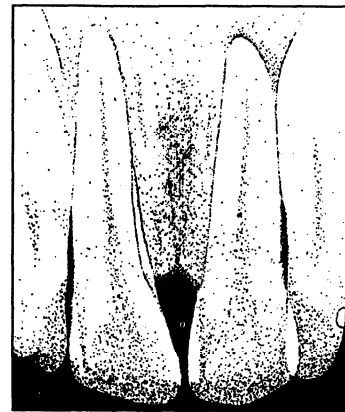

Figure 1-27.—Elongated image.

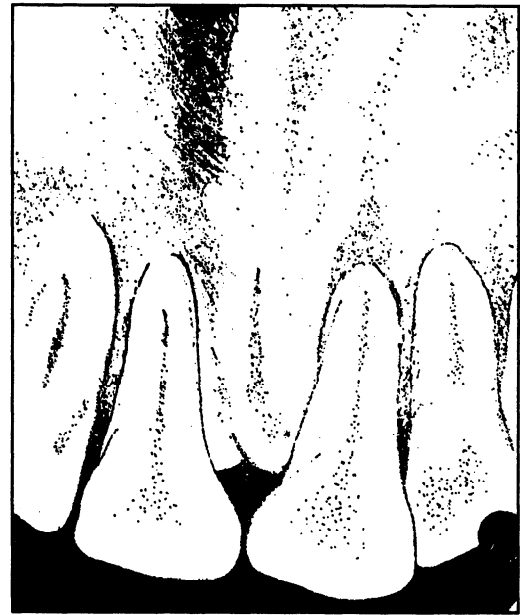


Figure 1-28.—Foreshortened image.

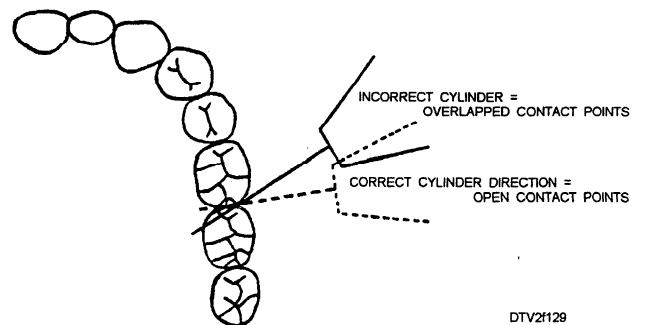


Figure 1-29.—Correct and incorrect cylinder direction.

manufacturer's instructions for correct time/impulse settings. Remember to reduce the kVp by 5 when taking radiographs in edentulous areas, and to 70 when taking radiographs on children.

2. Position the patient as shown in figure 1-23 for maxillary radiographs or figure 1-24 for mandibular radiographs. Remember that the patient's midsagittal plane must be perpendicular to the floor.

3. Position the film packet in the patient's mouth. Have the patient hold the film packet in place with a pair of hemostats or other holding device.

4. Set the vertical angulation of the tube head according to the chart in figure 1-26.

5. Center the tube head cylinder on the area to be radiographed. To simplify this process, the numbered anatomical landmarks are provided in figure 1-30. Take radiographs of the area by centering the tube head cylinder on these landmarks:

- Maxillary incisor area: Landmark 1, the tip of the nose.
- Maxillary cuspid area: Landmark 2, beside the ala of the nose.
- Maxillary bicuspid area: Landmark 3, below the pupil of the eye.
- Maxillary molar area: Landmark 4, below the outer angle of the eye and below the zygomatic bone.
- Mandibular incisor area: Landmark 5, the tip of the chin.
- Mandibular cuspid area: Landmark 6, directly below landmark 2 1/4 inches above the lower border of the mandible.

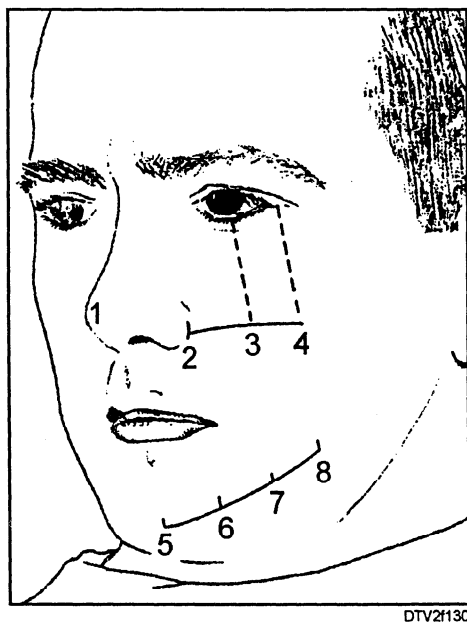


Figure 1-30.—Cylinder positioning landmarks for periapical radiographs.

- Mandibular bicuspid area: Landmark 7, directly below landmark 3 1/4 inches above the lower border of the mandible.
- Mandibular molar area: Landmark 8, directly below landmark 4 1/4 inches above the lower border of the mandible.

6. When you have the tube head cylinder centered on the horizontal landmark, double check to make sure that you have the correct horizontal angulation. The central X-ray beam should be projected straight through embrasures of the teeth to be radiographed.

7. Make the exposure.

8. Remove the film packet from the patient's mouth and place it in a clean paper cup. Place the disposable container in a lead container or behind a protective screen before making the next exposure.

### INTERPROXIMAL (BITEWING) EXAMINATION

The interproximal examination reveals the presence of interproximal caries, certain pulp conditions, overhanging restorations, improperly fitting crowns, recurrent caries beneath restorations, and resorption of the alveolar bone.

A typical interproximal radiograph (fig. 1-31) records in a single exposure the coronal and cervical portions of both maxillary and mandibular teeth, along with the alveolar bone of the region.

Bitewing X-ray film packets are used for the interpromixal examination. The bitewing film packet (fig. 1-32) has a paper tab, or wing, that the patient bites on to hold the packet in place during the exposure (thus the name bitewing).

Interpromixal radiographs can be made using either the paralleling technique or the bisecting angle technique.


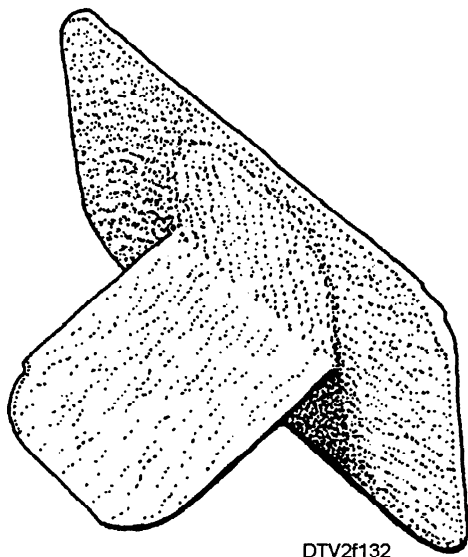


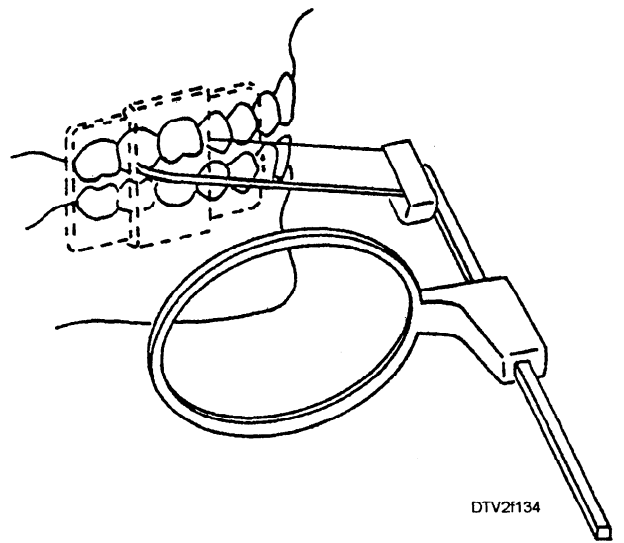
Figure 1-31.—Typical interproximal (bitewing) radiograph.





DTV2f132

Figure 1-32.—Bitewing film packet.



DTV2f134

Figure 1-34.—Paralleling device positioned for interproximal radiographs.

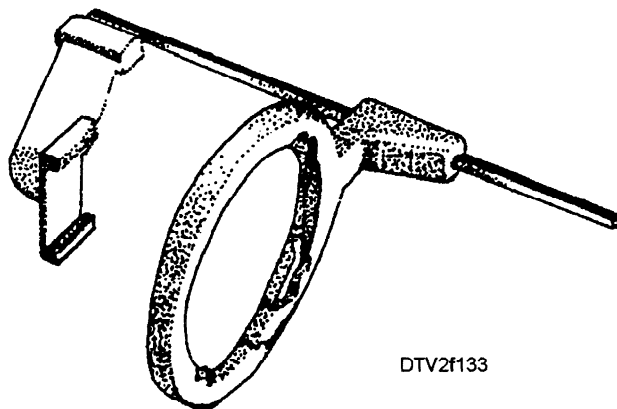
## PARALLEL PLACEMENT TECHNIQUE

The following procedures describe this technique:

1. Program the X-ray machine for the discussed time, mA settings, and kVp settings.

2. Prepare the inter-proximal paralleling device (fig. 1-33). Fold the bitewing tab against the film packet and insert the packet into the bite-block so that the printed side faces the backing support. Insert the end of the indicator rod into the holes in the bite-block. Slide the locator ring onto the indicator rod. Look through the locator ring to see if the bite-block is centered in the ring. If it is, the paralleling device is ready for positioning in the patient's mouth.

3. Position the paralleling device with film in the patient's mouth so that the anterior edge of the film touches the distal surface of the mandibular cuspid (fig. 1-34). Have the patient close gently but firmly on the bite-block to hold the film in position.



DTV2f133

Figure 1-33.—Interproximal paralleling device.

4. Slide the locator ring down the indicator rod until the ring almost touches the surface of the patient's face. Then, align the tube head using the same technique as previously described for the paralleling device.

5. Make the exposure. After making the exposure, put the exposed film in a lead lined container or behind a protective screen. You are now ready to take the radiograph on the opposite side of the patient's mouth.

## BISECTING-ANGLE TECHNIQUE

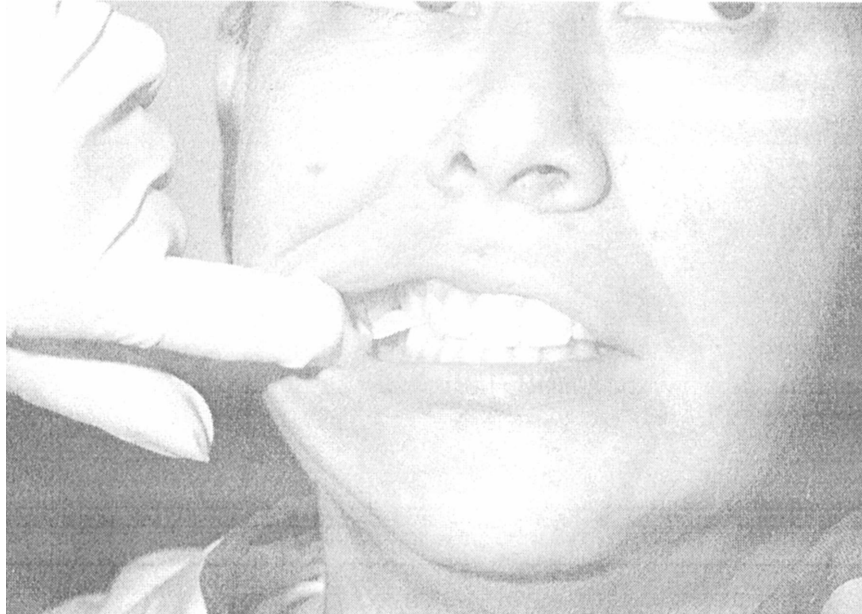The following procedures describe this technique:

1. Program the X-ray machine for the discussed time, mA settings, and kVp settings.

2. Position the patient so that the ala-tragus line is parallel with the floor, and the midsagittal plane is perpendicular to the floor.

3. Position the film packet in the patient's mouth. Hold the wing of the packet between your thumb and index finger. Place the lower edge of the packet between the tongue and the lingual surfaces of the mandibular teeth. Position the packet so that its anterior edge touches the distal surface of the mandibular cuspid. Rest the wing of the packet on the occlusal surfaces of the mandibular teeth. Instruct the patient to close slowly. As the patient's maxillary teeth contact your index finger, roll your finger out facially, permitting the patient's teeth to close on the wing (fig. 1-35). The film packet is now positioned.

4. Set the vertical angulation of the tube head at  $+5^{\circ}$  to  $+10^{\circ}$ .



DTV2f135

**Figure 1-35.—Patient closing on wing.**

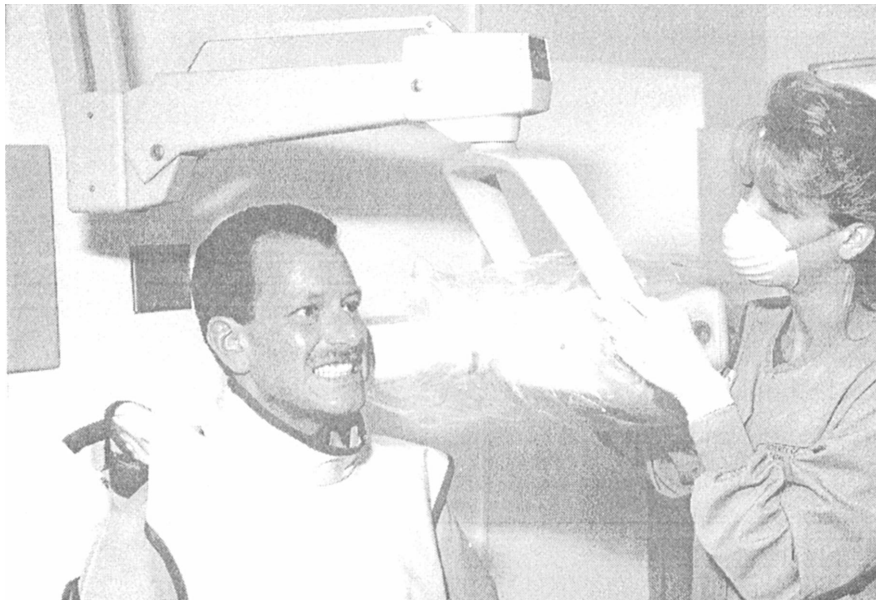
5. Center the tube head cylinder on the wing of the film packet. Be sure that the central X-ray beam passes through the embrasures as shown in figure 1-36.

6. Make the exposure. After making the exposure, put the exposed film in a clean paper cup and place in a lead lined container or behind a protective screen. You are now ready to take the radiograph on the opposite side of the patient's mouth.

### **OCCLUSAL EXAMINATION**

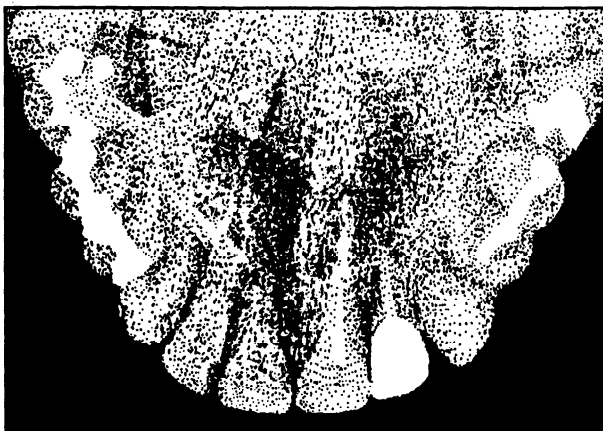
An occlusal examination is usually conducted when fractures of the jaw or gross pathological conditions are suspected. A typical occlusal radiograph (fig. 1-37) shows a large area of the maxillary or mandibular arch.

The occlusal film packet is shaped much like the periapical packet, only larger. Unlike the periapical



DTV2f136

**Figure 1-36.—Centering tube head cylinder.**



DTV21137

Figure 1-37.—Typical maxillary anterior occlusal radiograph.

and bitewing packets, the occlusal packet contains two X-ray films. This allows different developing times to be used for these films. The finished radiographs can then be compared for diagnostic purposes.

Occlusal radiographs are exposed using the bisected angle technique.

### MAXILLARY OCCLUSAL RADIOGRAPHS

Maxillary occlusal radiographs are taken by using the following procedures:

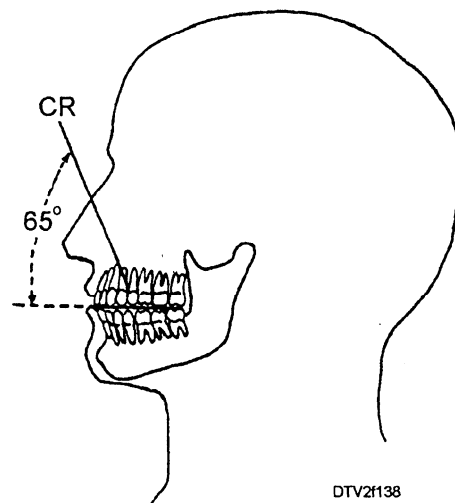
1. Set the X-ray machine at 10 mA, 90 kVp, and 60 impulses (1 second). (Reduce the kilovoltage 5 kVp if the arch is edentulous. Use 70 kVp if the patient is a child.)

2. Position the patient so that the ala-tragus line is parallel with the floor, and the mid-sagittal plane is perpendicular to the floor.

3. Place the film in the patient's mouth. Occlusal films are normally very comfortable. Have the patient relax the muscles of the mouth and cheek as much as possible. The pebbled surface of the packet should be toward the occlusal surfaces of the maxillary teeth, and the narrow side of the packet toward the patient's cheeks. To place the packet, retract one corner of the patient's mouth until the packet can be inserted. Position the packet far enough in the mouth so that it covers all the teeth. Special care must be taken to avoid gagging the patient. Have the patient close gently but firmly on the packet to hold it in place.

4. Position the tube head.

- a. For maxillary anterior occlusal radiographs, set the vertical angulation of the tube head at +65°. Center the tube head cylinder on the bridge of the



DTV21138

Figure 1-38.—Projection of central ray (CR) for maxillary anterior occlusal radiographs.

patient's nose so that the central X-ray beam will be projected as shown in fig. 1-38.

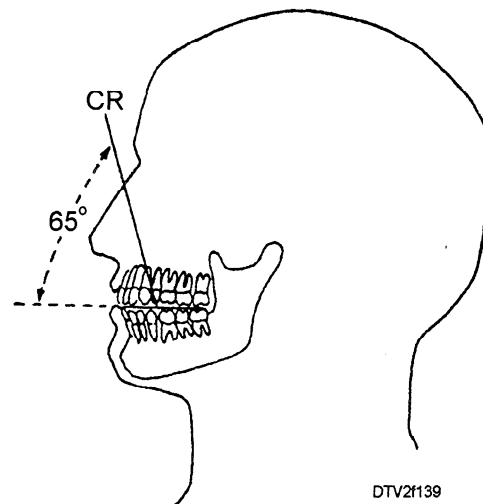
- b. For maxillary posterior occlusal radiographs, set the vertical angulation of the tube head at +75°. Center the tube head at the top of the patient's nose so that the central X-ray beam will be projected as shown in fig. 1-39.

5. Make the exposure.

### MANDIBULAR OCCLUSAL RADIOGRAPHS

Mandibular occlusal radiographs are taken by using the following procedures:

1. Program the X-ray machine for 10 mA, 90 kVp, and 60 impulses (1 second). (Reduce the kVp setting for edentulous patients and children as discussed earlier.)



DTV21139

Figure 1-39.—Projection of central ray (CR) for maxillary posterior occlusal radiographs.

2. Position the patient.

a. For mandibular anterior occlusal radiographs, position the patient so that the ala-tragus line is at a 45° angle with the floor, and the midsagittal plane is perpendicular to the floor.

b. For mandibular posterior occlusal radiographs, position the patient so that the ala-tragus line and mid-sagittal plane are perpendicular to the floor.

3. Place the film packet in the patient's mouth with the pebbled surface toward the occlusal surfaces of the mandibular teeth, and the short sides of the packet are toward the patient's cheeks. Have the patient close gently on the packet to hold it in place.

4. Position the tube head.

a. For mandibular anterior occlusal radiographs, set the vertical angulation of the tube head at -10°. Center the tube head cylinder on the tip of the patient's chin so that the central X-ray beam will be projected as shown in figure 1-40.

b. For mandibular posterior occlusal radiographs, set the vertical angulation of the tube head at 0°. Center the tube head cylinder beneath the patient's chin so that the central X-ray beam will be projected as shown in figure 1-41.

5. Make the exposures.

### INFECTION CONTROL

It is extremely important to pay attention to infection control when taking radiographs. Both the radiographic equipment and film can become contaminated and may result in the transmission of infectious agents. To protect themselves and the

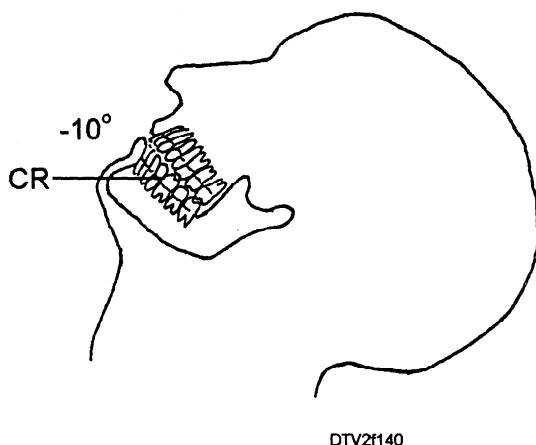


Figure 1-40.—Projection of central ray (CR) for mandibular anterior occlusal radiographs.

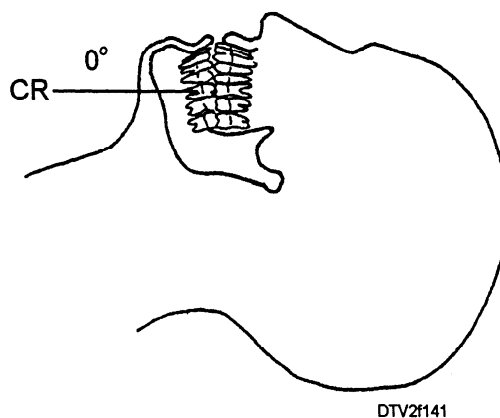


Figure 1-41.—Projection of central ray (CR) for mandibular posterior occlusal radiographs.

patients, dental personnel must maintain infection control standards in the radiology area similar to those used in the DTR. Information and procedures on the Dental Infection Control Program can be found in BUMEDINST 6600.10.

### HANDWASHING

Follow rigid handwashing procedures when treating a radiology patient. Wear gloves when placing intraoral films and handling contaminated film packets.

### DARKROOM

Disinfect all counter surfaces daily, and any other areas that might become contaminated such as doorknobs, light switches, and other surfaces that you might come in contact with.

### FILM POSITIONING DEVICES

Film positioning devices should be disposable (single use) or heat sterilized between patients. Your command should have an adequate supply of film positioning devices to treat your daily patient load. If supplies are short, you may disinfect film positioning devices between patients by immersion in an EPA-registered chemical disinfection such as a 2 percent glutaraldehyde. Rinse thoroughly after disinfection. Follow manufacturer's instructions for high-level disinfection.

### PANORAMIC UNIT BITE-BLOCKS

Use a disposable panoramic unit bite block cover for each patient. When disposable covers are not available, disinfect bite blocks as you would a film holding device.

## **INTRAORAL FILM PACKETS**

Intraoral film packets become contaminated when they are placed in a patient's mouth during exposure. We will explain procedures on how to handle and process contaminated intraoral film packets from the X-ray room to the dark room to avoid cross contamination. Procedures using an automatic film processor with and without a daylight loader are explained next.

### **Automatic Film Processors Without a Daylight Loader**

Procedures for using an automatic film processor without a daylight loader are as follows:

1. Wearing disposable gloves, expose an intraoral radiograph.
2. Place intraoral film packets removed from the patient's mouth directly into a clean paper cup previously set aside for this purpose. Do not contaminate the cup with soiled gloves.
3. Transfer cup to dark room.
4. While wearing the gloves used to take the radiograph, open the film packets and drop the film onto a clean paper towel without touching the film.
5. Discard film wrappers directly into a lined refuse container to prevent contamination of the darkroom work surfaces.
6. Place lead foil backing in a designated storage container.
7. Remove gloves and feed the uncontaminated film into the developer without special precautions.
8. Disinfect all areas and set up for your next patient.

### **Automatic Film Processors With a Daylight Loader**

When using an automatic film processor with a daylight loader, contamination of the fabric light shield is likely to be a problem. Since there is no way to disinfect this shield, disposable plastic film packet covers should be used to eliminate contamination of the fabric light shield by oral fluids and glove residue. Daylight loaders should be used only when a darkroom is not available.

## **Disposable Plastic Film Packets**


The following is a recommended technique for processing X-ray film with disposable film packet covers when using a daylight loader:

1. Wearing disposable gloves, expose an intraoral radiograph film with a disposable plastic film packet cover on it.
2. Still wearing the contaminated gloves, open the disposable plastic film packet containing the exposed X-ray film and using a sterile drop method, release the X-ray film into a clean paper cup previously set aside for this purpose.
3. Dispose of contaminated plastic film cover and gloves in a lined refuse container. Wash hands to remove powder from gloves and dry.
4. Open daylight loader and place the clean paper cup containing the exposed X-ray film inside. Close lid.
5. Place clean ungloved hands through fabric light shield and open film packet. Process X-ray film.
6. Open daylight loader and separate lead foil backing from film wrappers. Place lead foil in a designated storage container.
7. Discard film wrappers and paper cup into a lined refuse container.

### **Alternate Method When Not Using Disposable Film Covers**

Some X-ray departments may not have disposable plastic film covers for use with automatic film processors with a daylight loader. The following is an alternate method to prevent the fabric light shield from being contaminated:

1. Place the exposed film in a clean paper cup previously set aside for this purpose.
2. Remove soiled gloves and put on a pair of clean gloves.
3. Place the cup through the top of the processing box and close the lid.
4. Place clean gloved hands through the fabric light shield as shown in figure 1-42, unwrap the film packet, and drop the film onto the surface inside the loader.
5. Place the film wrapping into the cup. Remove the gloves, turn them inside out, and place them in the paper cup.



DTV2f142

**Figure 1-42.—Placing clean gloved hands through fabric light shield with a daylight loader.**

6. Carefully grasp the film by its edges to avoid transferring powder from your hands onto the film, drop the film in the chute for developing.

7. Remove hands from the loader, lift the lid, and dispose of paper cup and waste. Ensure all lead foil is collected and stored.

8. Wash hands thoroughly.

9. If the fabric light shield sleeves become contaminated, they may be gas sterilized.


### **X-RAY CHAIR**

Use an EPA-registered intermediate-level disinfectant on the X-ray chair daily or when visibly

contaminated. Change paper or plastic headrest covers after each patient.

### **X-RAY TUBEHEAD AND CONTROLS**

Cover those areas contacted by the staff and patients with plastic wrap (fig. 1-43) or disposable drapes. Be careful that these coverings do not interfere with the flow of cooling air to the X-ray tube head. Change after each patient. When wiping the tubehead and controls with liquid disinfectants, exercise care to prevent disinfectant from leaking into the tube head seams and exposure controls.



DTV2f143

**Figure 1-43.—X-ray tube head covered with plastic wrap.**

## FILM PROCESSING

After the patient has been radiographed, the X-ray film is processed to produce the finished radiographs. There are five basic steps involved in processing X-ray film: developing, rinsing, fixing, washing, and drying. You can process the film manually, or use an automatic film processor. For the most part, manual processing is used for a backup method for the automatic film processor and will not be discussed. If your command has manual processing capabilities, refer to the manufacturer's operating instructions. Because our discussion concerns both darkroom procedures and film processing, we will cover the darkroom first.

### DARKROOM PROCEDURES

The darkroom has two sources of illumination: white light and safelight. A white light is a standard ceiling light. It provides regular illumination for mixing solutions and cleaning the darkroom. An unwrapped, unprocessed X-ray film must never be exposed to white light.

Exposed film is useless. A safelight, which contains a 15 watt bulb with a special filter, is the only safe source of illumination in the darkroom when processing intraoral and panoramic X-ray film. The safelight must be located no less than 4 feet from the work surface so that you can open film packets and process films safely. Limit the length of exposure of undeveloped dental films to the safelight for no more than 2 minutes. Films left out exceeding this time might get a fogged image (discussed under faulty radiographs).

Occasionally, films are ruined because of light leakage. White light may leak through the filter on the safelight or it may leak into the darkroom from an outside source. A simple test will enable you to detect leakage.

To check for possible light leakage from an outside source, perform the test with all lights off, including the safelight.

Take a packet of unexposed X-ray film, open the film packet, and remove the film. Lay the film on the workbench, and place a penny over it for a period of 5 minutes. Then, process the film using the procedures provided later in this chapter. The processed film should show no image. If the outline of the penny can be seen, there is light leakage and you should inform your supervisor. You should perform this test at every

location in the darkroom where unwrapped film is being processed.

### SAFETY PRECAUTIONS

Because of the alkaline and acid nature of the developer and fixer solutions, minor chemical irritation or burns can occur when they come in contact with the skin, the eyes, and the mouth. Use caution when stirring or mixing solutions. Always wear rubber gloves and protective eye wear or a protective face shield and an apron when working around these solutions. If the solutions come in contact with the skin, flush the area with large amounts of water. If the solutions accidentally splash into the eyes or mouth, flush with large amounts of water and immediately seek medical attention. Fixer solution can stain and discolor clothing.

### AUTOMATIC PROCESSING

Automatic processing is the most commonly used method of processing dental radiographs in the Navy. The automatic film processor mechanically transports exposed X-ray film through the developing, fixing, washing, and drying cycles. Automatic processing is quicker than manual processing, and it produces finished radiographs of uniform quality. A variety of automatic film processors are in use in the Navy and they can be generally classified as small or large.


#### Large Automatic Film Processor

The large automatic processor (fig. 1-44) processes all sizes of dental radiographs including intraoral, occlusal, panoramic, and 8-inch x 10-inch cephalometric films.

This processor will be located in the darkroom. The X-ray film must be inserted in the processor under safelight conditions. Large automatic processors can be equipped with daylight loaders, eliminating the need for a darkroom.

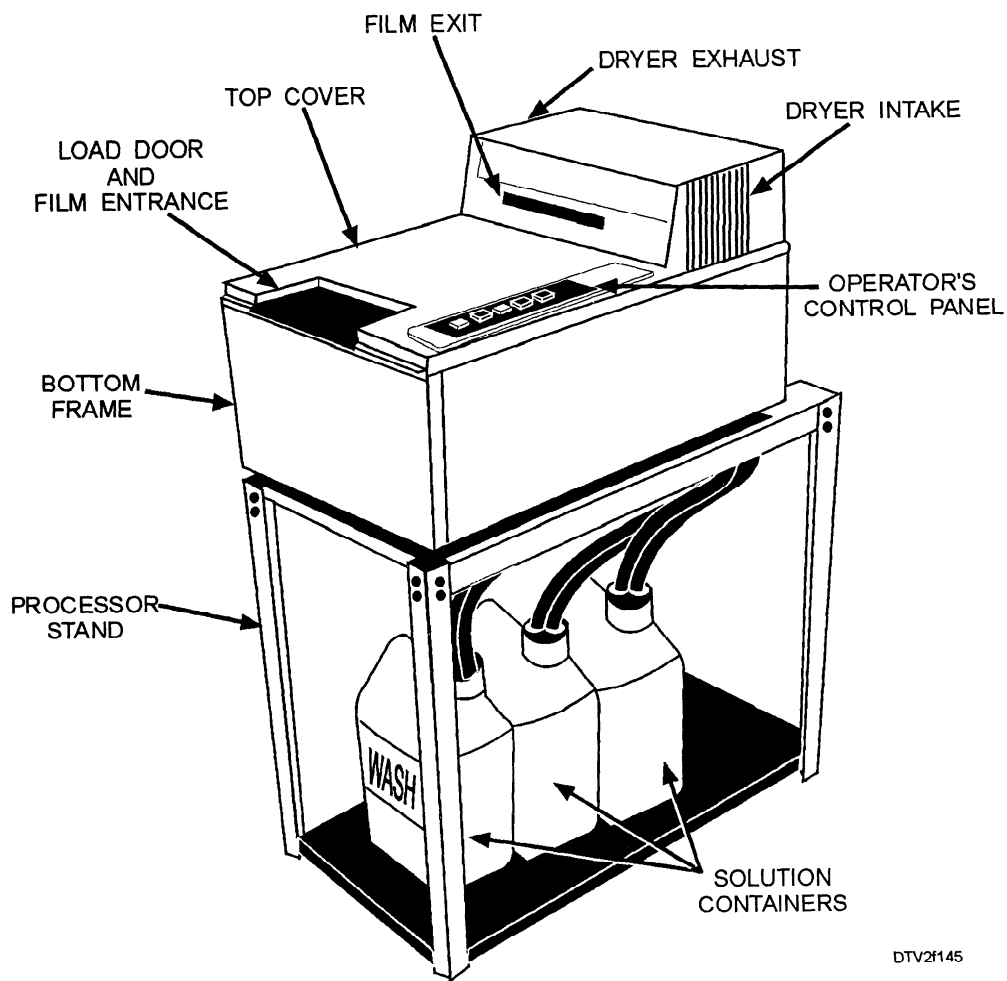
#### Operational Check

Perform the operational check at the beginning of each day to ensure that the processor is in good working order. It is a complex piece of equipment, so read the manufacturer's operational manual very carefully. Never attempt to repair the components inside the processor. There are a variety of large automatic processors used in the Navy today. The automatic processor's components, procedures, and



DTV2f144

Figure 1-44.—Large automatic processor.



DTV2f145

Figure 1-45.—External components of a large automatic processor.



maintenance described next are for the specific processor shown. If you work with a different make or model of an automated processor, refer to that manufacturer's operational manual for operating instructions.

Figure 1-45 shows the main external components of the large automatic film processor. Figure 1-46 shows the internal components when the top cover is opened from the processor. Figure 1-47 shows the functions of the operator's control panel.

The daily operational check of the large automatic processor is performed as follows:

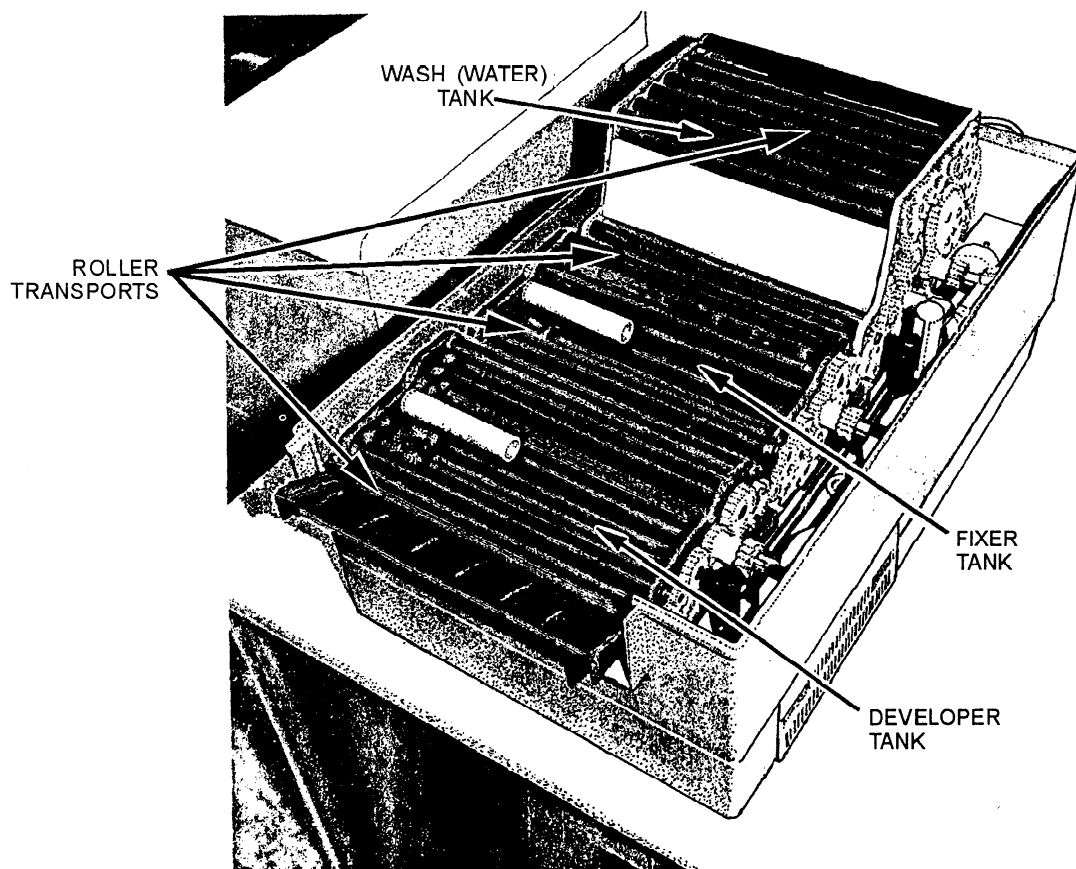
1. Plug the power supply cable into the power outlet.
2. Check the solutions. Most automatic processors are equipped with a replenisher, which automatically replenishes solutions when the power is turned on. An automatic processor without an automatic replenisher requires that you manually replenish the developer and fixer solutions. Pour the solutions slowly to avoid splashing. Direct the pouring stream to the center of the tank away from the drain tubes.

3. Turn on the external water supply valve. This valve is normally located close to and above the automatic processor. If not equipped with external water supply, change the water in wash water container and refill with fresh water.

4. Activate the automatic processor by depressing the power on switch. If equipped with an automatic replenishing system, the internal oscillating pumps will now cycle and fill the solution tanks to their proper levels. When the low solution level lamp has gone out, the solution heater will start and the transports will turn. **Do not process films at this time.**

5. After 10 to 15 minutes, The ready lamp will illuminate. This indicates that the proper processing temperature has been reached.

6. Depress the run/standby switch to the run position. Insert an 8-inch x 10-inch cleaning film into the processor receiving tracks. The cleaning film cleans the rollers of accumulated deposits, dirt, and debris. Use a new cleaning film every week. After the cleaning film exits the processor, depress the run/standby switch to the standby position.



DTV2f146

Figure 1-46.—Internal components of a large automatic processor.

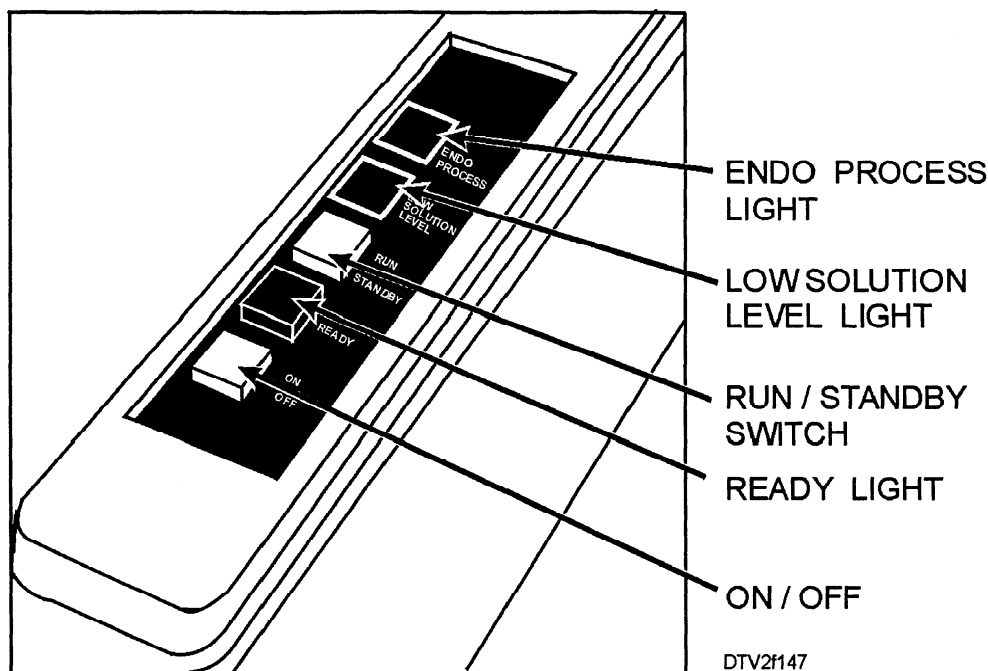


Figure 1-47.—Operator's control panel.

7. **Do not depress the on/off switch.** It should remain on for the entire working day. As long as the on/off switch is in the on position, several functions will occur throughout the day.

a. Approximately every 4 minutes, the oscillating pumps will cycle for several seconds. This action will maintain a uniform solution strength.

b. The solution heater will maintain a proper processing temperature.

c. The solution agitators will intermittently cycle, keeping the solutions well mixed.

d. The roller transports will intermittently turn, allowing the solutions to wet the rollers. This will prevent dried solution deposits from forming.

e. At the end of the working day, depress the on/off switch to the off position.

8. Some models may require that you turn the water inlet valve on the plumbing line to the off position.

### Procedures For Processing Film

If you are processing a large quantity of X-ray film, you must avoid any mixup. To do this, after you insert one patient's X-ray films, wait 15 seconds before inserting the next patient's films. After inserting the X-ray films of each patient, set the X-ray mount, envelope, or identification label aside, making sure to

keep them in the order in which they were processed. This will help you match the processed radiographs to the patient's unit, envelope, or identification label when the film exits the processor.

To process X-ray films, you should follow these procedures:

1. The recommended complete processing time is 5 minutes at normal speed. If your processor has an endo speed button, this can process X-rays in 2 minutes. Endo speed is used when the dentist wants to process the film quickly. The developer temperature should be at 82°F (28°C) and the water temperature 50°F to 90°F.

2. Depress the run/standby switch to the run position to begin automatic processing.

3. Insert the X-ray film. Unwrap the film and insert it into the film receiving slot. (Remember to open the film under safelight conditions). The automatic processors can have up to six tracks to accept intraoral films. To prevent overlapping, feed the film lengthwise into every other track (e.g., insert first three films into tracks 1, 3, and 5; insert the second three films into tracks 2, 4, and 6). Feed large films lengthwise one at a time, allowing at least 15 seconds between films. Allow 15 seconds to expire after the last film disappears before inserting another film or turning on the lights or opening the darkroom door. Once the films have been inserted, the total processing time will take 5 minutes unless on the endo cycle.

To obtain the best quality radiographs, follow the film manufacturer's processing guidelines. If radiographs processed at 5 minutes and 82°F (28°C) are too dark, reduce the X-ray exposure time setting.

When the films have been processed, the finished radiographs will exit the processor on the film track and fall into the film receptacle. When the last film has exited the unit, depress the run/standby switch to the standby position. The unit will remain on standby throughout the day.

### **Securing The Processor**

The processor should be secured at the end of the day. The securing procedures are as follows:

1. Depress the on/off switch to the off position.
2. Turn the water supply valve to the off position. (Some models without water plumbing will not require this step.)
3. Unplug the power supply cable.
4. Wipe the cover and housing of the processor with a damp sponge or cloth.

### **Chemistry Change**

Change the developer and fixer at a minimum of once every 3 to 4 weeks. If a large quantity of X-rays has been processed, change the developer sooner. Replenish the solutions following the manufacturer's instructions.

**NOTE:** The solutions used for automatic processing are not the same as those used for manual processing.

### **Maintenance Schedule**

You are responsible only for user maintenance on the processor; repairs are the responsibility of the dental equipment repair technician.

Monthly maintenance consists of cleaning the roller transports and solution tanks. Weekly maintenance consists of soaking the transport rollers, solution agitators, and other removable internal parts for 5 to 10 minutes with a processor cleaner.

**NOTE:** Any time the processor cover is lifted and maintenance is being performed, you must wear a safety face shield, apron, and protective gloves.

The quality of the processed radiographs are reflected in the maintenance of the processor.

Improper maintenance can cause radiographs of poor diagnostic quality, and may cause patients to have their radiographs taken over. Always follow manufacturer's instructions for correct maintenance and operating procedures.

To keep the processor in good operating condition, do not place heavy objects on top of the processor or use the top as a film loading or storage area. Do not turn the power switch on when the solution tanks are empty. Also, do not use steel wool or abrasive scouring powder when cleaning tanks or metal parts of the processor.

### **Small Automatic Film Processor**


The small automatic processor processes only bitewing and periapical dental radiographs. The processor solutions are self contained and require no plumbing.

The small processor in figure 1-48, may be located in a darkroom, but because of its small size and compatibility with a daylight loader, it is commonly found in endodontic departments, small dental clinics, and on board Navy ships where no darkroom is available.

### **Operational Check and Processing**


Refer to the instruction manual for the assembly and disassembly of processor components. The daily operational check for the small automatic processor is performed as follows:

1. Remove process cover and check the level of the solutions. Tank capacity for the developer and fixer tanks is 1 quart each. The wash tank holds 1 1/2 quarts of water. Figure 1-49 shows the solution tanks.
2. Plug the power supply cable into the power outlet.
3. Depress power (left) switch (fig. 1-50). Directly above the left switch, the red light goes on, indicating the chemistry heaters are on. When the green light (right) flickers (in about 15 minutes, depending on room temperature) X-rays may be processed.
4. To process films, depress the process (right) switch. The green ready light will alternate between flickering and full on, indicating an optimum 74° to 76°F temperature is being maintained.
5. Refer to the manufacturer's instruction manual procedures for processing bitewing and periapical films.



DTV2f148

**Figure 1-48.—Small automatic processor.**



DTV2f149

**Figure 1-49.—Solution tanks.**

### **Securing The Processor**

Turn off the power switch (left) and unplug power supply cable from outlet.

### **Chemistry Change**

Change the developer and fixer every 300 to 350 films or in 2 weeks, whichever is sooner. The water in the wash tank is changed every 100 to 125 films or in 1 week, whichever is sooner. When changing chemicals, clean the tanks with water and dry prior to placing new chemicals in them. Use the same safety precautions as mentioned before when handling chemicals.


### **Maintenance Schedule**

Daily, wipe the external parts of the processor with a dry or slightly moist, lint free cloth. Refer to the instruction manual for the complete maintenance schedule.

### **FAULTY RADIOGRAPHS**

Faulty radiographs are usually caused by the incorrect positioning of the film packet or the tube head; incorrect kVp, mA and time setting; or by incorrect processing procedures.

Some common causes of faulty radiographs due to tube head and film misalignment have already been




DTV2f150

**Figure 1-50.—Operator control panel.**

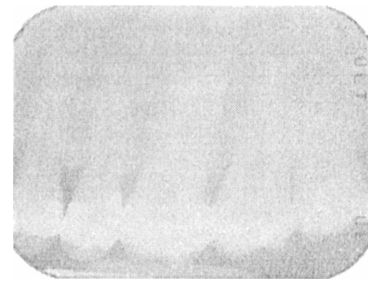
discussed (e.g., incorrect horizontal angulation produces superimposed radiographic images, and incorrect vertical angulation produces images that may be foreshortened or elongated.) The following are additional causes of faulty radiographs:

- No image (fig. 1-51): The film was immersed in the fixer before the developer. If the film is completely clear, it was never exposed.
- Very light image (fig. 1-52): The film was underexposed (kilovoltage too low); the developer was



DTV2f151

**Figure 1-51.—No image.**

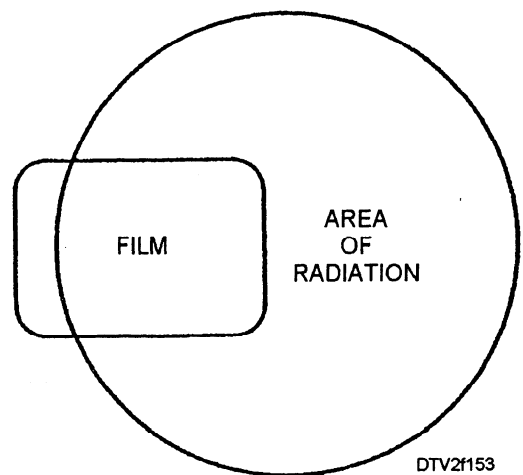


DTV2f152

**Figure 1-52.—Very light image.**

weak; or the film was not left in the developer long enough.

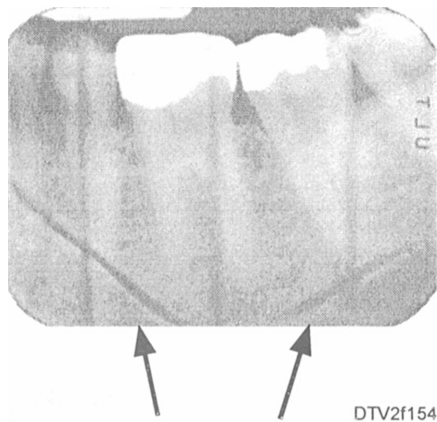
- Very dark image: The film was over-exposed (kilovoltage too high); the developer was too warm; or the film was left in the developer too long.
- Partial image (fig. 1-53): The film was not completely immersed in the developer; the film came into contact with other film or the side of the tank while in the developer; or the film or tube head was incorrectly positioned (cone cutting).
- Blurred image: The patient or tube head moved during the exposure.
- Fogged film: The film was outdated or contaminated; the film was overexposed by being held too close to the safelight; the film was exposed to stray radiation, excessive heat, chemical fumes, or lightleaks in the darkroom; the developer was improperly mixed, contaminated, or too hot.
- Streaked or stained film: The film was insufficiently washed or fixed; the processing solutions were dirty; or the film hanger was dirty.



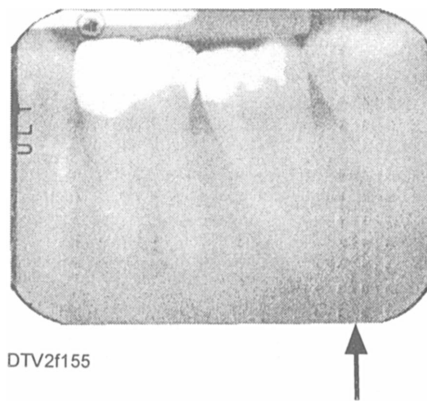
DTV2f153

**Figure 1-53.—Partial image (cone cutting).**

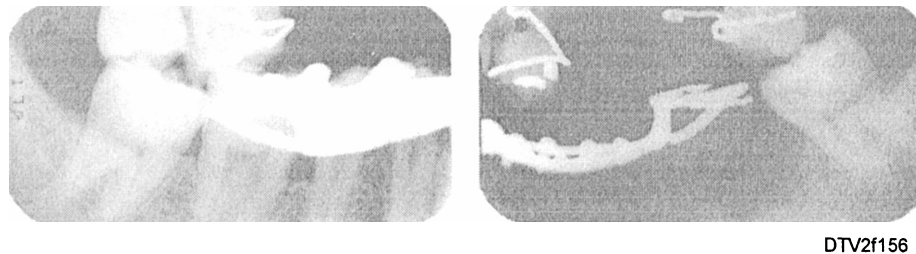
- Reticulation: There was a too rapid change in temperature during processing (e.g., the film was taken from a warm developer to a cold rinse).
- Crescent-shaped lines (fig. 1-54): The film packet was creased or bent.
- Herringbone image (fig. 1-55): The wrong side of the film, packet was facing the source of the X-ray beam during exposure causing the embossing pattern from the lead backing to appear on the film.



**Figure 1-54.—Crescent-shaped lines on film.**



**Figure 1-55.—Herringbone image.**



**Figure 1-56.—Foreign object image.**

- Black areas: The film was pulled too rapidly from its black paper wrapping, causing a discharge of static electricity.
- White spots: The developer failed to work on these areas because of dirt or air bubbles.
- Foreign object image (fig. 1-56): Dentures or other objects were in the patient's mouth during the exposure.

## FILM VIEWERS

The film viewer consists of a metal case with a back-lighted screen. The viewer is used to mount and examine radiographs. Figure 1-57 shows a typical desk mount film viewer. Never light the film viewer in the darkroom when you are working with unwrapped, unprocessed film. Keep the viewer screen clean at all times.

## MOUNTING RADIOGRAPHS

After processing the X-ray film, you will mount the finished radiographs in cardboard or plastic holders. Mounting makes the radiographs easy to view, keeps them in a chronological order, and protects them from damage.

Mounted radiographs may be viewed from either the front or back of the mount. If viewed from the front, the teeth appear on the film as if you were looking directly into the patient's mouth. If viewed from the back, the teeth appear on the film as if you were sitting on the patient's tongue looking out. Always mount X-rays in anatomical order. After you mount the radiographs, file the mount in the patient's Dental Record. There will be times when the dental officer will want to retain the radiographs for diagnostic purposes (e.g., endodontics). These are normally placed in a drug envelope, labeled and dated, and placed in the dental record.





Figure 1-57.—Desk mount film viewer.

### INTERPROXIMAL (BITE-WING) MOUNTING

Figure 1-58 shows a serial mount for inter-proximal (bite-wing) radiographs. The mount contains slots for mounting five pairs of interpromixal radiographs for a patient taken at different times and mounted in chronological order. Serial mounting enables the dental officer to compare radiographs taken at different time intervals to detect changes in the patient's oral structures.

The front of the mount contains spaces for the patient's name and social security number, mount number, and the date of each exposure. Fill in this information whenever you start a new mount. After you have completed the necessary information on the front side, turn the mount over and lay it face down on a table top.

Place the radiographs on a flat, dry surface with the convex surface of the identifying "dimple" toward the observer. Pick up a radiograph by the edges. Hold it up to the, film viewer. The line representing the occlusal surface of the bicuspid and molars should gradually curve upward, forming one-half of a smile. If the line curves upward on the right, slide the radiograph into the right-hand slot on the back of the mount with the upward curve toward the outside of the mount. Keep the raised dimple facing you. If the line curves upward on the left, slide the radiograph into the left-hand slot. If both radiographs are mounted correctly, they will appear as shown in figure 1-58, forming a complete smile. Each time an additional pair of inter-proximal radiographs is mounted, enter the date on the line beneath the mounting slots.



DTV21158

Figure 1-58.—Interproximal (bitewing) serial mount.

## FULL MOUTH PERIAPICAL MOUNTING

Figure 1-59 shows a full mouth periapical film mount. The mount contains 14 slots for periapical radiographs and 2 slots for interproximal (bite-wing) radiographs.

When mounting full mouth periapical radiographs, you will be working with 14 radiographs; take care to sort and mount them correctly. To do this, you must be able to recognize certain maxillary and mandibular anatomical landmarks.

### ANATOMICAL LANDMARKS

During the following discussion, locate each anatomical landmark on figure 1-60. The landmarks are indicated by arrows.

#### Maxillary Incisor Area

Radiographs of this area usually show a large white region caused by the bone of the nasal septum (A in fig. 1-60).

#### Mandibular Incisor Area

Mandibular incisors are smaller than maxillary incisors. The mandibular incisor area has a network of tiny white lines around and below the roots (D in fig. 1-60).

#### Maxillary Cuspid and Bicuspid Areas

Radiographs of these areas usually show a distinct wavy white line above or near the apices of

the teeth (B in fig. 1-60). The wavy white line identifies the floor of the maxillary sinus. This white line is not found in radiographs of the mandibular arch.

#### Mandibular Cuspid and Bicuspid Areas


Radiographs of these areas show a fine network of tiny white lines around and below the roots and a dark area in the cuspid area representing the mental foramen (E in fig. 1-60).

#### Maxillary Molar Area

Radiographs of these areas show the maxillary arch and the roots of the maxillary molars curving slightly toward the rear of the mouth (C in fig. 1-60). Maxillary molars have three roots, they tend to be indistinct on radiographs. In addition, the radiographs will usually show a distinct wavy white line above or near the apexes of the teeth.

#### Mandibular Molar Area

Mandibular molars show two roots that are distinct on radiographs. The mandibular nerve canal frequently shows as a dark, narrow band running horizontally under the apexes of the mandibular molars. The mandibular arch and the roots of the molars curve slightly toward the rear of the mouth. An impacted third molar will often be present on radiographs of the mandibular molar areas (F in fig. 1-60).



DTV2f159


Figure 1-59.—Full mouth periapical mount.




## MAXILLARY LANDMARKS



A. INCISOR AREA




B. CUSPID AREA




C. MOLAR AREA

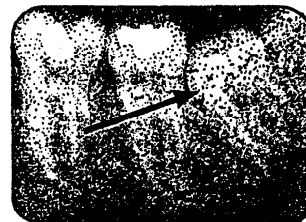
## MANDIBULAR LANDMARKS



D. INCISOR AREA



E. BICUSPID AREA



F. MOLAR AREA

DTV2f160

Figure 1-60.—Maxillary and mandibular radiographic landmarks.

## MOUNTING PROCEDURES

Place all the radiographs in the full mouth periapical series on a dry, flat working surface with the dimple side up. On the front of the film mount, enter the patient's name, social security number, rank/rate, the date, and the name of the dental treatment facility. Place the mount face down on the working surface. The two small arrows on the back of the mount should point toward you. Follow these steps to mount the radiographs:

1. Check each radiograph and make sure that the surface with the raised dimple faces you.

2. Mount interproximal radiographs. If interproximal (bite-wing) radiographs are included in the full mouth series, insert them in the slots provided as previously discussed.

3. Divide the radiographs into maxillary and mandibular groups. Using the film viewer, locate the anatomical landmarks discussed earlier. The maxillary radiographs are inserted in the 7 slots across the top of the film mount and the mandibular radiographs in the 7 slots across the bottom.

4. Insert the maxillary radiographs. First, identify the radiograph of the central incisor area. Keeping the side with the raised dimple facing toward you, rotate the

radiograph until the incisal edges of the teeth point down. With the back of the mount toward you, slide the radiograph into the incisor slot. When the radiograph is properly mounted, the side with the raised dimple will face you, and the incisal edges pointing down toward the center of the mount.

5. Work outward from the central incisor slot, inserting the rest of the maxillary radiographs in the following order: cuspid areas, bicuspid areas, and molar areas.

6. Insert the mandibular radiographs. Start with the radiographs of the central incisor areas and work outward. As before, the raised dots will be toward you and the incisal/occlusal surfaces of the teeth should be pointing upward toward the center of the mount.

When you have inserted all of the radiographs, hold the mounted radiographs up to the viewer. Double check to see that each radiograph is mounted correctly.

### PANORAMIC RADIOGRAPHS

The panoramic X-ray machine is used to produce an extraoral radiograph that shows both dental arches and the temporomandibular joints (fig. 1-61). The radiograph is made by rotating the tube head and film around the patient while the patient remains stationary. Because of the different manufacturers and models of

panoramic X-ray machines used in the Navy, this operation and maintenance will vary. Always refer to manufacturer's instruction manual prior to use.

The panoramic X-ray machine and control panel are shown in figures 1-62 and 1-63. Refer to these figures throughout the following discussion. You must be thoroughly familiar with the components shown before operating the machine.

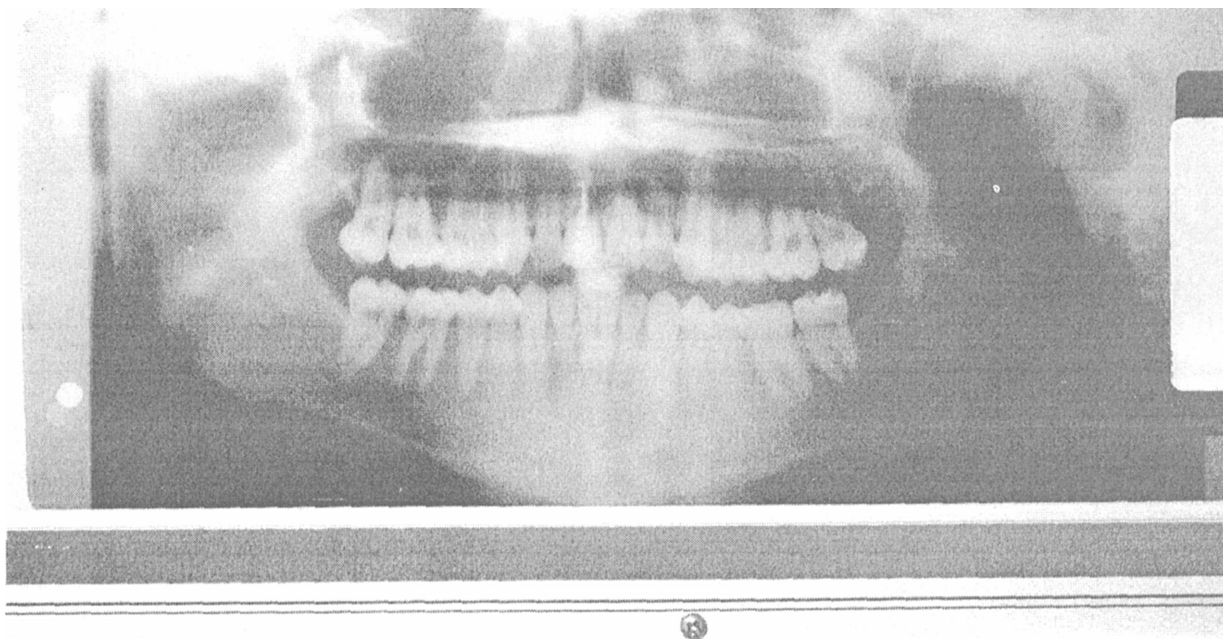### OPERATIONAL CHECK

The operational check for the panoramic X-ray machine is accomplished without a patient. To perform the operational readiness check, perform the following procedures as follows:

1. Turn on the pilot switch; the pilot light will illuminate.


2. Set the kVp selector switch to the desired voltage. Adjust the kVp meter as a reference for the desired kVp setting.

3. Select the mA settings, to be used. Adjust them according to the manufacturer's instructions. When you find the mA and kVp settings that give the best results, enter them on a technique values chart. Remember each manufacturer's film is different, so follow the recommendations.




DTV2f161

Figure 1-61.—Typical panoramic radiograph.



DTV2f162

Figure 1-62.—A panoramic X-ray machine.



DTV2f163

Figure 1-63.—A panoramic control panel.

**WARNING: When performing the operational check, keep the collimator covered with the lead cap.**

## **PREPARING THE FILM**

When the X-ray machine is operational, prepare the panoramic film. Load the film into a cassette drum, label it, and then mount it in the cassette drum assembly on the X-ray machine. To load and mount the cassette drum, follow the manufacturer's instructions.

## **LABELING THE CASSETTE**

The cassette is labeled for the purposes of orientation and patient identification.

To properly orient the finished radiograph so you can distinguish the left from the right side of the patient's dentition, tape a lead letter "R" in the lower right-hand corner on the outside of the cassette cover.

There are two ways to label the cassette for patient identification. You can use a self-adhesive label or an X-ray film identification printer. Follow the manufacturer's instructions when using the printer. The patient information includes: the patient's name (last name, first name, and middle initial), family member prefix code, social security number, and the date of the exposure.

## **REQUIREMENTS FOR A GOOD PANORAMIC RESULT**

Follow the manufacturer's operating instructions for complete operation of the panoramic X-ray machine before you attempt to use it. The following is

a list of important procedures that must be followed to ensure a good quality X-ray is produced.

- Make sure patient's back and cervical spine are as straight as possible.
- Check that the patient's mid-sagittal plane is centered within the unit.
- Ensure the patient's frankfurt plane is horizontal.
- Check that the anterior maxillary and mandibular teeth are located on the indents of the bite-block. If the patient's bite is abnormal, adjust mandible forward or backward to compensate.
- Observe patient to assure there is no movement during the radiographic procedure.

## **OPERATING THE PANORAMIC-RAY MACHINE**

With the machine operational and the film cassette drum in the cassette drum assembly, you are now ready to take the radiograph on the patient. Follow the manufacturer's instructions for patient positioning and operation. When the patient is positioned, explain the exposure procedures. Then make the exposure and process the film. You must wait 5 minutes between exposures to prevent overheating of the X-ray head.

## **USER MAINTENANCE**

The panoramic X-ray machine requires very little user maintenance. Wipe the metal and painted parts with a soft, dry cloth daily.

**Never** attempt to repair the panoramic X-ray machine yourself. Report malfunctions to your supervisor. All repairs are the responsibility of the dental equipment repair technician.

## CHAPTER 2

# DENTAL EXAMINATIONS

### INTRODUCTION

The dental examination is one of the basic professional services provided by the Navy dental team. Soon after you entered the military service, you received your first dental-oral examination to determine your dental health. Throughout your service with the Navy, you will receive annual or periodic dental examinations. The results of these examinations are recorded in your individual U.S. Navy Medical Outpatient and Dental Treatment Record (NAVMED 6150/21-30). The preparation of the NAVMED 6150/21-30 is discussed in *Dental Technician*, Volume 1, chapter 2. The Forensic Examination Section, which is located on the inside back cover of the NAVMED 6150/21-30, will be discussed in this chapter since it covers an examination.

Your responsibility is to assist the dentist in all areas of dental examinations. You must be able to understand and complete various dental forms used in the examination process that become a part of the NAVMED 6150/21-30. Information on dental examinations and related forms can be found in the *Manual of the Medical Department*, NAVMED P-117, chapters 6 and 15.

Dental examinations are performed by dentists in different areas of the dental clinic. The Oral Diagnosis Department has the responsibility of providing dental examinations and holding "sick-call" hours, while dentists and auxiliary personnel (hygienists and Dental Technicians) in other departments of the dental clinic also perform oral examinations. This chapter concentrates on your duties in pre-examination, examination types, occasions for dental examinations, dental classifications, designations, charting and abbreviations, recording dental treatment, additional dental treatment forms, and patient dismissal.

### PRE-EXAMINATION DUTIES

Before seating a patient for a dental examination, ensure that the operatory is neat and professional in appearance. Make sure the area is clean and the equipment is disinfected.

### PATIENT PREPARATION

The patient may be nervous, so try to put him/her at ease by using the communication skills that were discussed in *Dental Technician*, Volume 1, chapter 2, "Technical Administration and Responsibilities."

Introduce yourself and ask the patient for his or her dental record. Open the record and scan the Dental Health Questionnaire, NAVMED 6600/3. Look specifically for "yes" answers if the questions concerning contagious or infectious diseases, such as Hepatitis (Type), Human Immunodeficiency Virus (HIV), cold sores (herpes, etc.) were checked. When a patient has a "yes" answer, notify the dentist before treatment.

When the patient is seated, make him or her as comfortable as possible. Adjust the headrest and place the chair in the working position favored by the dentist, usually the fully reclined position shown in figure 2-1. In this position, the patient's head is level with the dentist's elbow when the dentist is seated on the dental stool.

After you have seated the patient and positioned the chair, turn on the operating light. To avoid shining the light in the patient's eyes, focus the light beam on the area beneath the patient's chin. Then, turn off the light until the dentist is ready to start the examination. When the dentist is ready, turn on the light and rotate the light up to the mouth.

Next you will need a patient napkin to drape the patient. A patient napkin holder attaches the patient napkin in place around the neck area. If the patient is a woman wearing lipstick, give her a tissue and politely ask her to remove the lipstick before the examination begins. If the patient is wearing dentures or removable partial dentures, ask him/her to remove them and place them in a cup of water. The dentist will need them standing by to evaluate proper fit and condition during the exam.

A patient who is wearing corrective glasses should be asked to leave them in place during the exam, while a patient not wearing corrective glasses should be given eye protection.

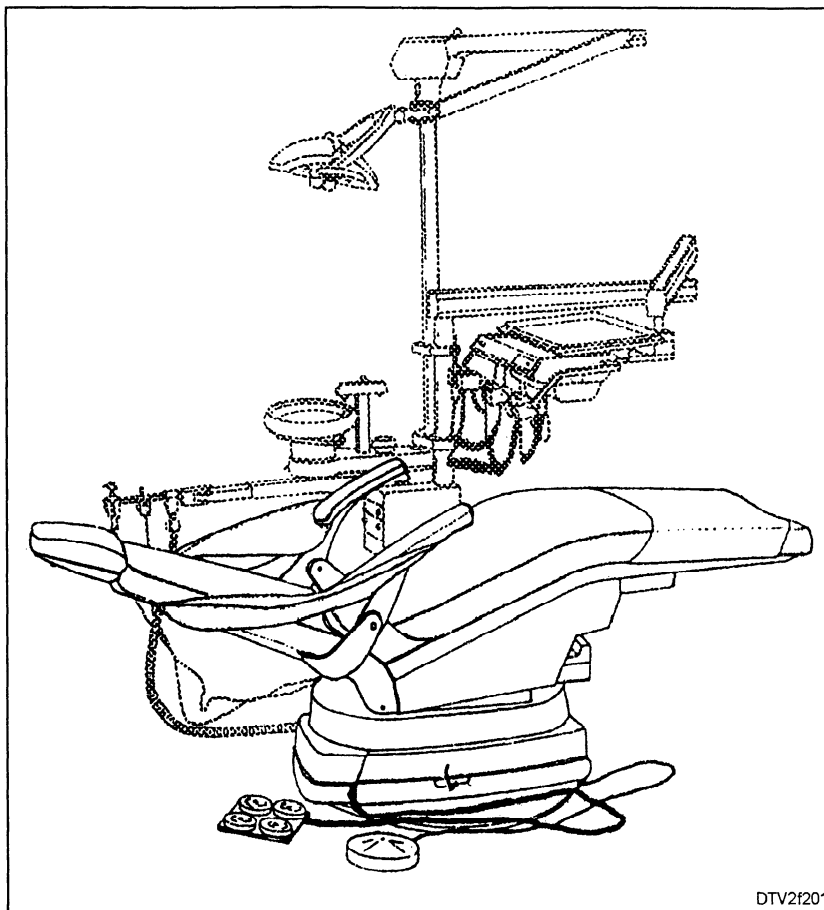


Figure 2-1.—Dental chair in working position.

## INSTRUMENT/EQUIPMENT PREPARATION

Once the patient is ready, prepare the necessary examination instrument and equipment for use. You must maintain an aseptic technique in the Dental Treatment Room (DTR). Throughout the procedure, take care to prevent sterile instruments from being contaminated. Place the sterile instrument pack on the bracket table. Open the oral exam instrument pack, leaving the items on the sterile wrapping paper as shown in figure 2-2. Some commands use peel packs for the exam pack. In this case, the instruments should be placed on bracket table covers (paper sheets). At this point you should have completed all of the preparation procedures. After you have double checked the area ensuring everything is ready, notify the dentist that the patient is ready.

## EXAMINATION DUTIES

During the dental exam, you are responsible for assisting the dentist and recording information on dental treatment forms and records.

Some of the typical tasks you may perform when assisting the dentist include:

- Taking the patient's vital signs (blood pressure and pulse). This is discussed in chapter 9 of this volume, "Dental Treatment Room Emergencies."
- Drying the teeth with the air syringe and directing the air on the mouth mirror to prevent fogging.

You may be required to record treatment information on the following dental treatment records and forms.

- Dental Treatment Record, NAVMED 6150/21-30
- Dental Health Questionnaire, NAVMED 6600/3
- Current Status Form
- Dental Examination Form, EZ603 and EZ603A
- Report of Medical Examination, SF 88
- Consultation Sheet, SF 513

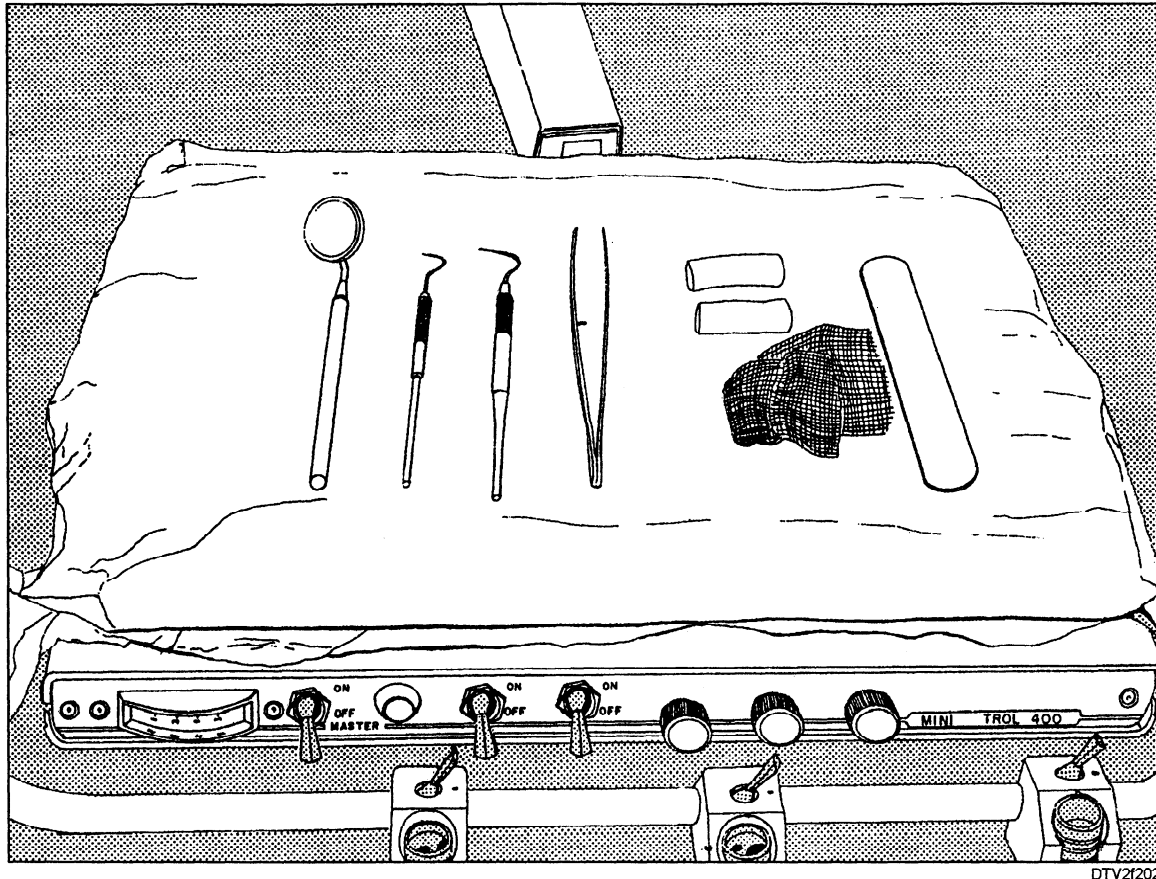


Figure 2-2.—Examination instrument setup.

DTV2f202

## EXAMINATION TYPES

The four different types of dental examinations are discussed in the paragraphs that follow. To ensure uniformity in nomenclature and definitions, dental examinations are classified by type.

### TYPE 1, COMPREHENSIVE EXAMINATION

This is the ideal examination, for it is the most extensive dental examination. The dentist will perform a comprehensive hard and soft tissue examination that includes: oral cancer screening examination; mouth-mirror, explorer, and periodontal probe examination; adequate natural or artificial illumination; panoramic or full-mouth periapical, and posterior bitewing radiographs; blood pressure recording; and when indicated, percussive, thermal and electrical test, transillumination, and study models. Included are those lengthy clinical evaluations required to establish a complex clinical diagnosis and the formulation of a total treatment plan. For example: treatment planning for full-mouth reconstruction; determination of the etiology or differential diagnosis of a patient's chief

complaint, such as temporomandibular joint (TMJ) dysfunction and associated oral facial pain; or lengthy history taking relative to determining a diagnosis, or in-processing examination for officer candidates.

### TYPE 2, ORAL EXAMINATION

Comprehensive hard and soft tissue examination, which will include: oral cancer screening examination; mouth-mirror, explorer, and periodontal probe examination; adequate natural or artificial illumination; appropriate panoramic or intraoral radiographs as indicated by the clinical examination; and blood pressure recording. An appropriate treatment plan will be recorded. This type is the routine examination, which is normally done only one time per treatment regimen per patient, unless circumstances warrant another complete examination.

### TYPE 3, OTHER EXAMINATION

This examination consists of diagnostic procedures as appropriate for: consultation between staff or staff residents; observation where no formal consult is prepared; certain categories of physical

examinations; and emergency oral examinations for evaluation of pain, infection, trauma, or defective restorations.

#### **TYPE 4, SCREENING EVALUATION**

This type of examination consists of a mouth-mirror and explorer or tongue depressor examination with whatever illumination is available. This category includes the initial dental processing of recruits without necessarily being examined by a dentist or other screening procedures. A qualified dental assistant or dental hygienist may perform a type 4 examination.

#### **OCCASIONS FOR DENTAL EXAMINATIONS**

Dental examinations are performed on various occasions. The type of the examination performed will depend on what the patient needing an examination requires (i.e., retirement, annual, etc.).

#### **ACCESSION**

All Navy and Marine Corps personnel who enter the military service will have a dental record established with an accession examination and radiographs.

#### **PERIODIC DENTAL EXAMINATIONS**

Dental examinations of all active duty Navy and Marine Corps personnel must be conducted annually and on other appropriate occasions to establish the need for dental treatment and verify dental records. Periodic dental examinations assess the readiness status of active duty Navy personnel. The annual examination should normally be a type 2 examination.

#### **SUITABILITY FOR OVERSEAS ASSIGNMENT (OVERSEAS SCREENING)**

The procedures for the medical and dental evaluation of Navy and Marine Corps members and their accompanying family members, who are undergoing suitability processing for overseas assignment, are provided in NAVMEDCOMINST 1300.1.

Based upon the findings of the dental examination, a dental officer recommends suitability or unsuitability of a member and family members for overseas assignment. This is documented on a

NAVMED 1300/1, Medical and Dental Overseas Screening Review for Active Duty or Dependent. The examining dentist will complete Part II: Dental Screening (fig. 2-3) on the NAVMED 1300/1.

The ultimate responsibility rests with the member's commanding officer to approve or disapprove the member or family members for overseas assignment.

#### **PERIODICITY OF MEDICAL EXAMINATIONS (PHYSICALS)**

As a part of each member's medical physical examination, a dentist must examine the member and record the results on the Report of Medical Examination, SF-88 (covered later in this chapter). Entries are also made on the member's EZ603, and filed in the NAVMED 6150/21-30.

All active duty members and reservists will have medical examinations completed as follows:

- Upon entry to enlisted or commissioned active duty
- At intervals of 5 years through age 50
- At intervals of 2 years through age 60
- Annually after age 60

#### **SEPARATIONS, RETIREMENTS AND SPECIAL PROGRAMS**

Dental examinations are required for personnel who separate from the Naval Service, retire, or apply for special programs. The *Manual of the Medical Department*, NAVMED P-117, chapters 6 and 15, outlines procedures for these examinations.

#### **DENTAL CLASSIFICATIONS**

The Navy Dental Corps has a uniform system for recording the results of a dental examination. It is a classification system that lets the provider determine the dental status of each individual and establishes priorities of treatment. Numbers are used to record one of four possible dental classifications. Each classification is carefully determined using prescribed criteria and is accurately recorded. The following is a description of each classification.



**PART II: DENTAL SCREENING.** The purpose of the dental screening examination and dental record review is to determine if the dental health of the examinee is suitable for assignment to overseas areas where access to dental care may be limited or where the capability for dental care within a military facility does not exist. Complete SF 603, Dental Health Record, and NAVMED 6600/3, Dental Health Questionnaire, and attach to NAVMED 1300/1

1. Does the examinee have any acute or chronic dental conditions (including active orthodontics) requiring routine or continuing access to care or access to specialized dental care?

- ( ) NO - Proceed to question 4.
- ( ) YES - Proceed to next question

2. List all acute or chronic dental conditions or illnesses as noted in the (a) dental record review, (b) dental examination, and (c) interview with the examinee:

3. If examinee's condition(s) will make him/her unsuitable for this assignment and can be corrected, do not complete this form until treatment is completed and/or examinee is found suitable/unsuitable. Arrange for treatment at your clinic or elsewhere as appropriate. Can treatment be completed prior to transfer date?

- ( ) NO - Provide servicemember's command with estimated date of completion of treatment and overseas screening.
- ( ) YES - Schedule treatment and completion of screening.

4. What is your recommendation on examinee's suitability for this assignment?

Suitable ( ) Unsuitable ( )

Military DTF: Examining Dentist's Signature	or	Civilian facility: Examining Dentist's Signature
Name / Rank or Grade (Print)		Dentist Name (Print)
SSN		Dentist's Address
DTF or Duty Station		City / State
Phone No.	Date	Phone No.                      Date

3.

Figure 2-3.—NAVMED 1300/1, Part II: Dental Screening.

## CLASS 1

This classification is for patients who do not require dental treatment or reevaluation within 12 months. Class 1 patients must meet these conditions:

- No dental caries or defective restorations.
- Arrested caries for which treatment is not indicated.
- Healthy periodontium, no bleeding on probing; oral prophylaxis not indicated.
- Replacement of missing teeth not indicated.
- Unerupted, partially erupted, or malposed teeth that are without historical, clinical, or radiographic signs or symptoms of pathosis and are not recommended for prophylactic (preventive) removal.
- Absence of temporomandibular disorders; stable occlusion.

## CLASS 2

Class 2 is the classification for patients who have oral conditions that the examining dentist feels if not treated or followed up, have the potential but are not expected to result in dental emergencies within 12 months.

## CLASS 3

Class 3 is the classification for patients who have oral conditions that the examining dentist expects will result in dental emergencies within 12 months if not treated. Patients should be placed in class 3 when there are questions in determining classification between class 2 and class 3.

## CLASS 4

Class 4 is the classification for patients who require a dental examination. This includes patients who require annual or other required dental examinations and patients whose dental classifications are unknown.

### DESIGNATIONS, CHARTING, AND ABBREVIATIONS

The designations and abbreviations are to be used when making entries in a patient's EZ603 or EZ603A (dental continuation sheet). The names of permanent and deciduous teeth and numbers that correspond with

them have been discussed in *Dental Technician*, Volume 1, chapter 4.

## TOOTH SURFACES

The following designation of tooth surfaces are used to record pathologic conditions and subsequent restoration of teeth:

<u>Surface</u>	<u>Designation</u>
Facial (labial and buccal)	F
Lingual	L
Occlusal	O
Mesial	M
Distal	D
Incisal	I

Combinations of the designations must be used to identify and locate caries, and to record treatment plans, operations, or restorations in the teeth involved; for example, 8-MID would refer to the mesial, incisal, and distal aspects of a right maxillary central incisor; 22-DF, the distal and facial aspects of a left mandibular cuspid; and 30-MODF, the mesial, occlusal, distal, and facial aspects of a right mandibular first molar.

## GENERAL CHARTING

As a Dental Technician, a large portion of your time during an examination involves recording existing restorations and current diseases and abnormalities in the patient's dental records. You must fully understand how and where to record this information. Dental chart markings have been standardized so the original dental condition, diseases and abnormalities (treatment needed), and treatments completed may be identified. This assists in efficient continuity of treatment and may establish identification in certain circumstances.

## STANDARD ABBREVIATIONS AND ACRONYMS

The use of standard abbreviations and acronyms is not mandatory, but it is desirable for expediency. Dental forms used to record dental treatment have limited amounts of space to write on. Use only abbreviations and acronyms that will not be misinterpreted. When you record treatment, ensure you correctly spell all terms. Well known medical and scientific signs and symbols such as: Rx (prescription),

WNL (within normal limits), BP (blood pressure) and O<sup>2</sup> (oxygen) may be used in recording dental treatment. The following abbreviations and acronyms are authorized:

Acute Necrotizing Ulcerative Gingivitis	ANUG
Assessment	A
All caries not removed	ACNR
Amalgam	Am
Anesthetic (thesia)	Anes
Bite-wing radiographs	BWX
Camphorated paramonochlorophenol	CMCP
Chief complaint	c c
Communication	Comm
Complete denture	CD
Copal varnish	Cop
Crown	Cr
Curettage	Cur
Drain	Drn
Electric pulp test	EPT
Endontics	Endo
Equilibrate (ation)	Equil
Eugenol	Eug
Examination	Exam
Extraction (ed)	Ext
Fixed partial denture (bridge)	FPD
Fluoride	FI
Fracture	Fx
Gutta percha	GP
Health questionnaire reviewed	HQR
History	Hx
Mandibular	Man
Maxillary	Max
No significant finds	NSF
Objective	O
Operative	Oper
Oral cancer screening examination	OCSE
Oral diagnosis	OD

Oral Health Counseling	OHC
Oral surgery	O S
Panoramic radiograph	Pano
Patient	P t
Patient Informed of Examination Findings and Treatment Plan	PTINF
Periapical	PA
Pericoronitis	PCOR
Periodontal Screening and Record	PSR
Periodontics	Perio
Plan	P
Plaque Control Instructions	PCI
Porcelain	Porc
Post Operative Treatment	POT
Preparation	Prep
Preventive dentistry	PD
Prophylaxi	Pro
Prosthodontics	Pros
Removal partial denture	RPD
Restoration(s)	Rest
Return to clinic	RTC
Subjective	S
Scaled (ing)	S
Surgical (ery)	Scl
Suture (s) (d)	su
Temporary	Temp
Topical	Top
Treatment (ed)	TX
Zinc oxide and Eugenol	ZOE

### RECORDING DENTAL TREATMENT

When you are involved in recording dental treatment from an examination or charting treatment that has been completed, certain markings are charted on the examination form you are using. The five forms that will be discussed in this section are the Forensic Examination, located on the inside back cover of the NAVMED 6150/21-30, and Current Status Form located on the inside back cover section of NAVMED

6150/21-30 underneath the record identifier for Personnel Reliability Program (if applicable). The last three forms are the Dental Exam Form (EZ603), Dental Continuation Form (EZ603A), and the Report of Medical Examination (SF 88).

**NOTE**

Please be aware that some of the dental forms used to record dental treatment will be changing in the future. The Bureau of Medicine and Surgery (BUMED) is now using the BUMED Approved EZ603 (trial), EZ603A, Current Status Form and Forensic Examination Form to record dental examinations and

treatment. These four forms replace the old Standard Form 603 and 603A (dental continuation). An example of the old SF603 is shown in figures 2-4 and 2-5. As with any Navy form or instruction that becomes obsolete, always use the current one available.

**FORENSIC EXAMINATION**

This form (fig. 2-6) replaces box 4 on the old SF 603. It is intended that this form be completed only once (usually at accession) during the member's military career. If a replacement record is made, a new forensic exam will be completed. Next we will discuss how to complete the forensic exam form.

HEALTH RECORD				DENTAL			
GENERAL SERVICES ADMINISTRATION INTERAGENCY COMMITTEE ON MEDICAL RECORDS FPMR 101-11, 806-8-OCTOBER 1975							
SECTION I. DENTAL EXAMINATION				REMARKS			
1. PURPOSE OF EXAMINATION				2. TYPE OF EXAM		3. DENTAL CLASSIFICATION	
<input checked="" type="checkbox"/> INITIAL	<input type="checkbox"/> SEPARATION	<input type="checkbox"/> OTHER (Specify)		<input checked="" type="checkbox"/> 1	<input type="checkbox"/> 2	<input type="checkbox"/> 3	<input type="checkbox"/> 4
4. MISSING TEETH AND EXISTING RESTORATIONS				Chrome alloy Max. RPD with acrylic teeth replacing 3, 4, 14			
5. DISEASES ABNORMALITIES, AND X-RAYS				PLACE OF EXAMINATION: NDC, SAN DIEGO, CA DATE: 20 Jan 88 SIGNATURE OF DENTIST COMPLETING THIS SECTION: Paul T. Boate CAPT, DC, USN			
				A. CALCULUS SLIGHT <input checked="" type="checkbox"/> MODERATE <input type="checkbox"/> HEAVY <input type="checkbox"/> B. PERIODONTITIS <input checked="" type="checkbox"/> LOCAL <input type="checkbox"/> GENERAL <input type="checkbox"/> INCIPIENT <input checked="" type="checkbox"/> MODERATE <input type="checkbox"/> SEVERE C. STOMATITIS (Specify) GINGIVITIS <input type="checkbox"/> VINCENT'S <input type="checkbox"/> D. DENTURES NEEDED (Include dentures needed after indicated extractions) FULL <input type="checkbox"/> PARTIAL <input type="checkbox"/> U <input type="checkbox"/> L <input type="checkbox"/> U <input type="checkbox"/> L ABNORMALITIES OF OCCLUSION—REMARKS 2 mm Diastema between 8 and 9 15 and 16 tilted mesially so only distal cusps in occlusion			
E. INDICATE X-RAYS USED IN THIS EXAMINATION				SIGNATURE OF DENTIST COMPLETING THIS SECTION			
<input type="checkbox"/> FULL MOUTH PERIAPICAL	<input checked="" type="checkbox"/> POSTERIOR BITE-WINGS	<input checked="" type="checkbox"/> OTHER (Specify) PANO		Paul T. Boate CAPT, DC, USN			
DATE: 20 Jan 88	PLACE OF EXAMINATION: NDC, SAN DIEGO, CA						
SECTION II. PATIENT DATA							
6. SEX: M	7. RACE: CAU	8. GRADE, RATING OR POSITION: SR	9. ORGANIZATION UNIT:	10. COMPONENT OR BRANCH:	11. SERVICE, DEPT. OR AGENCY: USN		
12. PATIENT'S LAST NAME—FIRST NAME—MIDDLE NAME: DOE, John MNM				13. DATE OF BIRTH (DAY-MONTH-YEAR): 1 Aug 66	14. IDENTIFICATION NO.: 111-11-1111		
NSN 7540-00-634-4179							
DENTAL Standard Form 608 603-103							

DTV2f204

Figure 2-4.—Sample of old SF 603, front side.

SECTION III. ATTENDANCE RECORD				
15. RESTORATIONS AND TREATMENTS (Completed during service)			16. SUBSEQUENT DISEASES AND ABNORMALITIES	
REMARKS			REMARKS	
17. SERVICES RENDERED				
DATE	DIAGNOSIS—TREATMENT	CLASS	OPERATOR AND DENTAL FACILITY	INITIALS
20Jan88	S: Inprocessing - no complaints, no pain O: T1 Exam., BWX, Pano., BP 110/75, OCSE type I), HQR dtd 20Jan88 (WNL) A: See section I, box 5 P: 1. P.D. - Spl., Pro., top, fluoride, PCI 2. O.S. consult - Ext. #32, eval. #1 3. OPER - refer to section I, box 5 (Gen Dent.) PTINF	(WNL)	(WNL), PERIO Exam. (case)	
			<i>J. Frost</i> CAPT, DC, USN, NDC SD	3
25Jan88	S: O.S. consult - no complaints, no pain O: T3 Exam., review Pano., BP 120/80, HQR dtd 20Jan88 (WNL) A: Healthy 21 year old recruit in no apparent distress #32, 1 - soft tissue impaction, no oral communication, asymptomatic P: O.S. consult at first permanent duty station, eval. #1, 32 PTINF Pt. understands the possibility of Ext #32			
			<i>V. Distal</i> CDR, DC, USN, NDC SD	3
2Mar88	S: Pain and swelling of lower right jaw for past 2 days O: T3 Exam., PA radiograph #32, review Pano., BP 120/80, HQR dtd 20Jan88 (WNL), oral temp. 100.2°F, edematous and macerated tissue #32 area mesioangular impaction #32 A: #32 - soft tissue impaction, symptomatic P: Ext. #32, local anes., oral antibiotic therapy x 10 days PTINF Importance of rest, diet, and fluids explained to patient			
			<i>F. Brink</i> LT, DC, USNR, USS ROCK	3

DOE, John NMN  
 PATIENTS: LAST NAME - FIRST NAME - MIDDLE NAME

U. S. G. P. O. 1903 - 301 - 526/019C

DTV2f205

Figure 2-5.—Sample of old SF 603, back side.

**Charting/Markings**

The teeth are separated on the exam form to facilitate illustrating supernumerary teeth, mixed dentition, and interproximal restorations. If a restoration exists interproximally with no occlusal component, use the space to draw the restoration. When indicating fixed partial dentures, ignore the spaces. Draw the prosthesis and indicate the materials and teeth involved in the Remarks section as usual.

Use the following symbols and notations to complete the top section of the Forensic Examination

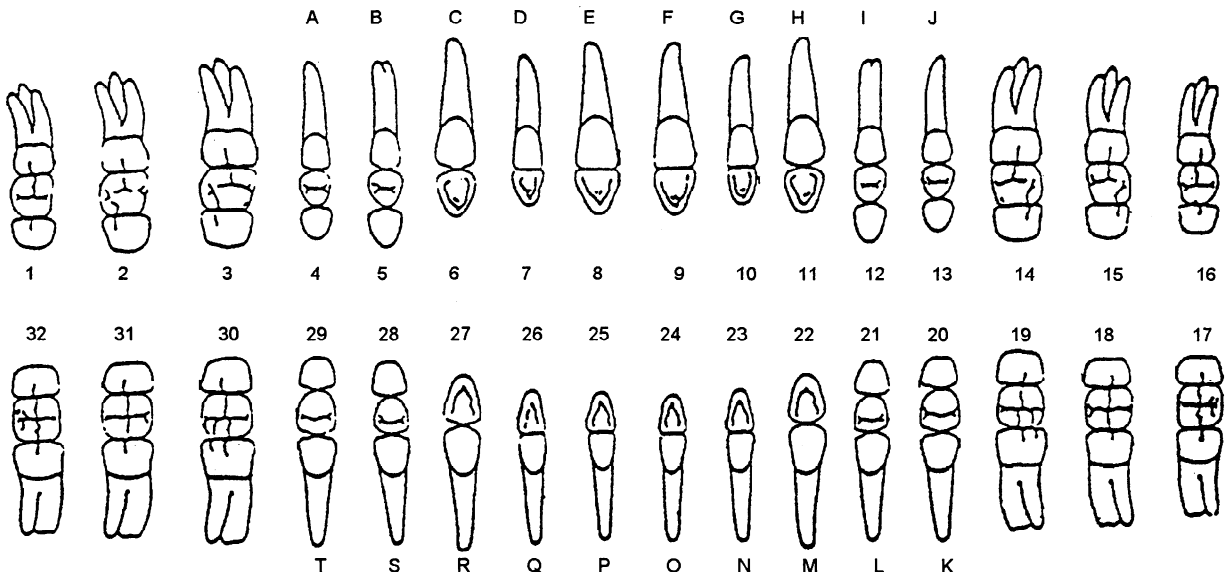
form to record existing restorations, existing teeth, missing teeth, prosthetic appliances, and variation of normal conditions (non-disease). Use black ink with the following symbols and notations. MANMED chapter 6, also gives details on these symbols and notations. **Note:** These same symbols are used for Box 2 on the Current Status Form.

**MISSING TEETH.**—Draw a large "X" on the root or roots of teeth not visible in the mouth. Figure 2-7 illustrates teeth #6, #11, and #12 as missing or extracted teeth.

**EDENTULOUS ARCH.**—Make crossing lines each running from the uppermost aspect of one third

# FORENSIC EXAMINATION

EXISTING RESTORATIONS, EXISTING TEETH, MISSING TEETH, PROSTHETIC APPLIANCES, AND VARIATION OF NORMAL CONDITIONS (NON-DISEASE) AS OF \_\_\_\_\_ (Date)



REMARKS

\_\_\_\_\_  
 \_\_\_\_\_  
 \_\_\_\_\_

OCCLUSION

ANGLE'S CLASS \_\_\_\_\_  
 OVERJET \_\_\_\_\_  
 OVERBITE \_\_\_\_\_  
 CROSSBITE \_\_\_\_\_  
 REMARKS \_\_\_\_\_

SOFT TISSUE

LEUKODEMA \_\_\_\_\_  
 MELANOPLAKIA \_\_\_\_\_  
 AMALGAM TATTOO \_\_\_\_\_  
 OTHER: \_\_\_\_\_

HARD TISSUE

INTRINSIC STAINING (TETRACYCLINE ) \_\_\_\_\_  
 TORI \_\_\_\_\_  
 ROTATED TEETH \_\_\_\_\_  
 MALPOSED TEETH \_\_\_\_\_  
 OTHER: \_\_\_\_\_

Examining Dentist's Name Stamp

Examining Dentist's Signature

Patient's Last Name                      First Name                      MI                      Patient's Social Security Number

Figure 2-6.—Forensic Examination Form.

molar to the lowermost aspect of the third molar on the opposite side. Figure 2-7 illustrates an edentulous mandibular arch.

**EDENTULOUS MOUTH.**—Inscribe crossing lines (fig. 2-8) one extending from the maxillary right third molar to the mandibular left third molar and the other line from the maxillary left third molar to the mandibular right third molar.

**PARTIALLY ERUPTED TOOTH.**—In the diagram of the tooth, draw an arcing line through the

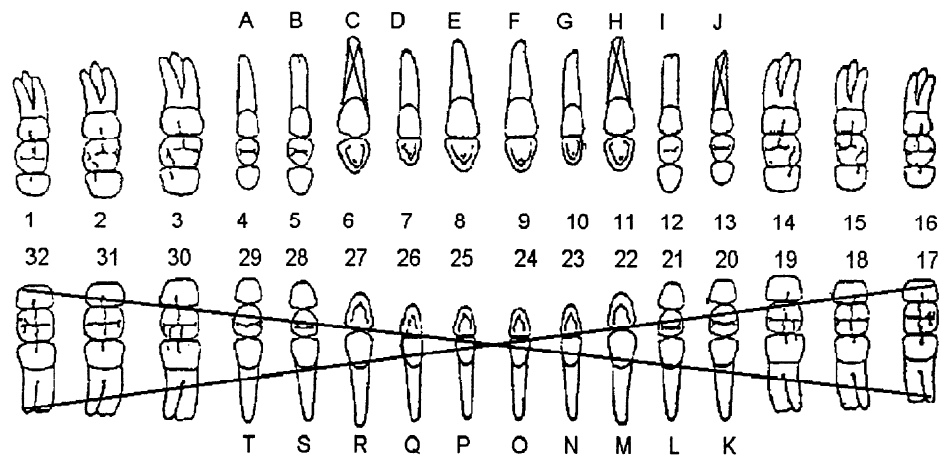
long axis. Figure 2-9 illustrates teeth #17 and #32 as partially erupted.

**AMALGAM RESTORATIONS.**—In the diagram of the tooth, draw an outline of the restoration showing size, location, and shape, and block in solidly. The following are different types of amalgam restorations:

- Occlusal (O): Chart along the grooves on the occlusal surface (fig. 2-10, teeth #1, #2, and #5).

## FORENSIC EXAMINATION

Existing restoration, existing teeth, missing teeth, prosthetic appliances, and variation of normal conditions (nondisease) as of \_\_\_\_\_

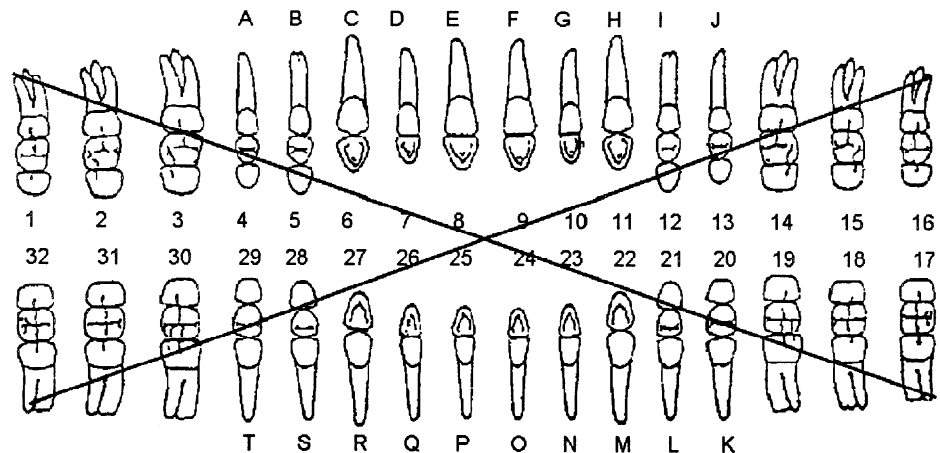


DTV2f207

Figure 2-7.—Missing teeth and edentulous mandibular arch.

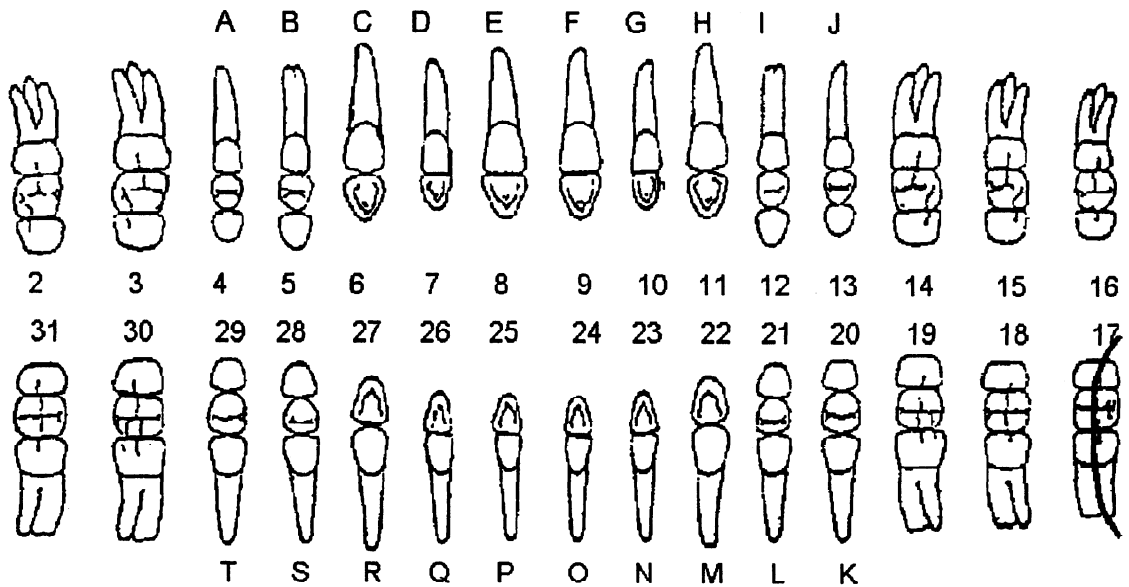
## FORENSIC EXAMINATION

Existing restoration, existing teeth, missing teeth, prosthetic appliances, and variation of normal conditions (nondisease) as of \_\_\_\_\_



DTV2f208

Figure 2-8.—Edentulous mouth.

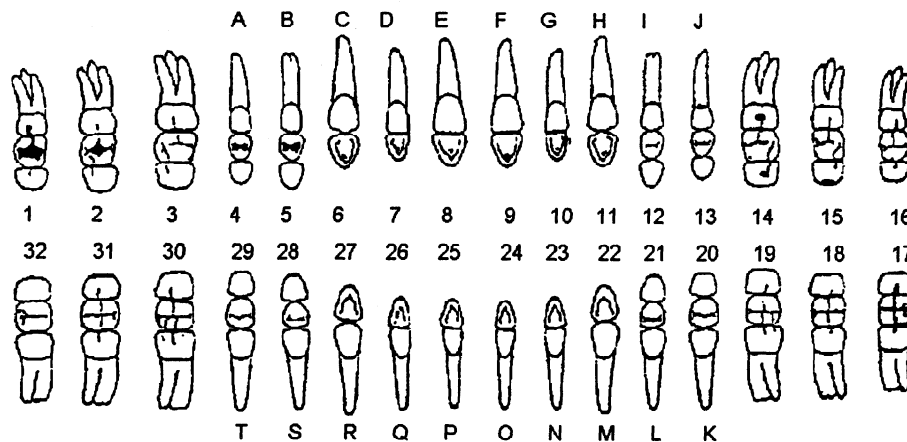


DTV2f209

Figure 2-9.—Partially erupted teeth.

## FORENSIC EXAMINATION

Existing restoration, existing teeth, missing teeth, prosthetic appliances, and variation of normal conditions (nondisease) as of \_\_\_\_\_



DTV2f210

Figure 2-10.—Single surface amalgam restorations.

- Double occlusal (O) (O): This restoration is often referred to as "snake eyes." Chart along the two separate grooves on the occlusal surface (fig. 2-10, tooth #4).

- Facial (F): Chart along the facial groove, in the facial pit (fig. 2-10, tooth #14), or at the gingival margin of the facial surface (fig. 2-10, tooth #13).

- Lingual (L): Chart these along the lingual groove, in the lingual pit (fig. 2-10, tooth #14), or at the gingival margin on the lingual surface (fig. 2-10, tooth

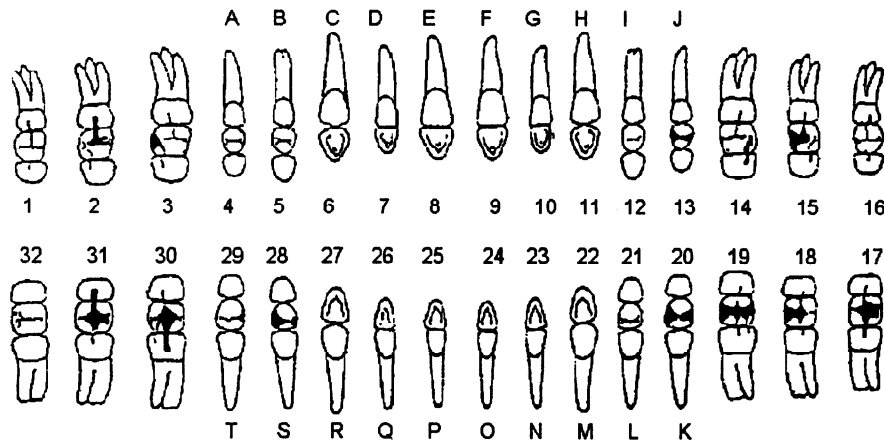
#15). On anterior teeth, chart these restorations in the lingual pit (fig. 2-10, tooth #9).

- Mesial-occlusal (MO): Chart by beginning at the mesial surface and following the grooves on the occlusal surface to the central pit or groove (fig. 2-11, tooth #18). There can be two amalgam restorations (e.g., an MO and a DO) on the same tooth. In this case the restoration will reach into the central groove, but not include the central pit (fig. 2-11, tooth #20). Rarely will a restoration cross the oblique ridge (fig. 2-11, tooth #2, #3, #14, and #15).



## FORENSIC EXAMINATION

Existing restoration, existing teeth, missing teeth, prosthetic appliances, and variation of normal conditions (nondisease) as of \_\_\_\_\_



DTV2211

**Figure 2-11.—Two and three surface amalgam restorations.**

- **Distal-occlusal (DO):** Chart by beginning at the distal surface, and follow the grooves on the occlusal surface to the central pit or groove (fig. 2-11, tooth #28).

- **Occlusal-facial (OF):** Chart starting at the central groove on the occlusal surface and down the facial groove on the facial surface. Occlusal-facial restorations are usually placed only on molars. On some molars, all of the occlusal pits will be included in the restoration (fig. 2-11, tooth #17).

- **Occlusal-lingual (OL):** Chart starting at the central groove on the occlusal surface and down the lingual groove on the lingual surface (fig. 2-11, tooth #31). Like (OF) amalgams, (OL) amalgams are usually placed only on molars.

- **Mesial-occlusal-distal (MOD):** Chart starting at the mesial surface and follow the grooves on the occlusal surfaces to the distal surface (fig. 2-11, tooth #13 and #19). You can also think of a (MOD) amalgam restoration as an (MO) and a (DO) amalgam restoration joined together through the central groove on the occlusal surface.

- **Mesial-occlusal-distal-facial (MODF):** Chart the same way as a (MOD) amalgam restoration, but include the facial surface. The facial surface may be charted in several ways. It may be charted in the facial groove (fig. 2-12, tooth #3), or it may be wrapped around the mesial or distal facial surface (fig. 2-12, tooth #14). The (MODF) amalgam may include a part of the facial surface (fig. 2-12, tooth #1), or it may include the entire facial surface (fig. 2-12, tooth #15).

Some (MODFs) include the coronal third of the facial surface (fig. 2-12, tooth #16).

- **Mesial-occlusal-distal-lingual (MODL):** Chart the same way as a (MOD) amalgam restoration, but include the lingual surface. The lingual aspect may be charted in the lingual groove (fig. 2-12, tooth #18) or it may wrap around the mesial and distal surfaces in the same manner as that discussed for the (MODF). Figure 2-12, tooth #30 and tooth #31, illustrates examples of the (MODL) restorations that include various portions of the lingual surfaces.

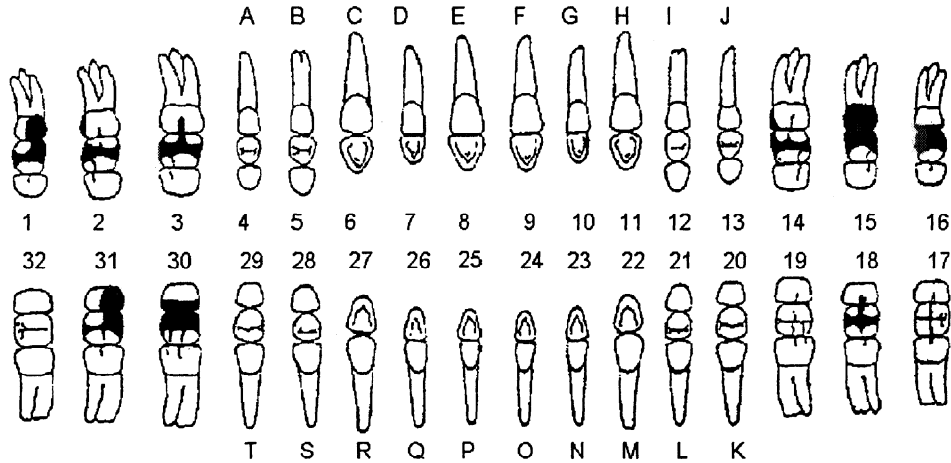
- **Mesial-occlusal-distal-facial-lingual (MODFL):** Chart by combining the (MODF) and (MODL) restorations. These restorations may include carious portions of the facial and lingual surfaces. Figure 2-13 illustrates the different types of (MODFL) restorations.

**NONMETALLIC PERMANENT RESTORATIONS.**—Nonmetallic Permanent Restorations include filled and unfilled resins, glass ionomer cement and pit and fissure sealants. In the diagram of the tooth, draw an outline of the restorations showing size, location, and shape. Do not block in. The following paragraphs explain how to chart nonmetallic restorations.

- **Mesial (M) and distal (D):** Chart these single surfaces on the mesial or the distal side of the facial surface. Figure 2-14, illustrates a mesial restoration (M) on tooth #8, and a distal restoration (D) on tooth #9.

## FORENSIC EXAMINATION

Existing restoration, existing teeth, missing teeth, prosthetic appliances, and variation of normal conditions (nondisease) as of \_\_\_\_\_

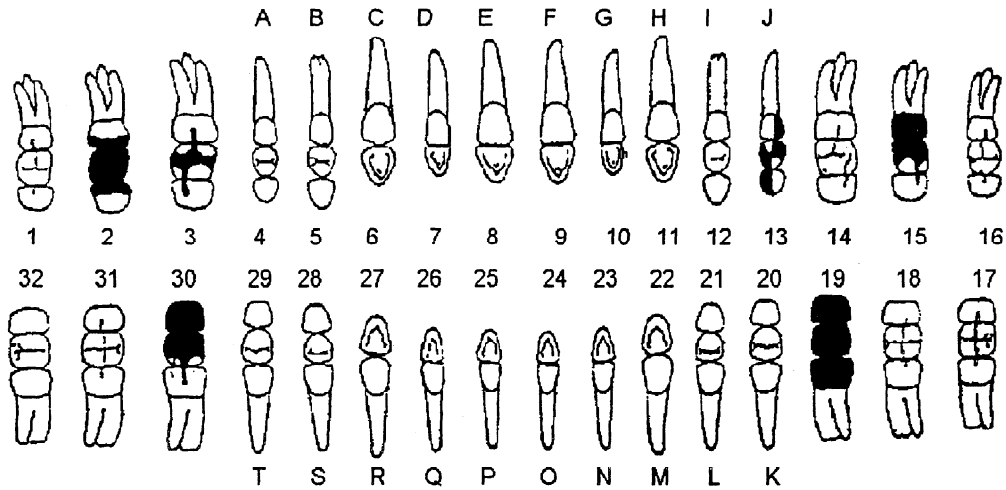


DTV2f212

Figure 2-12.—Four surface amalgam restorations.

## FORENSIC EXAMINATION

Existing restoration, existing teeth, missing teeth, prosthetic appliances, and variation of normal conditions (nondisease) as of \_\_\_\_\_



DTV2f213

Figure 2-13.—Five surface amalgam restorations.

- Incisal (I): These restorations include the incisal surface and/or one or more of the other surfaces (MI or DI). Tooth #10 in fig. 2-14, shows an (MI) restoration; tooth #7 in the same figure shows a (DI) restoration.

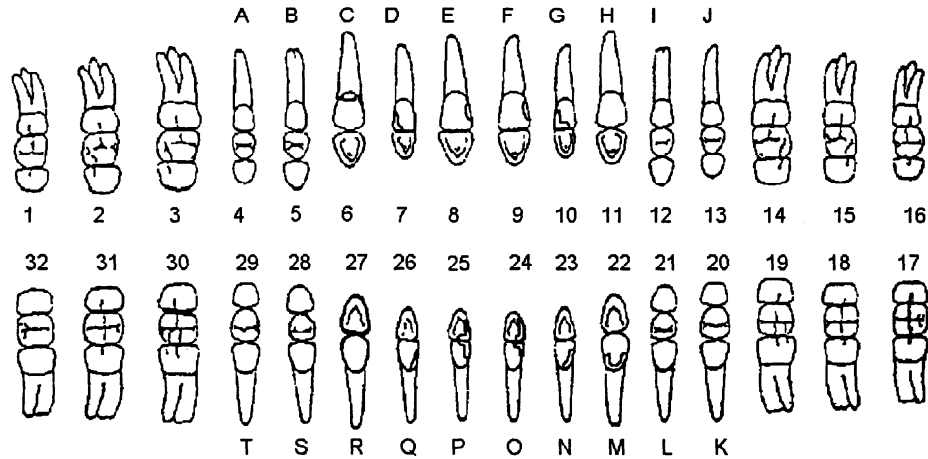
- Facial (F): Chart along the gingival margin of the facial surface unless otherwise instructed by the dentist. Tooth #6 in fig. 2-14 shows a facial (F) restoration.

- Lingual (L) on anterior teeth: You will usually chart them in the lingual pit (fig. 2-14, tooth #11) or at the gingival margin line of the tooth.

- Nonmetallic restorations with two or more surfaces: Chart these restorations as shown in the mandibular arch in figure 2-14. Tooth #26 shows a mesial-facial (MF) restoration; tooth #23, a distal-facial (DF) restoration; tooth #22, a mesial-facial-distal

## FORENSIC EXAMINATION

Existing restoration, existing teeth, missing teeth, prosthetic appliances, and variation of normal conditions (nondisease) as of \_\_\_\_\_



DTV21214

Figure 2-14.—Nonmetallic Restorations.

(MFD) restoration; tooth #25, a mesial-incisal-lingual (MIL) restoration; and tooth #24, a distal-incisal-lingual (DIL) restoration.

- Porcelain, Acrylic Resin, Glass Ionomer, Artificial Crowns, Facings, and Pontics: Chart these nonmetallic restorations by outlining all aspects of the crown or facing as shown on tooth #27 in figure 2-14. In the "Remarks" section, indicate the material used.

**GOLD RESTORATIONS.**—Outline and inscribe **horizontal** lines within the outline. If made of an alloy other than gold (chrome), the same charting

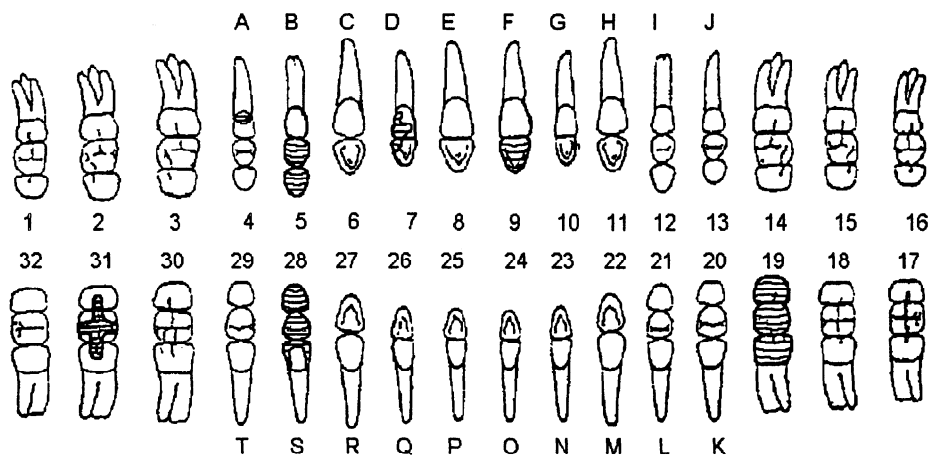
applies. Indicate in "Remarks" section on the Forensic Exam form the type crown and metal used.

Figure 2-15 shows examples of gold restorations. Tooth #4 has a facial (F) gold restoration, tooth #7 has a (DIL) gold restoration, and tooth #31 has a (MODFL) gold restoration.

To chart a full gold crown, outline each aspect of the crown, and then draw horizontal lines in the outlined area (fig. 2-15, tooth #19). Gold crowns may have a tooth-colored facial surface made of acrylic resin or porcelain call "facings." These facings are

## FORENSIC EXAMINATION

Existing restoration, existing teeth, missing teeth, prosthetic appliances, and variation of normal conditions (nondisease) as of \_\_\_\_\_



DTV21215

Figure 2-15.—Gold restorations and crowns.

inserted to give the restoration a natural appearance. Tooth #5 and tooth #9 in figure 2-15 show full gold crowns with nonmetallic facings. The nonmetallic facing is only outlined. Where a full crown is not needed, a three quarter gold crown may be used as shown on tooth #28 in fig. 2-15.

**COMBINATION RESTORATION.**—Outline the area showing the approximate overall size, location, and shape; partition at junction of materials used. Indicate each type of material used.

**REMOVABLE PARTIAL DENTURES (RPDs) AND COMPLETE DENTURES (CDs).**—Mark the missing teeth as previously described. Place a horizontal line between the outline of the teeth and the numerals designating teeth replaced by the CD or RPD (fig. 2-16). **Note:** On the Forensic Examination form in the "Remarks" section, describe the CD or RPD, indicating whether they are maxillary or mandibular and the type of restoration and material used. An example of this would be Man RPD (acrylic, gold, or chrome-cobalt).

**FIXED PARTIAL DENTURES (FPDs).**—Outline each aspect, including abutments and pontics.

Show partition at junction of materials and indicate each type of material used. Inscribe **diagonal** parallel lines to indicate gold. In the "Remarks" section, indicate each FPD type of material used (gold or chrome). Figure 2-17 illustrates gold or chrome fixed partial dentures and what they look like charted.

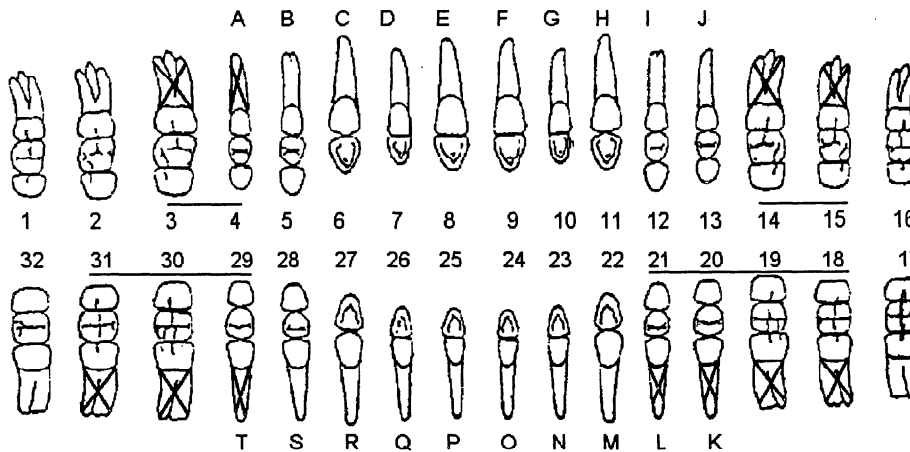
**POST CROWN.**—Chart the type of crown attached to the post. Outline each nonmetallic material and show restorative metallic materials. Outline approximate size and position of post or posts. In the "Remarks" section, indicate the material used.

**ROOT CANAL FILLING (RCF).**—Chart this specialized filling by drawing a line(s) in the area of the root(s) where the root canal(s) would normally be located. Teeth #3, #7, and #8 in figure 2-18 show examples of root canal fillings. **Note:** Root canal fillings will always be accompanied by a restoration, usually a crown, amalgam, or composite restoration.

**APICOECTOMY.**—This procedure involves the surgical removal of the apex of the tooth. Chart an apicoectomy by drawing a small triangle on the root of the tooth involved (fig. 2-18, tooth #11). Next chart the RCF on the root of the tooth beginning at the level of

## FORENSIC EXAMINATION

Existing restoration, existing teeth, missing teeth, prosthetic appliances, and variation of normal conditions (nondisease) as of \_\_\_\_\_



Remarks Chrome alloy Max. RPD  
with acrylic teeth replacing  
3, 4, 14, 15

Chrome alloy Man. RPD  
with acrylic teeth replacing  
18, 19, 20, 21, 29, 30, 31

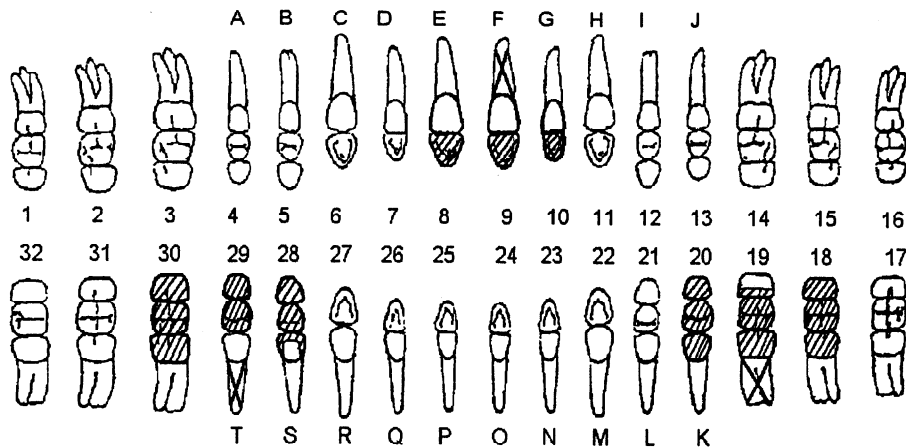
Soft Tissue \_\_\_\_\_  
Leukoedema \_\_\_\_\_  
Melanoplakia \_\_\_\_\_  
Amalgam Tattoo \_\_\_\_\_  
Other: \_\_\_\_\_

DTV2f216

Figure 2-16.—Removable partial dentures (RPDs).

## FORENSIC EXAMINATION

Existing restoration, existing teeth, missing teeth, prosthetic appliances, and  
variation of normal conditions (nondisease) as of \_\_\_\_\_

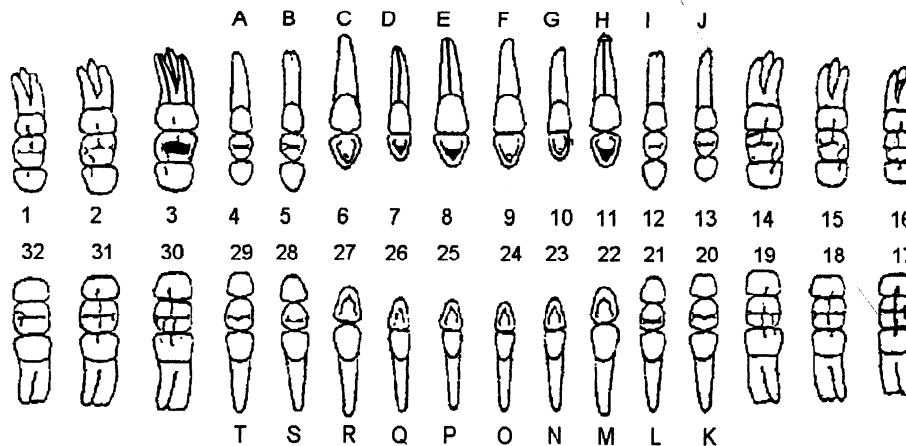


DTV2f217

Figure 2-17.—Gold or chrome fixed partial dentures (FPDs).

## FORENSIC EXAMINATION

Existing restoration, existing teeth, missing teeth, prosthetic appliances, and  
variation of normal conditions (nondisease) as of \_\_\_\_\_



DTV2f218

Figure 2-18.—Root canal fillings (RCFs) and apicoectomy.

the root amputation where the apicoectomy has been performed. The dentist will read the patient's radiograph to determine the level of the root amputation. Also note the (L) amalgam restoration on tooth #11.

**DECIDUOUS TEETH.**—Occasionally, a deciduous tooth will be retained in the adult mouth. Circle the appropriate alphabetical designation on the Forensic and Current Status forms if deciduous teeth are present. Figure 2-19 illustrates a deciduous tooth #11.

**SUPERNUMERARY TEETH.**—These are extra teeth other than the normal 32 teeth that are present in the mouth. To chart a supernumerary tooth, draw an outline of the tooth in its approximate location. Then insert an "S" in the proper location on the tooth number line as shown in figure 2-19.

**DRIFTED TEETH.**—To chart a drifted tooth, draw an arrow from the number of the drifted tooth as shown in figure 2-19 (teeth #19, #20, #32 and #31). The point of the arrow should indicate the approximate position to which the tooth has drifted. Drifting

# FORENSIC EXAMINATION

Existing restoration, existing teeth, missing teeth, prosthetic appliances, and variation of normal conditions (nondisease) as of \_\_\_\_\_

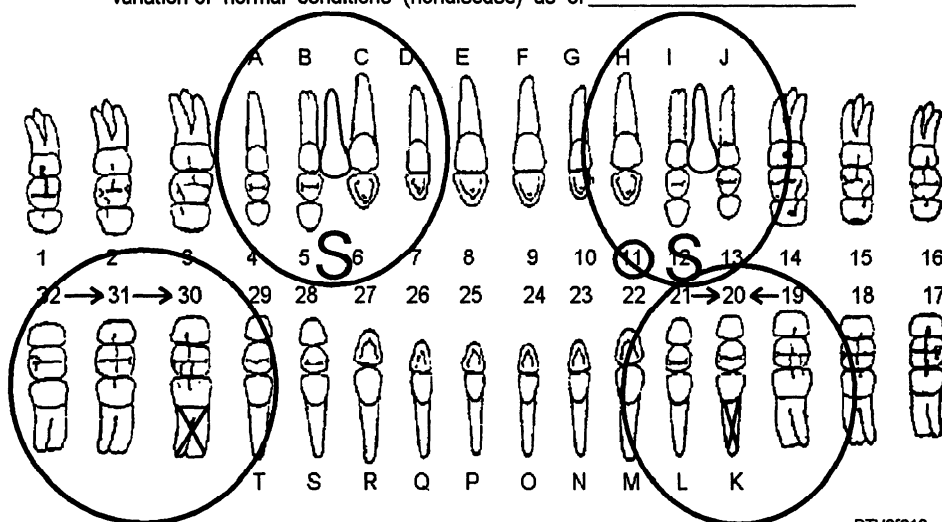


Figure 2-19.—Deciduous, supernumerary, and drifted teeth.

DTV2f219

usually occurs when teeth move toward the space of an extracted tooth.

**TEMPORARY RESTORATIONS.**—In the diagram of the tooth, draw an outline of the restoration showing size, location, and shape. If possible, describe the material in the remarks section.

## Remarks Section

Use this section to indicate the restorative materials and to differentiate between sealants, composites, and temporaries.

## Soft Tissue Remarks Section

This is just a partial list of some of the more common non-pathologic findings to facilitate charting. For each condition, indicate approximate size or extent and location. Leave blank if a condition does not exist.

## Occlusion Section

The examining dentist will tell you what Angle's class the patient has. The three classes are I, -11, or III. Each side of the patient's mouth may be different. Record the results in the space provided.

In the overjet and overbite section of occlusion, the dentist will let you know in millimeters the extent of the abnormality. Leave blank if normal.

In the crossbite section, the dentist will let you know the teeth involved to be written in the space provided.

The dentist will use the Remarks section of the occlusion section to record any other occlusal condition not listed above.

## Hard Tissue Remarks Section

This is just a partial list of some of the more common non-pathologic findings to facilitate charting. Leave section blank if the condition does not exist.

- Intrinsic staining—Indicate teeth involved. Check tetracycline, if appropriate.
- Tori—Indicate location and approximate size of projection.
- Rotated teeth—Indicate teeth involved and approximate number of degrees to the nearest 45 degrees.
- Malposed Teeth—Indicate teeth involved and whether facio- or linguo-version.
- Other—Use this space when noting other hard tissue conditions not listed above.

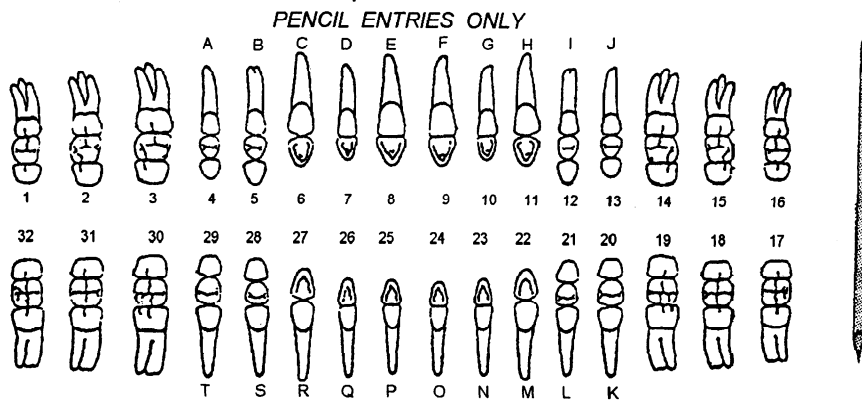
## Examining Dentist Name Stamp and Signature Sections

Use the examining dentist's name stamp to mark this section and ensure the signature line is signed.

# CURRENT STATUS

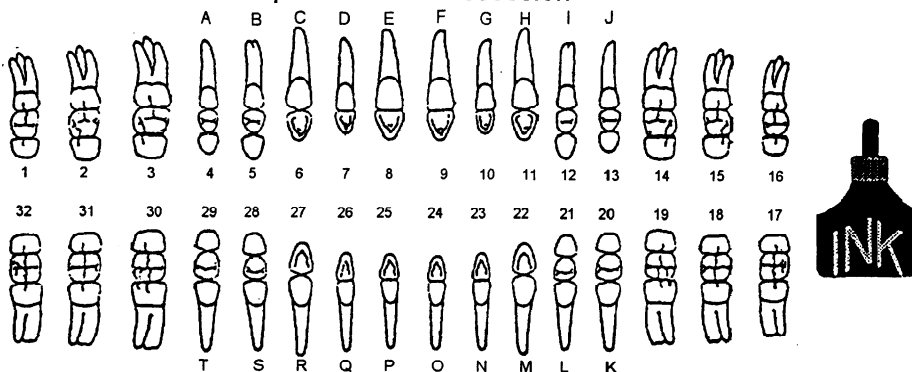
This form is intended to remain in effect for the member's entire service career. If a new form is required, place it over the old one, ensuring the medical alert box on the new form is correct  
 DATE FORM PLACED IN USE: \_\_\_\_\_ DATE FORM REPLACED: \_\_\_\_\_

## Box 1 Accession and Subsequent Diseased and Abnormalities



## Box 2 Missing Teeth at Time Of Accession and Treatments Completed After Accession

BLACK INK ENTRIES ONLY



**Box 3** If medical alert exists, write "ALERT" in large red letters, followed by short explanation.

**Box 4** Patient's Last Name                      First name                      MI                      Patient/Sponsor Social Security Number

DTV2f220

Figure 2-20.—Current Status Form.

### CURRENT STATUS FORM

This form (fig. 2-20) will last the entire service career of the patient. It is placed in the NAVMED 6150/21-30 in the same way the Personnel Reliability Program warning form is so that it may be folded up when not in use. If a new Current Status form is ever needed, the information from the previous forms **must be transferred** to the new form. The form is dated at the top when placed in use by the initial examiner and dated again when replaced by the final provider. The

Current Status form contains 4 boxes that explains the instructions for charting symbols used in boxes 1 and 2.

#### Box 1

Box 1, Accession and Subsequent Diseases and Abnormalities, replaces box 5 and box 9 (old box 16) on the SF 603/603A.

All carious lesions, indications for extraction, indications for root canal treatment, and periradicular lesions that the examining dentist recommends for the patient are drawn in **pencil** using the charting symbols

listed in this section. When the indicated treatment is completed, the pencil entry is erased.

### Charting Symbols (Box 1)

Use the following instructions for charting in the section, Accession and Subsequent Diseases and Abnormalities Section (Box 1). **Make sure you do not enter these symbols in Box 2, Missing Teeth at Time of Accession and Treatments Completed After Accession. Entering these symbols in the wrong area would prevent differentiation between the caries and the restorations.** Figure 2-21 illustrates charting symbols for Box 1.

**CARIES.**—On the diagram of the tooth affected, draw an outline of the carious portion, showing approximate size, location, and shape; block in solidly.

**DEFECTIVE RESTORATION.**—Outline the defective restoration, including the carious or otherwise defective area, and block in solidly.

**UNERUPTED TOOTH.**—Outline all aspects of the tooth with a single oval. This includes impacted teeth.

**INCLINATION (TILT) OF IMPACTED TEETH.**—Draw an arrow of the facial aspect of the

crown portion of the diagram that indicates the direction of the long axis of the tooth.

**EXTRACTION (REMOVAL) INDICATED.**—Draw two parallel vertical lines through all aspects of the tooth and roots involved. This applies also to unerupted teeth when removal is necessary.

**RETAINED ROOT.**—Draw a horizontal line on the root showing the level of retention. Place an "X" on the missing area. Draw two parallel lines in the direction of the long axis of the root through the part that is retained if extraction is indicated.

**FRACTURED TOOTH.**—Trace a jagged fracture line in the relative position on the crown or roots affected.

**PERIAPICAL RADIOLUCENCY.**—Outline approximate size, form, and location of the periapical radiolucencies, such as an abscess or cyst.

**FISTULA.**—Draw a straight line from the involved area, ending in a small circle in a position on the chart corresponding to the location of the tract orifice (opening) in the mouth.

**UNDERFILLED ROOT CANAL.**—Draw a vertical line from the crown toward the apex showing the extent of the filling.

**CURRENT STATUS**

This form is intended to remain in effect for the member's entire service career. If a new form is required, place it over the old one, ensuring the medical alert box on the new form is correct  
DATE FORM PLACED IN USE: \_\_\_\_\_ DATE FORM REPLACED: \_\_\_\_\_

---

Box 1 Accession and Subsequent Diseased and Abnormalities

*PENCIL ENTRIES ONLY*

#2 Meso-occlusal caries

#3 Distal caries

#4 Extraction indicated

#6 Mesial caries

#7 Periapical Abscess

#8 Fractured crown

#9 Fractured root-extraction indicated

#10 Abscess and fistula, underfilled root canal filling

#11 Resorbed root

#14 Defective restoration-outline area of restoration to be replaced and defective area

#16 Cyst involving 15 and 16

#17 Unerupted tooth. (If not visible in oral cavity, an "X" would appear on corresponding tooth on chart "Missing Teeth and Existing Restorations")

#20 Residual root requiring removal

#23-26 inclusive. Gingival crest-continuous line. Alveolar crest-continuous line.

#32 Impacted tooth with mesial inclination

DTV21221

Figure 2-21.—Charting symbols for Box 1, Accession and Subsequent Diseases and Abnormalities.



**RESORPTION OF ROOT.**—Draw an even line on the root showing the extent of resorption of the root.

**PERIODONTITIS AND ALVEOLAR RESORPTION.**—Indicate the extent of gingival recession by drawing a continuous line across the roots to approximate the extent of involvement. Draw another continuous line at the proper level across the roots of the teeth to indicate the extent of alveolar resorption. Base this finding on the dentist's clinical and radiographic findings.

### Box 2

Box 2, Missing Teeth at Time Of Accession and Treatments Completed After Accession replaces box 8 (old box 15) on the SF 603/603A and functions in the same way with the following exceptions:

- The information is cumulative on this form throughout the patient's military career.
- Missing teeth from the accession exam are also included in this box. By including this information, the SF 88, box 18 (old box 44) can be completed by looking at boxes 1 and 2 of the Current Status Form.

All extractions, restorations and root canal treatment completed during the patient's service career are entered using the symbols mentioned previously in this chapter under designations, abbreviations, and charting.

When indicating fixed partial dentures, ignore the spaces on the form in between the teeth and draw the prosthesis on each tooth as usual. Only use **black ink** to make entries in box 2.

### Charting Symbols (Box 2)

Use the same instructions and symbols from the Forensic Examination section for charting Missing teeth at Time of Accession and Treatments Completed after Accession (Box 2). When charting existing restorations, draw the restoration and show the approximate size, location, and shape in the diagram of the tooth. Identify missing teeth and restorative materials as previously shown in the Forensic Examination section (Charting/Markings). Note: No remarks are made on the Current Status form to indicate materials used.

### Box 3

Box 3, Medical Alert, is readily seen by all clinicians when opening the record. If a medical alert exists, the word "ALERT" is written or stamped in large red letters with a brief explanation following (i.e., ALLERGIC TO PENICILLIN). The use of red ink stamps is encouraged.

### Box 4

Box 4 is used to record the patient's last name, first name, middle initial, and patient/sponsor Social Security Number.

## DENTAL EXAM FORM

The Dental Examination form (EZ603) (fig. 2-22), is a new form that replaces part of the front of the old SF 603 and all of the various SOAP (subjective, objective, assessment, and plan) formats. It is intended to be used on the initial, subsequent periodic, annual, recall, SF 88, and separation exams. It is not intended for emergency or specialty consult exams. All entries are made in **black ink** except as noted. During the dental exam, the examining dentist may direct you to fill out the EZ603 and associated boxes on the form with information. The front page of the Dental Exam Form contains the "S," "O," "A," and "P" sections of the exam that are briefly discussed next.

- Subjective Section (S:)—This section of the form is used to fill out the reason for the examination and the patient's chief complaint.
- Objective Section (O:)—This section is generally meant to record findings and not a diagnosis. The major exception is the caries section where the findings and diagnosis are one and the same.
- Assessment Section (A:)—This section is generally used by the examiner to make a diagnosis.
- Plan Section (P:)—This section is the "Treatment Plan" for the patient.

The EZ603 is a new trial form and may be changed in the future. Instructions for the completion of the EZ603 can be found in MANMED, chapter 6, or current BUMED instructions.

BUMED Approved EZ603 (trial)

## DENTAL EXAM

**S: Reason for Examination:** Accession / Periodic / Separation / SF88 / Other Use INK!

**Chief Complaint:** None/

**O: Type of Exam:** T-1 T-2 **Blood Pressure:** / **HQ dated:** Reviewed

**HQR Finding:** WNL/

**Radiographs Ordered:** BWs Pano PA#

**Radiographic findings:** (except caries)

**Caries, defective restorations & fractured teeth. (radiographic & clinical)** None / Noted as follows:

---

**OCS/Soft Tissue findings:** WNL /

	R	PSR	L	
<b>Endo finding:</b> WNL /				Full
				Mod

**TMD findings:** WNL/Pain/Dysfunction

**Occlusion findings:** WNL/

**3rd Molars findings:** Impacted:# Partial Erupted (Comm):# Symptomatic:#

**Other findings:**

---

**A: Assessment of Chief Complaint:**

**Perio:** Healthy / Givitis (Local/Gan) / Pdtis (Mild/Mod/Severe) / Other **Perio Risk:** High Mod. Low

**Caries/Defective rests:** As noted above **Caries Risk:** High Mod. Low

**Oral Surgery:** **Tobacco Use:** None/

**Endo:** **Occlusion:**

**Other:**

---

**P: Treatment Plan**

Sequence		Department	TREATMENT NEEDS		DATA ENTRY	
			Phase 1 (Urgent)	Phase 2 (Routine)	Urgent	Routine
Phase 1	Phase 2				Phase 1	Phase 2
		<b>PSR SCORE</b>			3 4 *	1 2 3
		<b>HYGIENE</b>	RDH(1) DT(2) DO(3)	RDH(1) DT(2) DO(3)	1 2 3	1 2 3
		<b>OPER</b> (Teeth)			1 2 3	1 2 3
		<b>ORAL SURG</b> Simple Complex (Teeth)	1 16 17 32	1 16 17 32	4 5 6	4 5 6
		<b>PERIO</b> (Sextants) (with PSR score of 3 4 or *)	1 2 3 4 5 6	1 2 3 4 5 6	1 2 3	1 2 3
		<b>ENDO Ant.</b> (Teeth) Post.			1 2 3	1 2 3
		<b>PROS</b> (Teeth) Fix. Rem.			1 2 3	1 2 3
		<b>ORAL DIAG</b>			1	1
		<b>SEALANTS</b> (Teeth)			1 2 3	1 2 3
					4 5 6	4 5 6

**REMARKS / AMENDMENTS / CONSULTS / SPECIAL EVALUATIONS:** (See reverse) WLR

---

Patient counseled regarding the health hazards associated with tobacco use and where to seek cessation assistance as appropriate.

Patient has been advised of the findings of this examination and treatment plan.	Treatment completed and T2 exam performed this date.	RECALL DATE:
Examiner's Signature	Examiner's Signature	TECHNICIAN INITIALS:
Date:	Date:	RECALL INTERVAL:   12 Months
Name Stamp:	Name Stamp:	DENTAL CLASS
		1 2 3 4
Patient's Last Name:	First Name:	MI: SSN (patient / sponsor):

DTV2f222

Figure 2-22.—Dental Exam Form, BUMED-approved EZ603.

### INSTRUCTIONS FOR COMPLETING THE BACK OF THE EZ603

The reverse side of the EZ603 (which is blank) is provided for recording the narrative comments associated with the dental exam and related consultation. Commands are authorized to overprint this section with command specific formats that will facilitate the completion of the dental examination.

For placement in the Dental Record, the EZ603 is placed with the Plan or "P" side facing up. It is located on top of any accompanying EZ603As and under the Current Status Form.

### INSTRUCTIONS FOR COMPLETING THE EZ603A

This form (fig. 2-23) functions the same as the old SF603 (side 2) and SF603A with the exception of no pictographs of the teeth. Record the completion of all dental treatment such as the treatment plan, dental emergencies, results from Report of Medical Examination (SF 88), and any other narrative dental findings on the EZ603A.

An additional column has been added on the far left side to indicate the tooth number (s) of the treatment provided on that date. This will facilitate



MEDICAL RECORD		REPORT OF MEDICAL EXAMINATION			DATE OF EXAM																																																																																																																									
1. LAST NAME—FIRST NAME—MIDDLE NAME		2. IDENTIFICATION NUMBER		3. GRADE AND COMPONENT OR POSITION																																																																																																																										
4. HOME ADDRESS (Number, street or RFD, city or town, state and ZIP code)			5. EMERGENCY CONTACT (Name and address of contact)																																																																																																																											
6. DATE OF BIRTH	7. AGE	8. SEX <input type="checkbox"/> FEMALE <input type="checkbox"/> MALE		9. RELATIONSHIP OF CONTACT																																																																																																																										
10. PLACE OF BIRTH		11. RACE <input type="checkbox"/> WHITE <input type="checkbox"/> BLACK <input type="checkbox"/> AMERICAN INDIAN/ ALASKA NATIVE <input type="checkbox"/> HISPANIC WHITE <input type="checkbox"/> HISPANIC BLACK <input type="checkbox"/> ASIAN/PACIFIC ISLANDER																																																																																																																												
12a. AGENCY		12b. ORGANIZATION UNIT		13. TOTAL YEARS GOVERNMENT SERVICE a. MILITARY      b. CIVILIAN																																																																																																																										
14. NAME OF EXAMINING FACILITY OR EXAMINER, AND ADDRESS			15. RATING OR SPECIALTY OF EXAMINER																																																																																																																											
			16. PURPOSE OF EXAMINATION																																																																																																																											
<b>17. CLINICAL EVALUATION</b>																																																																																																																														
NOR MAL	(Check each item in appropriate column, enter "NE" if not evaluated.)				ABNOR MAL																																																																																																																									
NOR MAL	(Check each item in appropriate column, enter "NE" if not evaluated.)				ABNOR MAL																																																																																																																									
A. HEAD, FACE, NECK AND SCALP					O. PROSTATE (Over 40 or clinically indicated)																																																																																																																									
B. EARS-GENERAL (INTERNAL CANALS) <i>(Auditory acuity under items 39 and 40)</i>					P. TESTICULAR																																																																																																																									
C. DRUMS (Perforation)					Q. ANUS AND RECTUM (Hemorrhoids, Fistulae) (Hemocult Results)																																																																																																																									
D. NOSE					R. ENDOCRINE SYSTEM																																																																																																																									
E. SINUSES					S. G-U SYSTEM																																																																																																																									
F. MOUTH AND THROAT					T. UPPER EXTREMITIES (Strength, range of motion)																																																																																																																									
G. EYES-GENERAL (Visual acuity and refraction under items 28, 29, and 38)					U. FEET																																																																																																																									
H. OPHTHALMOSCOPIC					V. LOWER EXTREMITIES (Except feet) (Strength, range of motion)																																																																																																																									
I. PUPILS (Equality and reaction)					W. SPINE, OTHER MUSCULOSKELETAL																																																																																																																									
J. OCULAR MOTILITY (Associated parallel movements nystagmus)					X. IDENTIFYING BODY MARKS, SCARS, TATTOOS																																																																																																																									
K. LUNGS AND CHEST					Y. SKIN, LYMPHATICS																																																																																																																									
L. HEART (Thrust, size, rhythm, sounds)					Z. NEUROLOGIC (Equilibrium tests under item 41)																																																																																																																									
M. VASCULAR SYSTEM (Varicosities, etc.)					AA. PSYCHIATRIC (Specify any personality deviation)																																																																																																																									
N. ABDOMEN AND VISCERA (Include hernia)					BB. BREASTS																																																																																																																									
					CC. PELVIC (Females only)																																																																																																																									
NOTES: (Describe every abnormality in detail. Enter pertinent item number before each comment. Continue in item 42 and use additional sheets if necessary)																																																																																																																														
<b>18. DENTAL (Place appropriate symbols, shown in examples, above or below number of upper and lower teeth.)</b>																																																																																																																														
<table border="1" style="width:100%; border-collapse: collapse; font-size: small;"> <thead> <tr> <th colspan="2">Restorable</th> <th colspan="2">Non-restorable</th> <th colspan="2">Missing</th> <th colspan="2">Replaced by</th> <th colspan="2">Fixed Partial</th> </tr> <tr> <th>1</th><th>2</th><th>3</th> <th>1</th><th>2</th><th>3</th> <th>1</th><th>2</th><th>3</th> <th>1</th><th>2</th><th>3</th> </tr> </thead> <tbody> <tr> <td>32</td><td>31</td><td>30</td> <td>Teeth</td> <td>32</td><td>31</td><td>30</td> <td>Teeth</td> <td>32</td><td>31</td><td>30</td> <td>Dentures</td> <td>32</td><td>31</td><td>30</td> </tr> <tr> <td>R</td> <td colspan="12" style="text-align: center;">( X X X X )</td> <td>O</td> <td colspan="2"></td> </tr> <tr> <td>I</td> <td>1</td><td>2</td><td>3</td><td>4</td><td>5</td><td>6</td><td>7</td><td>8</td><td>9</td><td>10</td><td>11</td><td>12</td><td>13</td><td>14</td><td>15</td><td>16</td><td>L</td> </tr> <tr> <td>G</td> <td>32</td><td>31</td><td>30</td><td>29</td><td>28</td><td>27</td><td>26</td><td>25</td><td>24</td><td>23</td><td>22</td><td>21</td><td>20</td><td>19</td><td>18</td><td>17</td><td>F</td> </tr> <tr> <td>H</td> <td colspan="12" style="text-align: center;">X X X X</td> <td>X</td> <td colspan="2"></td> </tr> <tr> <td>T</td> <td colspan="12" style="text-align: center;">X X X X</td> <td>X</td> <td colspan="2"></td> </tr> </tbody> </table>					Restorable		Non-restorable		Missing		Replaced by		Fixed Partial		1	2	3	1	2	3	1	2	3	1	2	3	32	31	30	Teeth	32	31	30	Teeth	32	31	30	Dentures	32	31	30	R	( X X X X )												O			I	1	2	3	4	5	6	7	8	9	10	11	12	13	14	15	16	L	G	32	31	30	29	28	27	26	25	24	23	22	21	20	19	18	17	F	H	X X X X												X			T	X X X X												X			REMARKS AND ADDITIONAL DENTAL DEFECTS AND DISEASES  Type 2 Exam. Class 3 Qualified: Yes    No
Restorable		Non-restorable		Missing		Replaced by		Fixed Partial																																																																																																																						
1	2	3	1	2	3	1	2	3	1	2	3																																																																																																																			
32	31	30	Teeth	32	31	30	Teeth	32	31	30	Dentures	32	31	30																																																																																																																
R	( X X X X )												O																																																																																																																	
I	1	2	3	4	5	6	7	8	9	10	11	12	13	14	15	16	L																																																																																																													
G	32	31	30	29	28	27	26	25	24	23	22	21	20	19	18	17	F																																																																																																													
H	X X X X												X																																																																																																																	
T	X X X X												X																																																																																																																	
<b>19. TEST RESULTS (Copies of results are preferred as attachments)</b>																																																																																																																														
A. URINALYSIS: (1) SPECIFIC GRAVITY			B. CHEST X-RAY OR PPD (Place, date, film number and result)																																																																																																																											
(2) URINE ALBUMIN			(4) MICROSCOPIC																																																																																																																											
(3) URINE SUGAR																																																																																																																														
C. SYPHILIS SEROLOGY (Specify test used and results)			D. EKG	E. BLOOD TYPE AND RH FACTOR	F. OTHER TESTS																																																																																																																									
NSN 7540-00-834-4038 88-128			STANDARD FORM 88 (Rev. 10-9-1) Prescribed by: GSA/ICMR FIRM 141 CFR 201-9.202-1																																																																																																																											

Figure 2-24.—Report of Medical Examination, SF 88, (front) Box 18.

DTV2f224

box 18. Use these symbols to chart the lower portion of this box. Box 18 also contains space for the dentist's "Remarks and Additional Dental Defects and Diseases." In this space, type, print, or stamp the type of dental exam, dental classification, and qualified "YES" or "NO."

**Box 43**

Include here a summary of the patient's dental defects and the dentist's diagnosis. Since the summary

refers to the items noted in box 18 (the dental section of the report), mark in the summary #18 and list defects and diagnosis.

**Box 50**

Type, print or stamp the examining dentist's name, rank, DC, and USN (or USNR) or civilian title (DDS/DMD) if a contract dentist performs the examination. A dentist or physician signs his or her signature in box 50.

NAME										IDENTIFICATION NUMBER										NO. OF SHEETS ATTACHED																																																																					
MEASUREMENTS AND OTHER FINDINGS																																																																																									
20. HEIGHT					21. WEIGHT					22. COLOR HAIR					23. COLOR EYES					24. BUILD <input type="checkbox"/> SLENDER <input type="checkbox"/> MEDIUM <input type="checkbox"/> HEAVY <input type="checkbox"/> OBESE					25. TEMPERATURE																																																																
26. BLOOD PRESSURE (Arm at heart level)															27. PULSE (Arm at heart level)																																																																										
A. SITTING			B. RECUMBENT			C. STANDING (5 mins.)			A. SITTING			B. RECUMBENT			C. STANDING (3 mins.)			D. AFTER EXERCISE			E. 2 MINS. AFTER																																																																				
SYS.			DIAS.			SYS.			DIAS.			SYS.			DIAS.			SYS.			DIAS.			SYS.			DIAS.																																																														
28. DISTANT VISION										29. REFRACTION										30. NEAR VISION																																																																					
RIGHT 20/					CORR. TO 20/					BY					S.					CX					CORR. TO					BY																																																											
LEFT 20/					CORR. TO 20/					BY					S.					CX					CORR. TO					BY																																																											
31. HETEROPHORIA (Specify distance)																																																																																									
ESO					EXO					R.H.					L.H.					PRISM DIV.					PRISM CONV. CT					PC					PD																																																						
32. ACCOMMODATION										33. COLOR VISION (Test used and result)										34. DEPTH PERCEPTION (Test used and score)																																																																					
RIGHT					LEFT					UNCORRECTED					CORRECTED																																																																										
35. FIELD OF VISION										36. NIGHT VISION (Test used and score)										37. RED LENS TEST																																																																					
RIGHT					LEFT					RIGHT					LEFT					38. INTRAOCULAR TENSION																																																																					
RIGHT					LEFT					RIGHT					LEFT					39. HEARING																																																																					
RIGHT WV					/15 SV					/15					250					256					500					512					1000					1024					2000					2048					3000					3096					4000					4096					8000					8144					8192				
LEFT WV					/15 SV					/15					RIGHT					LEFT					40. AUDIOMETER					41. PSYCHOLOGICAL AND PSYCHOMOTOR (Tests used and score)																																																											
RIGHT					LEFT					RIGHT					LEFT					RIGHT					LEFT					RIGHT					LEFT					RIGHT					LEFT					RIGHT					LEFT					RIGHT					LEFT																								
42. NOTES (Continued) AND SIGNIFICANT OR INTERVAL HISTORY																																																																																									
(Use additional sheets if necessary)																																																																																									
43. SUMMARY OF DEFECTS AND DIAGNOSES (List diagnoses with item numbers)																																																																																									
<p>#18: Severe periodontoclasia, 10 mm overbite, 2 mm diastema between 8 &amp; 9</p>																																																																																									
44. RECOMMENDATIONS - FURTHER SPECIALIST EXAMINATIONS INDICATED (Specify)																				45A. PHYSICAL PROFILE																																																																					
																				P U L H E S																																																																					
46. EXAMINEE (Check)																				45B. PHYSICAL CATEGORY																																																																					
A. <input type="checkbox"/> IS QUALIFIED FOR																				A										B										C										E																																							
B. <input type="checkbox"/> IS NOT QUALIFIED FOR																																																																																									
47. IF NOT QUALIFIED, LIST DISQUALIFYING DEFECTS BY ITEM NUMBER																																																																																									
48. TYPED OR PRINTED NAME OF PHYSICIAN															SIGNATURE																																																																										
49. TYPED OR PRINTED NAME OF PHYSICIAN															SIGNATURE																																																																										
50. TYPED OR PRINTED NAME OF DENTIST OR PHYSICIAN (Indicate which)															SIGNATURE																																																																										
A. B. SMITH, LCDR, DC, USN															A. B. Smith																																																																										
51. TYPED OR PRINTED NAME OF REVIEWING OFFICER OR APPROVING AUTHORITY															SIGNATURE																																																																										

STANDARD FORM 88 (Rev. 10-94) BACK

DTV2f225

Figure 2-25.—Report of Medical Examination, SF 88, (back) boxes 43 and 50.

### ADDITIONAL DENTAL TREATMENT FORMS

Two other forms may be associated with dental treatment. These forms are the Consultation Sheet, SF 513, and the Reserve Dental Assessment and Certification, NAVMED 6600/12, which are discussed next.

#### CONSULTATION SHEET, SF 513

Dental Treatment Facilities (DTFs), Medical Treatment Facilities (MTFs), and shipboard medical

and dental departments use the SF 513 (fig. 2-26) to refer patients from one DTF/MTF, or department to another. Please note that SF 513 refers patients with both dental and medical conditions needing a second opinion or a referral to a specialist for further evaluation or treatment. To assist you in filling out this form, make the following entries on the SF 513:

- To: Enter the name of the DTF/MTF, or department to which the patient is being referred.
- From: The name of the requesting facility.

MEDICAL RECORD		CONSULTATION SHEET	
<b>REQUEST</b>			
To: Dental Department Naval Hospital, San Diego, CA		From: (Requesting physician or activity) Naval Dental Clinic, San Diego	DATE OF REQUEST 23 Mar 98
<small>REASON FOR REQUEST (Complaints and findings)</small>			
Chief Complaint: "My lower right jaw is painful and I can't get my teeth together on that side."			
Finding: This 23 year old male reported to sick call this morning complaining of pain in posterior of right Man. quadrant and inability to occlude on this side. Exam. reveals large contusion area, right angle of Man. Man. displaced on right side. Pain and movement upon palpation of lower right side.			
<small>PROVISIONAL DIAGNOSIS</small>			
Fracture, right Man.			
<small>DOCTOR'S SIGNATURE</small> <i>P. T. Boate</i> P. T. Boate, LCDR, DC, USN	<small>APPROVED</small>	<small>PLACE OF CONSULTATION</small> <input type="checkbox"/> BEDSIDE <input type="checkbox"/> ON CALL	<input type="checkbox"/> ROUTINE <input type="checkbox"/> TODAY <input type="checkbox"/> 72 HOURS <input type="checkbox"/> EMERGENCY
<small>CONSULTATION REPORT</small>			
(Continued on reverse side)			
<small>SIGNATURE AND TITLE</small>			<small>DATE</small>
<small>IDENTIFICATION NO.</small>	<small>ORGANIZATION</small>	<small>REGISTER NO.</small>	<small>WARD NO.</small>
<small>PATIENT'S IDENTIFICATION (For typed or written entries give: Name-last, first, middle, grade, rank, rate, hospital or medical facility)</small>			<small>CONSULTATION SHEET STANDARD FORM 513 (Rev 9-77) Prescribed by GSA/ICMR FPMR 01-11806-8 513-107</small>
WALTER, T. Door USN/AD SK2 555-55-5555 Naval Dental Clinic, San Diego, CA			

DTV2f226

Figure 2-26.—Consultation Sheet, SF 513.

- Date of Request: The date the Consultation Sheet is prepared.
- Reason for Request: The reason as stated by the dentist or requester.
- Provisional Diagnosis: The diagnosis as stated by the dentist or requester.
- Doctor's Signature: Type, print, or stamp the name, rank, title of the dentist or requester with his or her signature in this space.
- Place of Consultation: Check "bedside" or "On Call." Also mark the next box as "Routine," "Today," "72 Hours," or "Emergency."
- Consultation Report: **Leave blank.** This section will be filled in by the person receiving the form.
- Patient's Identification: The patient's name (last, first, and middle initial), branch of service and status, rank/rate, family prefix code, and social security number, and the activity to which the patient is assigned.

## **RESERVE DENTAL ASSESSMENT AND CERTIFICATION, NAVMED 6600/12**

Voluntary Training Unit (VTU) or Selected Reserve (SELRES) personnel **may** have this additional form included in their dental records. Use NAVMED 6600/12 in conjunction with the Naval Reserve T-1 or T-2 dental examination that is performed every 5 years or with any required physical examination. Instructions for completion of the NAVMED 6600/12 is found in MANMED, chapter 6.

### **PATIENT DISMISSAL**

Once the examination is completed, return the patient's dental prosthesis if it was removed for the exam. The dentist may have instructions for the

patient; for example, information regarding medications or future appointments. Make sure that the patient understands the instructions given by the dentist. Remove the patient napkin from the patient and place it over the contaminated instruments.

Push the dental operating light and the bracket table out of the way so the patient will not bump against them. Return the dental chair to its lowest upright position, raise the arm of the chair and assist the patient from the chair.

Direct the patient to the front desk to make future appointments if needed. Remove all instruments and prepare the DTR for the next patient. Follow the infection control, sterilization, and disinfection procedures outlined in *Dental Technician*, Volume 1, chapters 9 and 10.





## CHAPTER 3

# PREVENTIVE DENTISTRY

### INTRODUCTION

The goal of preventive dentistry is to assist the patient in either establishing control of his or her dental disease or in continuing to maintain good oral health. Preventive dentistry includes all clinical tests, treatments, and patient education for the purpose of preventing oral disease and supporting the effectiveness of treatment aimed at caries and periodontitis. All patients will receive a careful assessment of their oral health needs and be provided with an individualized preventive dentistry treatment plan.

### PREVENTIVE DENTISTRY TECHNICIAN

Each dental treatment facility has an appointed preventive dentistry officer responsible for the formulation, supervision, and execution of all aspects of the preventive dentistry program as per SECNAVINST 6600.5. For you to perform preventive dentistry procedures, you should elect to qualify as an expanded function preventive dentistry technician at your command. Details for this program can be found in BUMEDINST 6600.13. Some of the duties of a preventive dentistry technician are as follows:

- Completes a thorough dental health questionnaire review
- Performs supragingival scalings with hand and sonic instruments
- Performs oral prophylaxis
- Provides nutrition/diet counseling
- Applies topical anticariogenic agents
- Places pit and fissure sealants
- Delivers pre-operative oral antimicrobial rinses
- Sharpens and demonstrates proper care of periodontal instruments
- Demonstrates proper patient instruction in the use of home care devices

### ORAL PROPHYLAXIS

The term *prophylaxis* means prevention of disease. When you apply its broadest interpretation to the oral cavity, it includes all measures to prevent oral disease. For our purposes, we define oral prophylaxis as *the clinical procedures that you perform for your patients*. Our discussion will include evaluation of records, the seating of the patient, instruments, examinations, and contraindications to prophylaxis. We will begin with the evaluation of the patient's dental health record.

### PREPARATION FOR ORAL PROPHYLAXIS

Before the patient enters the dental treatment room (DTR), evaluate his or her dental record for completeness. The folder should contain the patient's dental records, current radiographs, a current dental health questionnaire and any other applicable forms discussed in *Dental Technician*, Volume 1, NAVEDTRA 12572, chapter 2, and chapter 2 of this manual. Check the past medical and dental history of the patient. Check the recommendations that were made during previous oral prophylaxis appointments and the recent dental examinations. If the patient has had radiographs taken since the previous oral prophylaxis, evaluate them for subgingival calculus and restoration margin overhangs. Subgingival calculus can appear on a radiograph as a "spur" or deposit between the teeth, below the gingival margin.

**NOTE:** Subgingival calculus and overhangs can only be removed by a dental officer or dental hygienist.

If you find any subgingival calculus during the patient examination or treatment, contact a dental officer or hygienist who will remove it either during your appointment with the patient or at a later time. A preventive dentistry technician should only treat patients with supragingival calculus who are scheduled for routine oral prophylaxis. Patients with subgingival calculus will be appointed with a dental officer or dental hygienist. The dental treatment plan will indicate who will treat the patient to ensure proper scheduling.

## CONTRAINDICATIONS TO PROPHYLAXIS

Evaluate the medical history of dental patients before treatment begins. NAVMED Form 6600/3 will be completed to find out whether there are any medical problems that can affect dental treatment. Some patients have medical conditions, such as a heart murmur, that require antibiotic treatment 1 hour before you can treat them. If the medical history indicates the patient has or had a heart murmur, ask the patient if he or she has taken any antibiotic medicine.

**NOTE:** If any questions on the NAVMED 6600/3 are answered "yes," it is of the utmost importance that you discuss the patient's history with a dental officer before rendering treatment.

## PATIENT AND OPERATOR POSITIONING

Correct operator and patient positioning helps to accomplish the following:

- Prevents operator and patient fatigue and discomfort
- Permits the operator to gain a clear view of the tooth being worked on
- Allows easy access of instruments to the teeth
- Saves time

### Patient Positioning

Position the back of the patient's chair at about a 15° angle (slightly raised above the parallel position) to the floor (fig. 3-1).

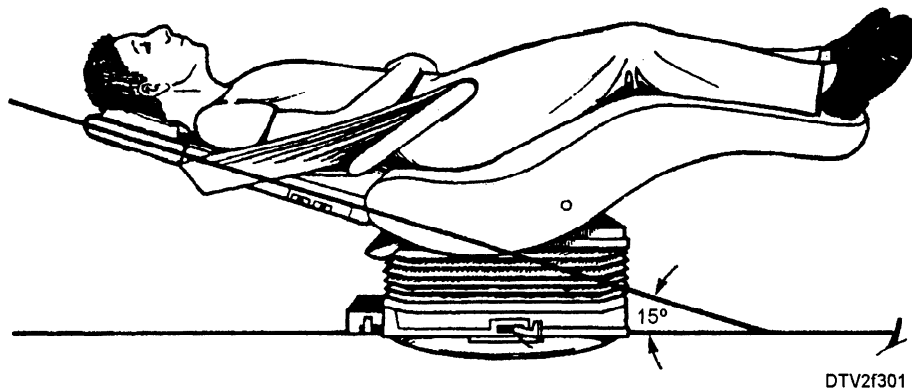


Figure 3-1.—Positioning of the patient.

The patient's heels should be even or slightly higher than the head. The top of the patient's head must be even with the end of the headrest for you to see and reach the patient's mouth. If possible, position the bracket tray out of the patient's direct vision. Ask the patient if he or she is in a comfortable position.

### Operator Positioning

To properly position yourself in the seated operator position, adjust the chair so that you are comfortable and your posture is correct. To maintain good working posture (fig. 3-2), position your feet flat on the floor, thighs parallel to the floor, back and head straight, and arms at waist level. Keep your body weight evenly distributed.

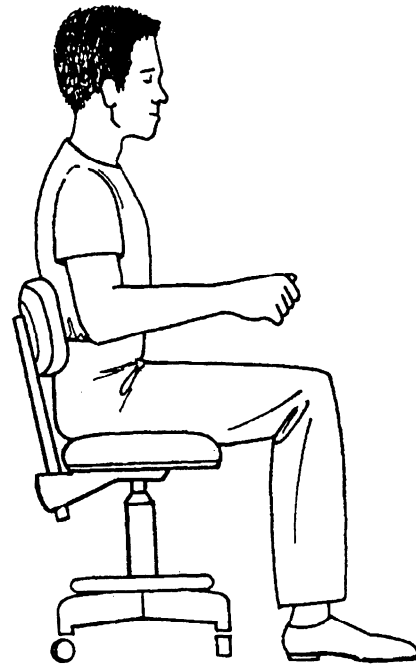


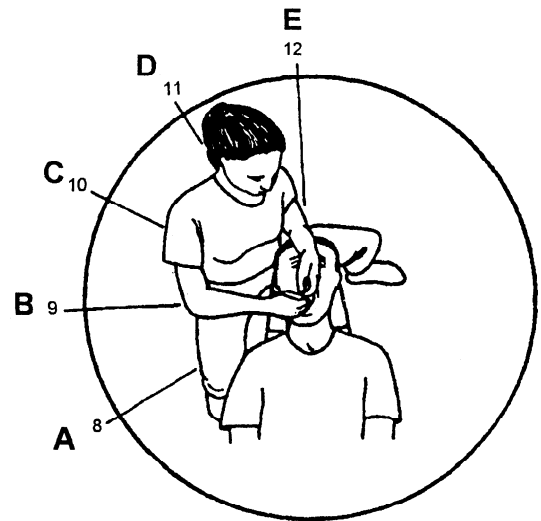
Figure 3-2.—Seated operator position.

Your unit light is kept at arms length above or in front of the patient. The light should be easy to reach but not near the patient's or operator's head. Illumination of the treatment area becomes more difficult when the light is positioned too close to the patient. In addition the light generates a large amount of heat. Direct the unit light from above the patient as shown in figure 3-3.

The position of the bracket table should be low enough to permit a clear view of the instruments. It should also be a reasonable distance above and to the side of the patient.

The patient's open mouth should be level with your waist. This will enable you to reach the patient's mouth while maintaining your arms at waist level. For mandibular instrumentation, the patient will have his or her mouth open in a chin-down position. Position your legs under the back of the chair. The back of the dental chair should touch the top of your legs, or you may straddle the back of the chair with your legs.

Now you are ready to learn how to position yourself around your patient in relation to the treatment areas of the mouth. Operating positions for right-handed and left-handed technicians are usually identified in relation to a 12-hour clock (figs. 3-4 and 3-5).

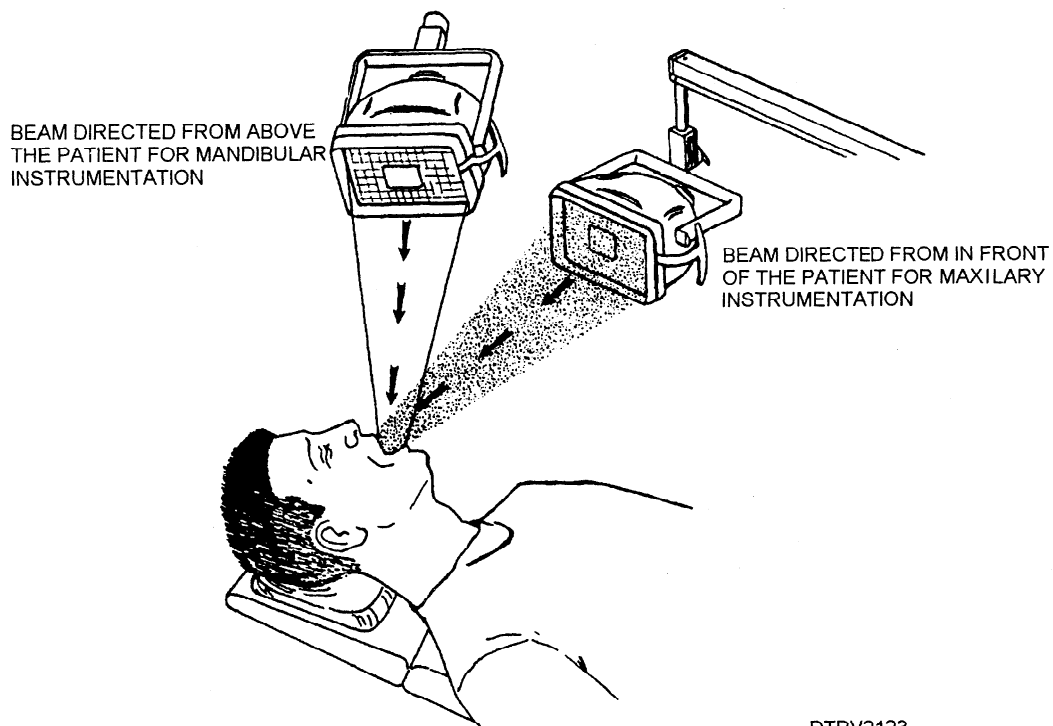


- A. 8 O'CLOCK POSITION, OPERATOR SEATED TO THE FRONT OF THE PATIENT
- B. 9 O'CLOCK POSITION, OPERATOR SEATED AT THE SIDE OF THE PATIENT
- C. 10 O'CLOCK
- D. 11 O'CLOCK POSITION (ILLUSTRATED ABOVE)
- E. 12 O'CLOCK POSITION, OPERATOR SEATED TO THE REAR OF THE PATIENT

DTV2f304

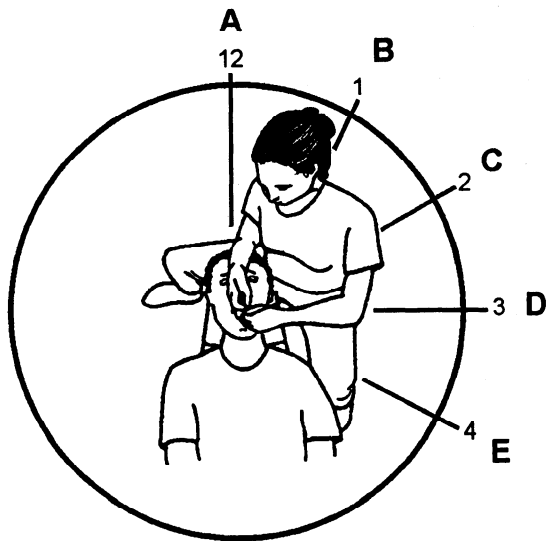
Figure 3-4.—Operating positions—right-handed operator.

As you try various positions, notice how they afford you a clear view of the treatment area. You will not be able to obtain a clear view of the teeth surfaces in the mouth through operator and patient positioning



DTBV2123

Figure 3-3.—Unit light placement.



- A. 12 O'CLOCK POSITION, OPERATOR SEATED TO THE REAR OF THE PATIENT
- B. 1 O'CLOCK POSITION, (ILLUSTRATED ABOVE)
- C. 2 O'CLOCK POSITION
- D. 3 O'CLOCK POSITION, OPERATOR SEATED AT THE SIDE OF THE PATIENT
- E. 4 O'CLOCK POSITION, OPERATOR SEATED TO THE FRONT OF THE PATIENT

DTV2f305

Figure 3-5.—Operating positions-left-handed operator.

alone. The use of the mouth mirror will assist you to obtain a complete view.

## SCREENING EXAMINATION

Before you begin any scaling procedures, make a thorough appraisal of the condition of the patient's mouth. This examination serves three purposes:

- Determines the needs of the patient
- Determines the sequence in which these needs must be met
- Provides you with useful information for conducting the dental health counseling

The screening examination has two phases:

- Observation of the entire oral mucosa
- Examination of the teeth and gingival tissues

Look for ulcers or sores on the lips, skin, or intraoral mucosa. These may be the result of viral or other infections, which could preclude your treatment of the patient. You can also ask the patient if he or she has any sensitive or painful teeth or areas in the mouth about which you should know. If you see something during your examination that you do not recognize as a normal feature of the anatomy, check with a dental officer before proceeding.

Plaque is nearly transparent and difficult to see without the use of a stain or disclosing agent to highlight its presence. These agents color the plaque, but they do not color clean tooth surfaces. The coloring agent used in disclosing is a harmless red food dye and comes in the form of tablets or liquid. Follow the manufacturer's instructions for use. After your initial examination of the patient, apply a disclosing agent to reveal the presence of plaque before the prophylaxis procedures. This will help you and the patient identify what must be cleaned and will assist in patient education.

## TYPES, USES, AND MAINTENANCE OF PERIODONTAL EQUIPMENT

The ultrasonic scaler, air polishing unit, and sonic scaler were designed for use in oral prophylaxis and other periodontal procedures.

### WARNING

Before operating any equipment, ensure you are familiar with its use, operation, and safety precautions.

## ULTRASONIC SCALER

The ultrasonic scaler converts electrical energy into 30,000 microscopically small mechanical strokes per second. The strokes are transmitted to an insert tip. Combined with a water spray and a light touch, the activated tip rapidly and gently dislodges plaque, calculus, and stain from the teeth. As you can imagine, the ultrasonic unit can generate a great amount of heat. For this reason, water is kept running through the entire unit and expelled from the working end of the instrument. Water aids to cool the tip of the instrument and the tooth structure. The water also serves to wash away debris. The vibratory motion of the tip transmits mechanical energy to water that creates powerful bursts of collapsing bubbles called cavitation. Cavitation aids in the mechanical removal of plaque and calculus by the vibrating tip.

### Components

The four major components of the unit are an electronic generator, a hand piece assembly, a set of interchangeable inserts, and a foot-controlled switch. A picture of an ultrasonic scaler unit is shown in

figure 3-6. Follow the manufacturer's instructions on setup, adjusting water flow, ultrasonic tuning, and ultrasonic power. Some units are tuned automatically while others require manual tuning.

**ELECTRONIC GENERATOR.**—The electronic generator produces the power required to activate the handpiece. The three controls located on the front panel of an automatically tuned ultrasonic unit are the ON/OFF indicator, POWER ADJUSTMENT CONTROL, and a WATER ADJUSTMENT CONTROL. A manually tuned ultrasonic unit will also have a TUNING ADJUSTMENT CONTROL.

**HANDPIECE AND CABLE ASSEMBLY.**—This assembly consists of a handpiece into which interchangeable scaling inserts are placed. A cable connects the handpiece to the generator. To place an

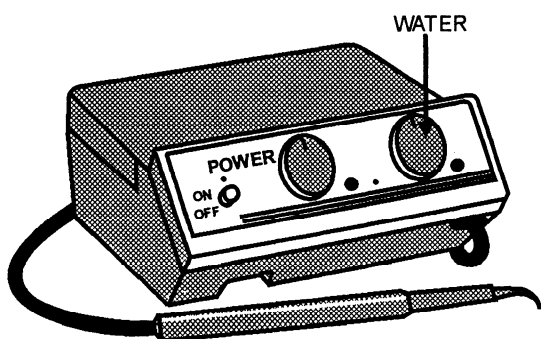
insert into the handpiece, first lubricate the O-ring with water. Then hold the handpiece with the open end upright over a sink or suitable basin. Step on the foot switch to turn on the unit and flood the handpiece chamber with water. Stop flooding when you see the water has reached a level halfway up the handpiece. Push the insert into the open end of the handpiece with a twisting motion (fig. 3-7); a small amount of water may be displaced by the insert stack and may spill out. Check to see if the insert is fully seated. With the insert in place, hold the handpiece in an upright position. Activate the insert and bleed off any air trapped during handpiece insertion. Allow the water to run from the handpiece for a few seconds until it flows without spurting. Repeat this procedure each time an insert is placed into the handpiece. Trapped air does not interfere with the handpiece operation, but can cause excessive heating of the instrument.

**INTERCHANGEABLE INSERTS.**—A set of interchangeable inserts facilitates access to all areas of the mouth. The components of an insert include the insert tip, water outlet, plastic grip, O-ring, connecting body, and the magnetostrictive stack (fig. 3-8). The water outlet delivers preheated water along the entire working length of the tip. The O-ring acts as a water seal when the insert is placed into the open end of the handpiece. A connecting body transmits motion from the stack to insert tip. The magnetostrictive stack converts electrical power supplied to the handpiece into mechanical vibrations to activate the insert tip.

**FOOT CONTROLLED SWITCH.**—The handpiece is activated by a foot-operated on/off switch. When the foot pedal is held down, the handpiece is activated and water flows. Both the handpiece and water flow are shut off when the pedal is released.


**Water Supply**

Attached to the ultrasonic scaling unit is a water supply hose. The free end of the hose attaches to a



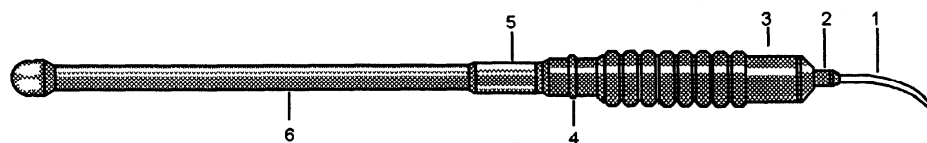
DTV2f306

Figure 3-6.—Ultrasonic scaler unit.



DTV2f307

Figure 3-7.—Placement of the insert into the handpiece.



- 1) INSERT TIP
- 2) WATER OUTLET
- 3) PLASTIC GRIP
- 4) O-RING
- 5) CONNECTING BODY
- 6) MAGNETOSTRICTIVE STACK

DTV2F308

Figure 3-8.—Components of the interchangeable inserts.

water connection on the dental unit. The water supply pressure should range from a minimum of 25 psi to a maximum of 60 psi. Water pressure outside of this range can cause the equipment to malfunction. Refer to the manufacturer's instructions for specific information.

Flush the waterline daily before use to reduce the bacteria that accumulates overnight. Set the water flow to maximum and depress the foot switch for 1 minute without an insert in the handpiece. Before use on each patient, flush the waterline for 30 seconds.

### Ultrasonic Tips and Techniques

A wide variety of inserts are available for use with the ultrasonic scaler. Each insert is designed for a specific use. A power level is recommended by the manufacturer for each insert.

Tip selection is based on the type, location, and amount of calculus deposits present. Larger tips are effective in removing heavy supragingival calculus deposits and stains, where smaller tips used by a dentist or hygienist are similar in design to a scaler and can be used subgingivally. The tips should be dull so they will not damage the tooth and root surface. The various tips and their uses are as follows:

- Beaver-tail ultrasonic tip (fig. 3-9)—Used on the lingual and facial posterior surfaces to remove very heavy, supragingival deposits. Use light pressure with an erasing motion for stain removal and overlapping strokes for calculus removal. Avoid using the sides or face of this insert. Use the high power level with this insert.

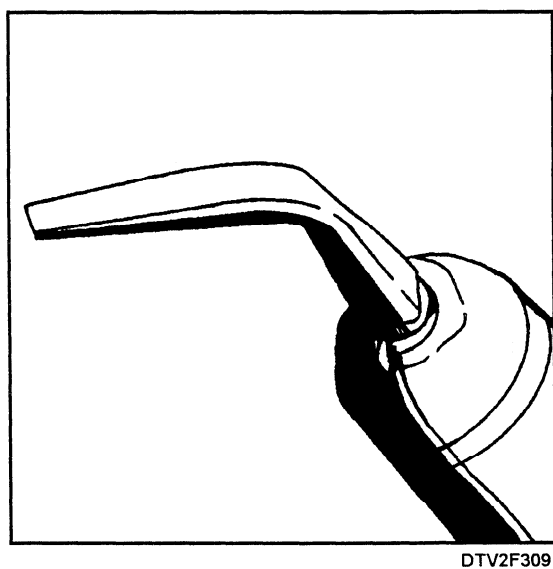


Figure 3-9.—Beaver-tail ultrasonic tip.

- Chisel ultrasonic tip (fig. 3-10)—Used for removing supragingival calculus on anterior teeth. Place the tip against the proximal tooth surface and use a horizontal stroke to remove the calculus. **Set the power level on high for this insert.**

- Universal ultrasonic tip (fig. 3-11)—The most commonly used tip for supra and subgingival calculus deposits in all areas. The universal tip is ideally suited for finishing after completing heavier scaling procedures. Use the sides of the insert with only light pressure, and push or pull strokes. **Set the power level at high for this insert.**

- Periodontal probe ultrasonic tip (fig. 3-12)—Used to remove subgingival calculus. Used by dentist or dental hygienist with a horizontal or vertical stroke. **Set the power level on medium for this insert.**

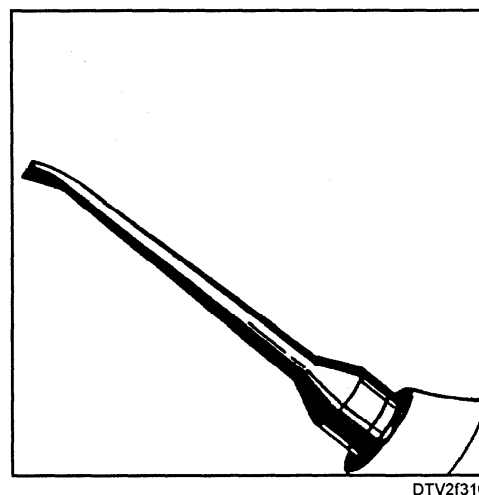


Figure 3-10.—Chisel ultrasonic tip.

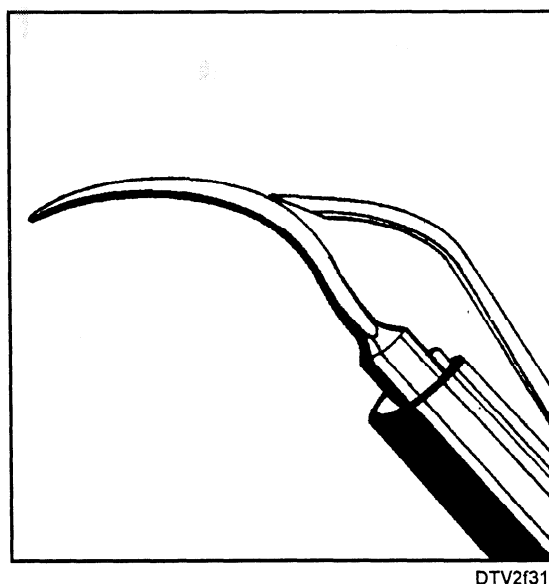



Figure 3-11.—Universal ultrasonic tip.



DTV2f312

Figure 3-12.—Periodontal probe ultrasonic tip.

Before starting ultrasonic scaling, take time to explain the procedure to your patient. The noise, water spray, and vibratory sensation produced by the ultrasonic scaler may frighten the patient if no warning is given. Place a plastic drape on your patient in addition to the patient towel to prevent clothing from becoming wet. If possible, have the patient rinse for 30 seconds with an antimicrobial mouthwash before treatment to reduce aerosol pathogens. The amount of water that will accumulate in the patient's mouth will necessitate the use of a saliva ejector. Ask your patient to hold the evacuation tip if necessary.

Hold the ultrasonic handpiece in a modified pen grasp (discussed later in this chapter) with the end of the hose tucked in the palm of your hand. This prevents the hose from weighing down the handpiece. Establish a fulcrum (discussed later) on a tooth in the same arch as close as possible to the tooth you are treating. The working end of the instrument tip should be adapted to a 10° to 15° angle to the long axis of the tooth. Use the lateral surfaces, face, and back of the instrument tip for scaling. The toe or tip of the working end should **never be used to scale**.

### Patient Sensitivity

If the patient reports tooth sensitivity during ultrasonic scaling, several possibilities exist. First, be certain the insert tip is at a 10° to 15° angle to the tooth surface. You can increase the speed of tip movement over hypersensitive areas to alleviate discomfort. A change in the motion of the insert tip from vertical to horizontal, or vice versa, sometimes helps diminish

sensitivity. It may be necessary to lighten your finger pressure on the handpiece, especially on exposed dentin. If sensitivity persists, decrease the power setting.

**NOTE:** Incorrect adaptation of the instrument to the tooth will cause pain to the patient and damage to the tooth.

It is very important to understand that the instrument tip must be in direct contact with the calculus deposit to be effective. Use light, rapid strokes, keeping the tip moving at all times to avoid heat build up or tooth damage.

### Level I Maintenance

No special maintenance is required; however, several precautionary measures should be followed:

- Do **not** place the unit on or next to a heat source since it could damage the electronic components.
- Do **not** keep the unit in a tightly confined space or corner. Keep it where a normal amount of air will circulate freely on all sides of the unit.
- The unit should **not** be used when the patient or operator of the unit is wearing a cardiac pacemaker.

You may experience some difficulties with the unit that requires minor adjustments. For example, the handpiece may heat up if there is insufficient water flow or air is trapped in the handpiece. Water flow requires adjustment if the spray from the insert does not properly cover the area of the activated insert tip. Water leaks from the handpiece during operation generally indicate that the O-ring on the insert is worn and requires replacement. Always consult the manufacturer's instructions for the causes and corrective measures for other problems.

### AIR POLISHING UNIT

The air polishing unit (fig. 3-13) uses air and water to project a controlled stream of specially processed sodium bicarbonate. It removes gross extrinsic stain, plaque, and soft debris from all exposed surfaces of the tooth enamel. It polishes and cleans tooth surfaces, pits, and fissures. Some patients prefer this method of polishing, which reduces the sense of pressure and heat associated with use of a rubber cup and pumice. Air polishing is ideal for polishing teeth to which

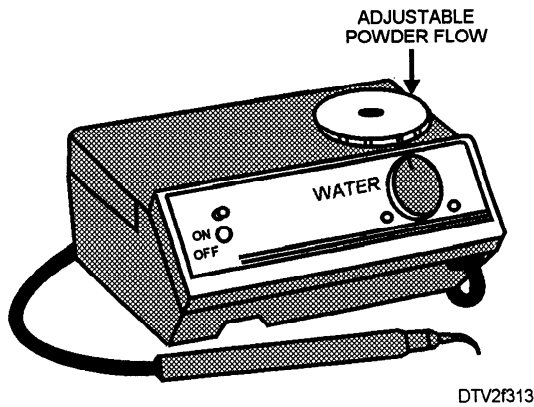


Figure 3-13.—Air polishing unit.

orthodontic bands and brackets are applied. Air polishing of enamel also increases resin bond strength when used before acid etching for sealants and other procedures.

### Components

The three major components of the unit are the air polishing delivery system, foot-controlled switch, and handpiece assembly. Some newer models combine the air polishing and ultrasonic systems. In such units, additional components and controls exist because the units are combined (fig. 3-14). The combination handpiece assembly has separate openings to accommodate the scaling and polishing inserts (fig. 3-15). The operation and maintenance of the combined unit are the same as the two independent units.

### Technique

Keep the handpiece tip approximately 4mm to 5mm from the tooth surface being cleaned. Center the spray on the middle one-third of the tooth and use a constant circular motion. The edge of the spray will

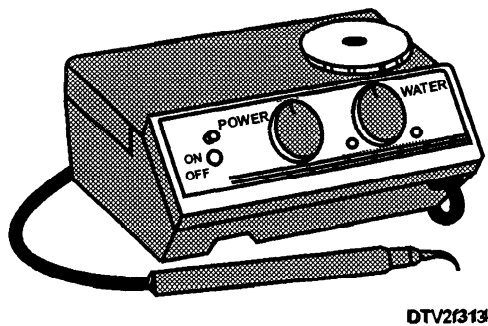


Figure 3-14.—Combined ultrasonic scaler and air polishing unit.

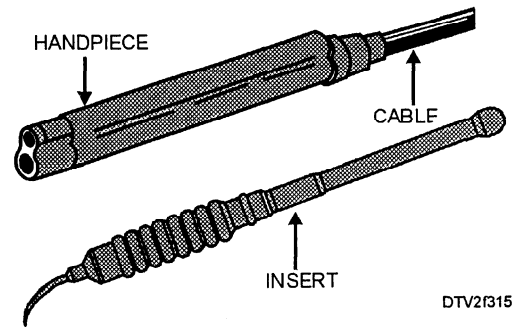


Figure 3-15.—Handpiece assembly of an air polishing unit.

clean the tooth surface near the gingiva. The angulation of the handpiece tip to the surface varies according to the different locations of the teeth.

On the facial and lingual surfaces of all posterior teeth, direct the handpiece slightly distally at an 80° angle toward the gingiva (fig. 3-16). On the facial and lingual surfaces of all anterior teeth, direct the handpiece at a 60° angle toward the gingiva (fig. 3-16). For all occlusal surfaces, direct the handpiece at a 90° angle to the surface.

### Precautions and Contraindications

You must be concerned with several precautions and contraindications to the use of the air polishing system. Avoid direct contact of the cleaning jet with soft tissue. This could seriously and unnecessarily harm mucosa or gingiva. To preclude possible soft tissue emphysema or air embolism effects, never direct the tip into the sulcus. Sodium bicarbonate air polishing of highly polished metal restorations will leave a matte (dull) finish. Avoid prolonged use of this system on cementum or dentin. Consult with a dentist

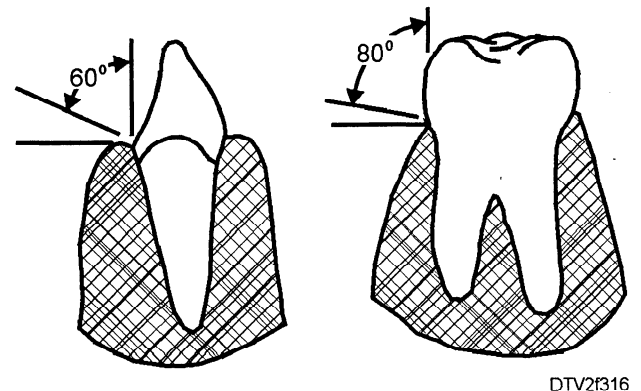


Figure 3-16.—Angulation of the air polishing handpiece tip on facial and lingual surfaces of anterior and posterior teeth.



before air polishing teeth in patients with severe respiratory illness or on a restricted sodium diet. Patients wearing contact lenses must remove them before you use this polishing system.

### Level I Maintenance

The waterline should be flushed daily before use for 60 seconds to reduce any bacteria that accumulates in the line overnight. The handpiece should be flushed for 30 seconds before use between patients. At the end of the day, remove and empty the powder chamber. The cleaning powder must be kept dry and stored in a place that does not exceed 95°F. For additional information on maintenance of the powder chamber and other procedures, refer to the manufacturer's instructions.

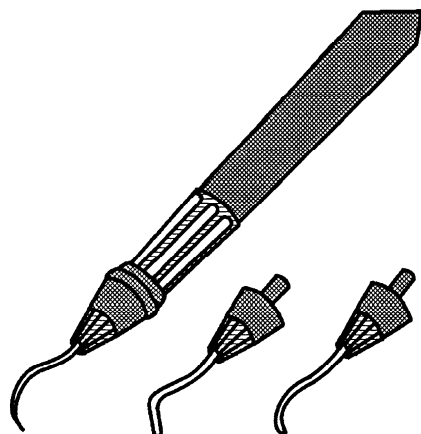
## SONIC SCALER

The sonic scaler is an air-powered, mechanical scaler that runs at sonic frequency and uses a controlled water spray. It removes large calculus deposits and stains from teeth.

### Components

The sonic scaler consists of the scaler handpiece and three types of tips (fig. 3-17). Both the tips and handpiece can be sterilized. The handpiece attaches to the hoses on the dental unit with a swivel attachment coupling. Air and water pressure are controlled by using the air and water control valves on the dental unit. The three type tips and their uses are as follows:

- Universal tip—Used for all surfaces to remove medium and heavy calculus deposits



DTV2B17

Figure 3-17.—Sonic scaler handpiece and tips. Left to right: Universal, Perio, and Sickle tip.

- Perio tip—Breaks up heavy calculus and is recommended for supragingival scaling of the lingual mandibular incisors
- Sickle tip—Recommended for sensitive patients, and to remove light to medium deposits of calculus

### Technique

Lightly apply the vibrating tip to the tooth's surface using a back and forth brush stroke to dislodge the calculus deposits. The handpiece directs a continuous water spray to cool the tip and tooth to prevent overheating. Avoid placing the scaler tip directly on the enamel since this will cause pitting.

### Level I Maintenance

Follow the manufacturer's instructions for instrument sterilization and other maintenance requirements. As with other devices supplied with water from the dental unit, flush the sonic scaler waterline for 60 seconds at the beginning of the workday and for 30 seconds between patients.

## PERIODONTAL SCALING INSTRUMENTS

Periodontal hand scalers are important in removing calculus. These instruments are discussed in chapter 6, "Periodontal Assistance." In addition to hand scaling instruments, part of your preventive dentistry setup will include a mouth mirror and an explorer.

### MOUTH MIRROR

The mouth mirror permits examination of tooth surfaces in areas of the mouth that cannot be viewed directly. The mouth mirror is also useful as a retractor of the patient's tongue and cheeks.

Avoid causing discomfort to the patient when you are using the mouth mirror. Do not use excessive pressure on the handle or shank against the patient's lips or the corner of the mouth. Do not press the edge of the mirror into the gingiva. Since some teeth are sensitive to metal, do not touch the teeth with the mirror when you are inserting it into or removing it from the mouth.

You can prevent fogging of the mirror by:

- Requesting the patient breathe through the nose, rather than the mouth

- Using a special defogging solution
- Warming the mirror by holding it against the patient's buccal mucosa
- Heating the mirror under warm running water

Hold the mirror with a modified pen grasp and use a finger rest close to the area being viewed.

## EXPLORER

The explorer is used for tactile examination of the teeth. It is excellent for detection of calculus. Use it over the entire dentition to ensure all detectable calculus and stains have been removed following an oral prophylaxis. Otherwise, it is likely you will leave some calculus deposits or stains on the teeth.

## INSTRUMENT GRASP

A correct instrument grasp has a direct bearing upon your ability to manipulate instruments. There are three instrument grasps that you may use in combination with a finger rest during oral prophylaxis procedures. We will describe them in the following paragraphs.

### PEN GRASP

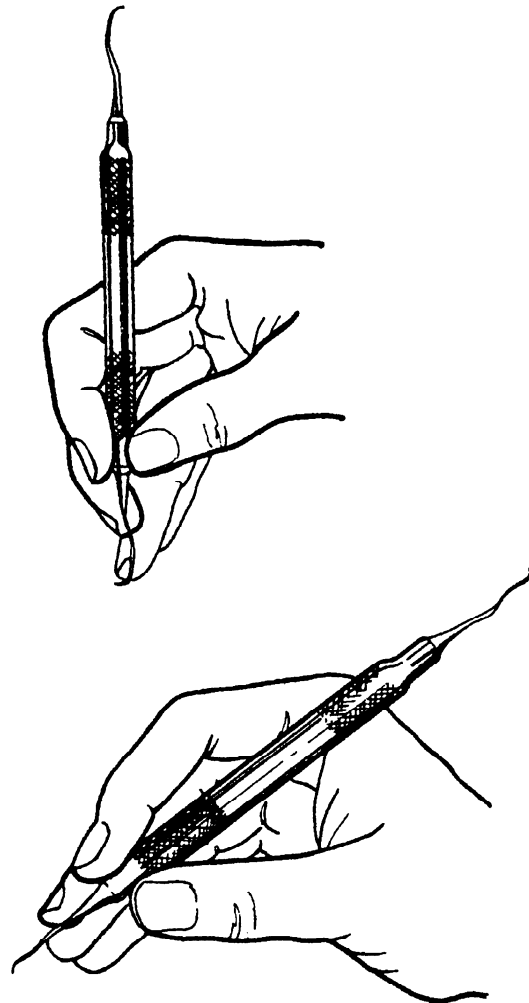
With the pen grasp, hold the instrument the way you would hold a pen when writing. Grasp the handle with your thumb and first finger while your middle finger supports the instrument from underneath. This is a favorite grasp when using the mouth mirror.

### MODIFIED PEN GRASP

With the modified pen grasp, hold the instrument in basically the same way as in the pen grasp, except that the fleshy part of your middle finger rests lightly on the shank of the instrument (fig. 3-18). This finger is used to feel the shank vibrate when the instrument's working end rubs over a rough surface. The middle finger also helps to guide the instrument. The ring finger is used to stabilize the hand in the patient's mouth. Balance your hand and the instrumentation with this finger.

### PALM GRASP

When using the palm grasp, the index, middle, ring, and little finger hold the instrument so that it rests in the palm of your hand. Your thumb remains free to stabilize your hand in the patient's mouth, or it may be



DTV21318

Figure 3-18.—Modified pen grasp.

used to support an instrument when sharpening (fig. 3-19). This grasp is rarely used in the mouth and only when exceptional force is needed.

## FINGER REST

Use a finger rest or fulcrum to maintain control of the instrument. It is a stabilizing point for your hand while you are operating in the mouth. You should use a finger rest in the same arch and as close to the working area as possible. In the modified pen grasp, the third or ring finger is always used as a finger rest. This finger can rest on the teeth, the gingiva, another finger, or a combination of these. **Do not** use soft movable tissue for a finger rest. When you are holding the instrument in a pen grasp, use your third finger as the finger rest. When you are using the palm grasp, use your thumb for

## ORAL PROPHYLAXIS PROCEDURES

As you perform the prophylaxis procedure, remember that you are treating a living, breathing human being. You must accomplish your task in a manner that does not irritate the patient. Your job is not to chastise the patient for past dental neglect, but to **rehabilitate** and **educate** the patient toward improved oral health.

Before starting any scaling or prophylaxis procedure, ensure that your patient takes out of the mouth any removable partial or complete dentures that are present. This lets you inspect all the oral tissues and will avoid possible damage to the prosthetic teeth during the scaling or polishing procedures. Place the prosthetic appliance in a cup of water or in a moist towel.

Be as gentle as possible during the scaling procedure so that you do not injure the tooth or its surrounding tissues. Frequently irrigate and suction the scaling site to prevent particles of calculus from becoming implanted in the gingival tissues.

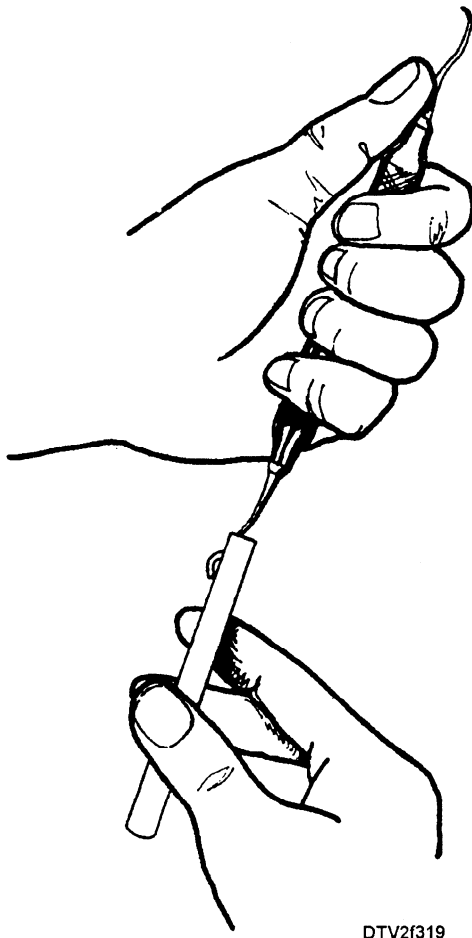While scaling, you will occasionally need to remove calculus and debris from the working end of your instrument. You can do this in several ways. You can place a dappen dish containing hydrogen peroxide on the bracket table and simply dip the instrument tip into the solution, or you can wipe the instrument on a gauze sponge attached to the towel chain or held in your non-scaling hand. Avoid wiping the instrument directly on the patient's towel because blood and debris from your hands or the instrument can stain the patient's clothing.

### A SYSTEMATIC APPROACH TO PERIODONTAL SCALING

You should approach each patient with a specific plan of treatment. This will vary with individual patient needs. A routine oral prophylaxis for a patient who practices adequate oral hygiene can usually be completed in one appointment. Patients who have neglected their oral health, such as those with periodontitis and or have subgingival calculus, will be appointed with a dental hygienist or dentist.

Your examination and scaling procedure should be done with a definite routine. By using a routine, you will be able to treat as many teeth as possible from one position, and ensure you will not overlook any tooth or tooth surface. The recommended routine is as follows:

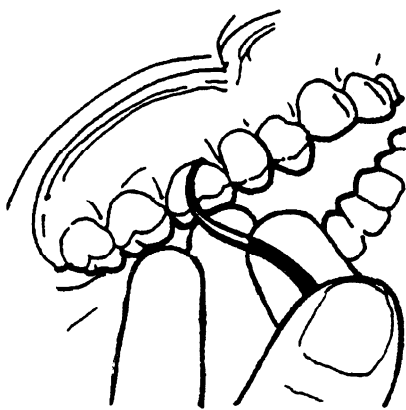
1. Mandibular anterior teeth



DTV2f319

Figure 3-19.—Palm grasp.

the finger rest. The same finger that is used as a finger rest also acts as a fulcrum, the pivot point around which the necessary force to remove the calculus can be exerted. Figure 3-20 illustrates the correct finger position for a finger rest.



DTV2f320

Figure 3-20.—Finger rest.

2. Right mandibular posterior teeth
3. Left mandibular posterior teeth
4. Maxillary anterior teeth
5. Right maxillary posterior teeth
6. Left maxillary posterior teeth

Starting with the mandibular anterior teeth, examine the facial and proximal surfaces. Then, scale those surfaces. Next, examine and scale the lingual and proximal surfaces. After you have completed the mandibular anterior teeth, follow the routine until the entire dentition (all teeth) has been examined and scaled.

## CALCULUS REMOVAL

Dental Technicians are only allowed to remove **supragingival calculus**. Supragingival calculus is defined as calculus **above the gumline**. Subgingival calculus removal and root planing are only to be performed by a dentist or dental hygienist. Figure 3-21 illustrates subgingival and supragingival calculus.

Scaling the teeth removes calculus by mechanically fracturing the deposits off each tooth. It is relatively simple to remove large deposits of supragingival calculus, but removing the smaller pieces that are left behind when the larger pieces fracture off takes practice to ensure the tooth surface is calculus-free.

Supragingival calculus may be detected visually. It will appear as a white, chalky, or yellow deposit on the tooth surface. Drying the tooth surface with air from the three-way syringe will make a deposit easier to see.

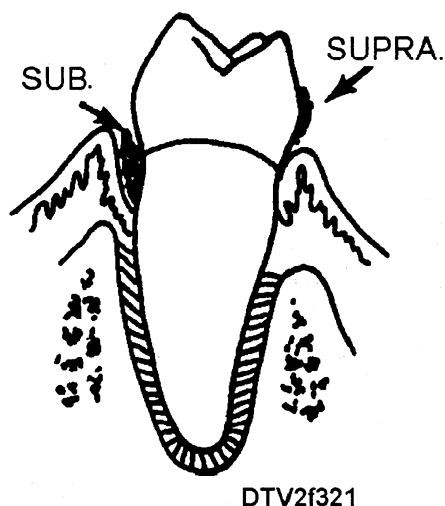


Figure 3-21.—Subgingival and supragingival calculus.

You can also detect supragingival calculus by passing the point of an explorer over the teeth. Enamel will feel hard and smooth as the explorer tip passes freely over it. Calculus feels rough and will interfere with the free movement of the explorer tip. The easiest way to detect supragingival calculus is by using a disclosing agent. This will enable you to visually identify stained areas of plaque and calculus.

## SCALING INSTRUMENTS

Your choice of an instrument is determined primarily by the amount of calculus present. If the patient has a large amount of supragingival calculus or heavy stain, you may want to start your scaling procedure with the ultrasonic or sonic instrument. After you have removed the calculus or heavy stain, you then can use the various hand instruments to remove the remaining deposits. If the patient has a light to moderate accumulation of supragingival calculus, you may choose to complete the entire procedure with hand instruments.

## INSTRUMENTATION

After you have located the calculus deposits, you are ready to perform the instrumentation necessary to remove them. There are four basic scaling strokes: exploratory, vertical, horizontal, and oblique.

### Exploratory Stroke

The exploratory stroke is used to determine the general outline of the deposits. To perform the exploratory stroke, hold the scaler or curette lightly in a modified pen grasp. Holding the instrument lightly will increase your sense of touch. Establish a finger rest, then move the cutting edge of the blade across the tooth surface toward the gingiva. When you feel the calculus, continue moving the blade until the cutting edge reaches the border of the deposit. **Do not** insert the blade below the gingiva. Position the cutting edge of the instrument next to the border of the calculus deposit (fig. 3-22). You are now ready to change to a vertical, horizontal, or oblique scaling or working stroke (fig. 3-23) depending on the location of the calculus.

### Vertical Stroke

The vertical stroke parallels the long axis of the tooth. Use this stroke to remove calculus from the proximal surfaces of the teeth. It is considered the

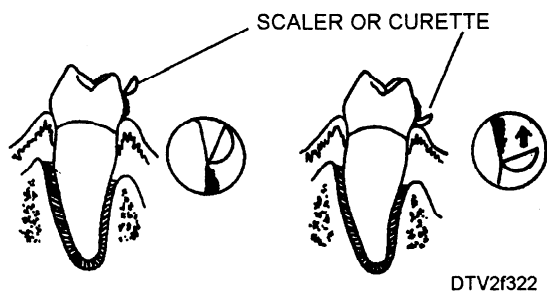


Figure 3-22.—Exploratory stroke.

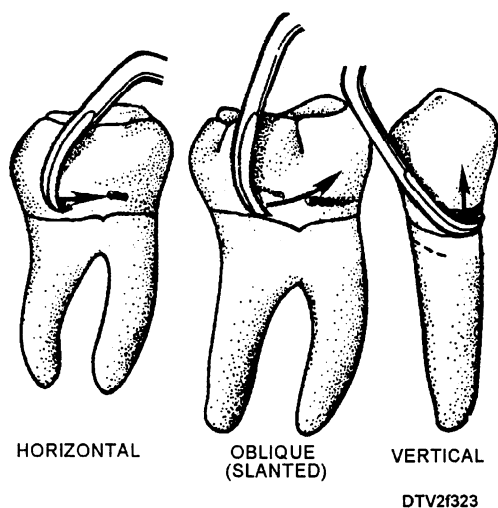


Figure 3-23.—Scaling strokes.

safest scaling stroke because the cutting edge of the instrument does not come in contact with the epithelial attachment.

### Horizontal Stroke

The horizontal stroke will parallel the gingival margin. Use this stroke cautiously to remove supragingival deposits from the facial and lingual surfaces of the teeth.

### Oblique Stroke

The oblique or slanted stroke is made at a 45° angle to the long axis of the tooth. Use this stroke to scale the majority of the tooth's surfaces. However, the direction of the stroke that you select will depend on the type of instrument, the area of the mouth, and the tooth surface involved.

### Activating the Stroke

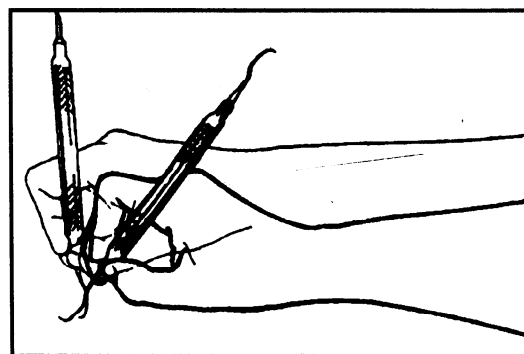
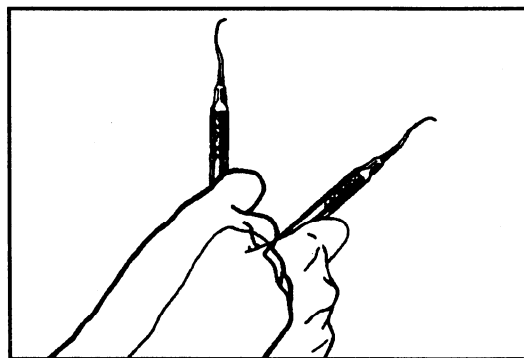
Before starting the working phase of the stroke, tighten your grip on the instrument. Use your hand,

wrist, and arm to activate the instrument (fig. 3-24). Avoid scaling with independent finger movements as this technique is extremely fatiguing. Your working stroke should be short, controlled, decisive, and directed in a manner to protect the tissues from trauma. With a short stroke, you can maintain control of the instrument and adapt the cutting edge to variations in the tooth surface. Always keep as much of the working blade (not just the point) on the tooth as possible. The exact length of the stroke depends on the height of the deposits. During the working stroke, you should slightly increase the pressure on the fulcrum to balance the pressure of the instrument on the tooth.

**Never** remove calculus by shaving it in layers. Shaving often leaves a thin layer of calculus, which is difficult to distinguish from the tooth surface. This thin layer can serve as a nucleus for new plaque and calculus formation. After you have completed the scaling procedure, you are ready to polish the teeth.

## POLISHING TEETH

The current treatment plan in the patient dental record will indicate whether or not a tooth polishing should be done. However, if the gingiva has been irritated during scaling, you may have to schedule the Polishing Procedure for a later date. Have a dental



DTV2f324

Figure 3-24.—Instrument activation.

officer evaluate the tissue condition if any questions exist.

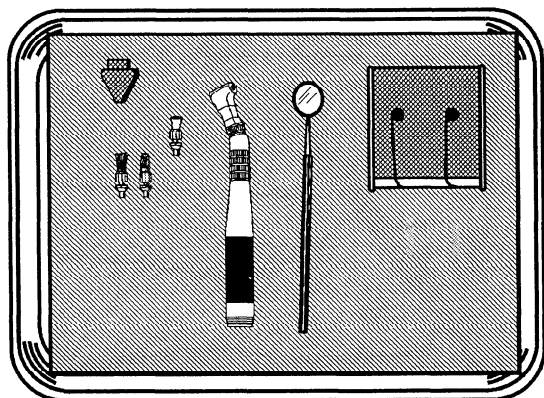
Tooth polishing removes plaque or stains remaining on the teeth after thorough scaling. Improper use of a prophy cup and abrasive paste can have harmful effects on the teeth including: loss of tooth structure, removal of fluoride-rich surface enamel, thermal injury to the pulp, and trauma to soft tissues.

## Materials and Equipment

A typical tooth polishing setup (fig. 3-25) includes a mouth mirror, slow-speed handpiece with a prophylaxis angle attachment, rubber polishing cup, tapered bristle brush, dental floss, and prophylaxis paste.

Many different types of prophylaxis (sometimes abbreviated as "prophy") angle attachments are available. Disposable or single-use prophy angles are recommended; however, sterilizable prophy angles are equally effective, can be more economical, and are widely used in the Navy. There are latch and screw-type rubber polishing cups. Ensure that the prophy angle and the type of rubber cup you select are compatible. Follow the manufacturer's instructions for use and maintenance of handpiece and prophy attachments.

The use of single-unit prophylaxis paste prevents waste and cross contamination. Commercially prepared pastes containing fluoride are commonly used in the Navy and are available in popular flavors. Pastes are also available in fine, medium, coarse, and coarse grits. Select the abrasiveness appropriate for removal of the stains present. A fine paste will not efficiently remove heavy stain. A coarse paste will



DTV2f325

Figure 3-25.—Tooth polishing setup.

needlessly remove enamel when treating fine stains. A tapered bristle brush may be used to polish the occlusal surfaces of the teeth.

## Precautions

You must be careful when you use the handpiece and prophylaxis attachment. Neither a polishing cup nor bristle brush should contact soft tissue. Such contact could injure the tissue. Only use the bristle brush on occlusal surfaces of teeth, well away from the soft tissue.

You must also be careful to avoid friction between the cup or brush and the tooth. Friction causes heat, and heat can harm the tooth pulp and cause pain to the patient. For this reason, always run the handpiece at the **slowest** of the slow speeds. The speed of the handpiece is controlled by a foot-operated rheostat. Use firm pressure when applying the rubber cup to the surface that needs polishing. You will know that you have applied sufficient pressure when you see the cup's edge flare slightly. Don't bounce the cup on and off the tooth. Keep the cup in **constant** motion while in contact with the tooth. To avoid splattering paste, bring the cup almost in contact with the tooth before the cup starts turning. Follow all safety precautions. You should always wear protective gloves, glasses, and mask. Drape the patient to protect his or her clothing.

## Polishing Routine

You should polish the patient's teeth according to a definite sequence. A typical sequence would start with the maxillary arch and polish the teeth as follows:

- All facial surfaces—from the right quadrant to the left quadrant.
- All lingual surfaces—from the left quadrant to the right quadrant.
- All occlusal surfaces—from the right quadrant to the left quadrant.

As you polish, begin at the gingival margin of the tooth and work toward the occlusal or incisal edge, using vertical or oblique pulling strokes. Rinse the working area with water from the three-way syringe as needed and have the patient use the saliva ejector to remove the debris from the mouth.

You may not be able to reach all of the interproximal areas with the polishing cup. To polish these areas, place the polishing paste in the facial and

lingual embrasures and carry it into the interproximal space with dental floss or dental tape.

At the end of the polishing, carefully floss the patient's teeth. This is an excellent opportunity to begin your oral hygiene instruction. Have the patient watch you with a hand-held mirror. When flossing is complete, rinse and remove any debris remaining in the mouth. Once the teeth have been cleaned of plaque and calculus, topical fluoride can be applied professionally if the procedure is indicated in the current treatment plan.

### **Fluoride Application**

Topical fluoride can be administered by three different methods. The first method involves the application of fluoride solution. This type of fluoride must be painted on the teeth with a cotton tip applicator. The second method of fluoride application is the use of a concentrated fluoride rinse. The third method is the tray technique, which is used to apply fluoride gels. Gel application is generally regarded as the most effective means of topical fluoride treatment. We will focus our attention on fluoride gel application.

A variety of trays are available for fluoride gel application. The use of disposable trays reduces the chance of cross contamination and eliminates the need to clean and sterilize reusable ones. Trays come in several arch sizes to ensure optimal fit for each patient. The tray should provide complete coverage of all erupted teeth without going beyond the most distal tooth surface in the arch. Custom-fitted trays can be made that require less gel and promote contact of the gel with the teeth. The extra time and expense of custom fluoride tray fabrication will limit the use to specific patients who require daily application of fluoride gel.

Reexamine the mouth to estimate the size of the dental arches and identify any features such as malposed teeth or bony tori that will influence tray selection. Select a maxillary tray and try it into the patient's mouth. Make sure all teeth will be contacted by the gel. Remove it and do the same for the mandibular arch. Refer to the manufacturer's instructions for the amount of gel required for each tray. A narrow strip of material along the bottom of the tray is normally adequate. This technique will minimize the amount of gel required and will reduce the chance that excess gel will be swallowed by the patient. The patient's teeth must be dried and kept as dry as possible until trays are inserted. Dry each arch

separately before placing the tray into the patient's mouth.

First place the mandibular tray. Retract a corner of the mouth with your finger. Insert one end of the tray in the mouth at an angle and then rotate the other end of the tray into the mouth. Insert the saliva ejector before placing the maxillary tray. Place the maxillary tray in a similar fashion and ask your patient to close his or her teeth together gently. Refer to the manufacturer's instructions for the amount of time the gel remains in the mouth. Generally, application is no longer than 4 minutes. After the trays have been removed, allow your patient to expectorate (spit) any remaining fluoride from the mouth. Instruct the patient not to rinse, drink, eat, or smoke for at least 30 minutes.

## **ORAL HYGIENE INSTRUCTIONS**

A vital part of any preventive dentistry program is the education and motivation of patients in proper oral hygiene. During the appointment you must take the time to explain the harmful effects of bacterial plaque and demonstrate proper tooth brushing and flossing techniques. It is recommended that you review *Dental Technician*, Volume 1, chapter 5, "Oral Pathology," and chapter 8, "Nutrition and Diet," as this information also plays an important role in oral hygiene.

### **INSTRUCTION ATMOSPHERE**

The atmosphere you create for your oral hygiene instruction will influence your ability to communicate with the patient. Position yourself in front of the patient so that you can look directly into the eyes and observe the patient's responses to your instructions. You may want to repeat or clarify points that the patient's response suggests he or she does not understand or if the patient questions what you have said. In most cases, sitting on the dental stool and facing the patient from the front is a good instructional position. This position allows you to view the patient's facial expression. Being at the same eye level as the patient also helps you establish rapport, since you are not talking "down" to them.

Talk directly to your patient and smile occasionally. If you stare at the wall or some other inanimate object during your presentation, the patient will get the impression that you are not sincere or interested. Use simple words, and explain any scientific or technical terms with which the patient may not be familiar. Your patient may not know that

"gingiva" is the technical term for "gums," and they might think "calculus" is a form of mathematics. Use simple layman terms.

The use of visual aids, such as charts and patient literature, can help illustrate the progression of dental disease or effective hygiene techniques and reinforce your discussion with the patient. The use of a disclosing agent can increase the impact of your instruction on the patient. By using this agent before the appointment, you can actually show the patient the areas that he or she missed during the cleansing technique. Remember your job is not to chastise the patient for past neglect, but to educate and encourage improvement in oral hygiene.

## HOME CARE

Home care is NOT limited to the home. Let your patients know that they can keep extra toothbrushes and dental floss at work. The difference between oral hygiene and dental disease is not toothbrushing, but mouth cleansing. Everybody brushes their teeth, but the goal is to thoroughly clean the mouth.

One of the major causes of tooth decay and periodontal disease is bacterial plaque. Bacterial plaque is an almost invisible film of water, containing cells and millions of living bacteria. To prevent dental diseases, you must effectively remove this destructive film **at least once** during a 24-hour period. By keeping your teeth and gums clean, you will have better health, retain your natural appearance, enjoy chewing and talking, and prevent bad breath.

## EFFECTIVE TOOTHBRUSHING

The toothbrush can remove the bacterial film from the facial, lingual, and occlusal surfaces of the teeth. Brush gently but with enough pressure to feel the bristles on the gum. Do not use so much pressure that you feel discomfort. The method we will describe here, the "**Modified Bass**" technique, is effective and relatively easy for most patients to perform. Sometimes other methods are recommended in special situations, such as malocclusion.

Toothpaste foams and prevents you from seeing if you are placing the brush properly. While a person is learning to brush properly, it is best to omit toothpaste or use it in a second brushing.

Your toothbrush should have soft, multitufted nylon bristles. It should have a rigid plastic handle and a small and flat head.

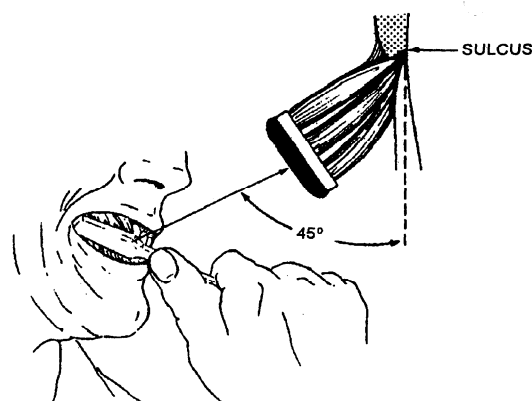
- For all facial surfaces and the posterior lingual surfaces, point the bristles at the teeth at a 45° angle. Lay the bristles in the sulcus area and use a gentle vibrating motion (fig. 3-26).

- For the lingual surfaces of the anterior teeth, place the brush as shown in figure 3-27 and use small circular scrubbing strokes.

- When brushing the occlusal surfaces, place the bristles flat on the surface and use the same scrubbing strokes as for the other surfaces (fig. 3-28). Move the bristles around the mouth in a regular pattern so as not to skip any areas.

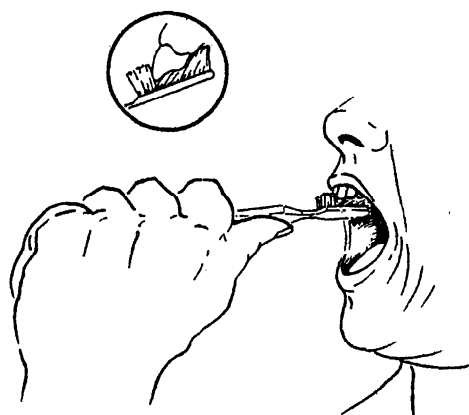
## ELECTRIC TOOTHBRUSHES

Many electric toothbrushes are accepted by the American Dental Association (ADA) and have earned its seal of approval. Always follow the manufacturer's instructions on the use and maintenance of these products.



DTV2I326

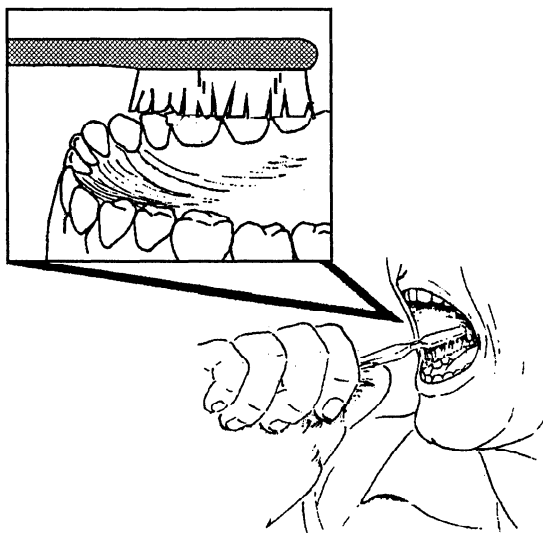
Figure 3-26.—Brushing the sulcus area.



DTV2I327

Figure 3-27.—Brushing the lingual surfaces of anterior teeth.





DTV2f328

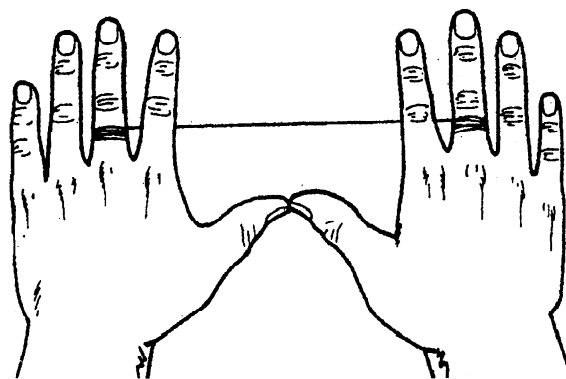
Figure 3-28.—Brushing the occlusal surfaces.

## USE OF DENTAL FLOSS

For most people, dental decay and periodontal disease most often occur between or on the proximal surfaces of teeth. The toothbrush cannot clean these areas effectively or clean behind the last tooth in each arch. Dental floss is best for cleaning these areas. Both waxed and unwaxed floss clean equally effectively. However, a patient with very tight interproximal contact areas may find waxed floss is easier to use. Patients who have suffered a loss of interproximal tissues may use dental tape.

When patients are first learning to floss, they may find it difficult to accomplish. You should assure them that with practice, flossing will become easier. In addition, some patients may feel discomfort and have bleeding around the gingiva the first few times they floss. Assure them that the discomfort and bleeding will go away in a day or two. To ease the discomfort, you may recommend that such patients should use a warm salt water rinse after flossing.

To properly floss, cut off a piece of floss about 18 inches long and lightly wrap the ends of the floss around your middle finger, as shown in figure 3-29. The fingers controlling the floss should not be more than one-half inch apart. Do not force the floss between the teeth. Insert it gently by sawing it back and forth at the point where the teeth touch each other. Let it slide gently into place. With both fingers, move the floss up and down on the side of one tooth, and then repeat on the side of the other tooth until the surfaces



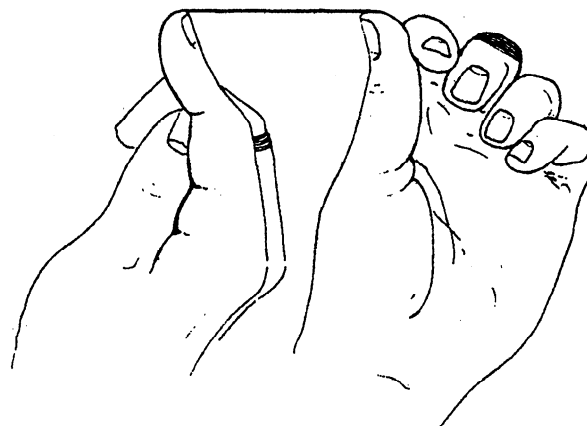
DTV2f329

Figure 3-29.—Floss wrapped around middle fingers.

are "squeaky" clean. Use your fingers to curve or bend the floss around the tooth. Go carefully under the gum line with the floss since this is a sulcus where plaque collects. Slide the floss down until you feel resistance, but do not go far enough into the gum to cause discomfort, soreness, or cut the gum tissue that will cause bleeding. When the floss becomes frayed or soiled, a turn from one middle finger to the other brings up a fresh section.

- To clean between the upper **left** back teeth, pass the floss over your thumb and forefinger of your right hand (fig. 3-30). To see the proper position of the hands, look at figure 3-31. The thumb is placed on the outside of the teeth and helps hold the cheek back.

- To clean between the upper **right** teeth, pass the floss over your right thumb and forefinger on your left hand. Now the right thumb is outside the teeth and the left forefinger is on the inside.



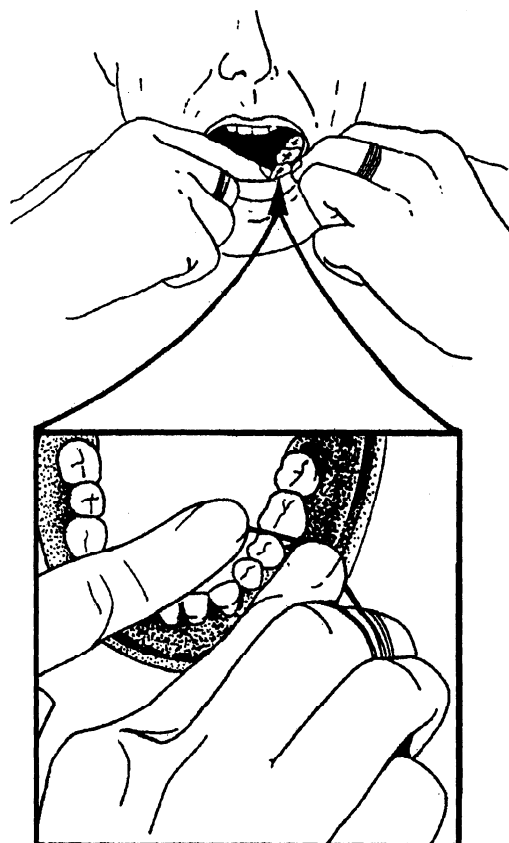
DTV2f330

Figure 3-30.—Floss position for the maxillary posterior teeth.



DTV2f331

Figure 3-31.—Hand position for flossing maxillary posterior teeth.



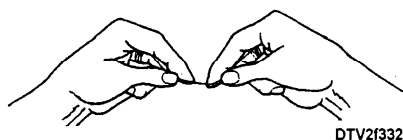
DTV2f333

Figure 3-33.—Hand position for flossing mandibular posterior teeth.

- To clean between all lower teeth, hold the floss with the forefingers of both hands (fig. 3-32). You can insert the floss gently between all lower teeth with the floss over your forefingers in this position. Figure 3-33 illustrates the correct method for flossing between the lower back teeth, using the two forefingers to guide the floss.

### EVALUATION

Are your patient's teeth clean? When flossing has been completed, rinse vigorously with water to remove food particles and plaque. Also advise the patient to rinse with water after eating if unable to floss or brush. Neither rinsing alone nor water-spraying devices remove the bacterial plaque because of the glue-like



DTV2f332

Figure 3-32.—Floss position for the mandibular teeth.

material in the plaque. To ensure all areas of the teeth are clean, a disclosing agent can be used to determine if any surfaces on the teeth were missed during flossing.

### SENSITIVITY

After treatment of the teeth or gums, the exposed root surfaces may be sensitive to cold and heat. This condition is usually temporary if the teeth are kept clean. If the teeth are not kept clean, the sensitivity may remain and become more severe. For the few patients who have severe sensitivity, the use of specially medicated toothpastes and mouthwashes may be recommended.

### DENTIFRICE

Although dentifrices (toothpaste) are **not** necessary for effective cleaning of the teeth, they may be refreshing for the patient and have a psychological benefit. Instruct your patients that if they wish to use a dentifrice, they should select a fluoridated toothpaste displaying the ADA seal of approval.

## MAINTENANCE OF PROSTHETIC APPLIANCES

If your patient has a prosthetic appliance, tell him or her to take the removable appliance out of the mouth after meals and thoroughly brush it. Patients should use a good prosthetic appliance brush and their preferred dentifrice or soap and water. Have the patient follow the dentist's instructions regarding how long to leave the appliance out of the mouth while sleeping to give the tissues proper rest and how to take care of the appliance when it is not worn.

Plaque accumulates on the surfaces of abutments and beneath the pontics of fixed partial dentures (bridges). **Floss threaders** are thin plastic devices that help the patient direct the floss into these areas. Fixed partial dentures should also be cleaned at least once daily.

## ORAL HYGIENE AIDS

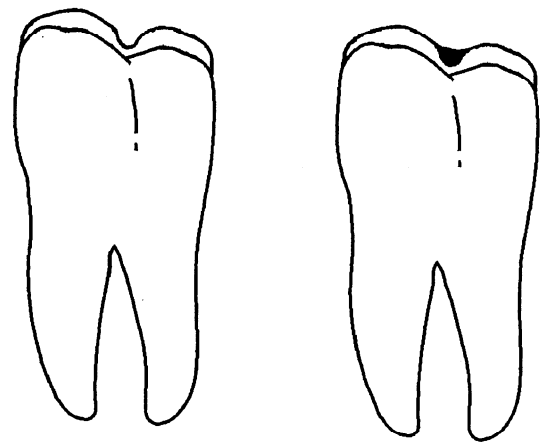
Toothpicks, interdental proximal brushes, oral irrigators, and mouthwashes are aids to oral hygiene. They may be used in addition to, but not in place of, tooth brushing and flossing. These products will be recommended by a dentist or dental hygienist and should bear the ADA seal of approval.

## APPLICATION OF PIT AND FISSURE SEALANTS

A pit and fissure sealant is a plastic resin-like material that is applied to the tooth surface and hardened. The plastic resin bonds into the depressions and grooves (pits and fissures) of the chewing surfaces of back teeth. Sealants are highly effective in preventing pit and fissure caries in premolars and molars. The sealant acts as a barrier protecting enamel from plaque and acids. Figure 3-34 illustrates a before and after drawing of a sealant on a tooth. Acid-etch resin sealants are classified into three types, based on the method by which they are cured (hardened):

- Ultraviolet light-cured
- Chemically or self-cured
- Visible light-cured

As a basic dental assistant, you may receive training in expanded functions to place pit and fissure sealants as described in BUMEDINST 6600.13. Check with your command on certification requirements. Pit and fissure sealants may only be placed by certified personnel. Only a dental officer can



BEFORE SEALANT

AFTER SEALANT

DTV2f334

Figure 3-34.—Before and after applying a sealant on a tooth.

authorize and recommend what teeth require sealants. This will be noted on the patient's treatment plan.

The following clinical guidelines should be followed for successful sealant application:

- Ensure the patient's treatment plan indicates what teeth require sealants.
- Ensure the proper eye and clothing protection are in place for you and the patient.
- The teeth must be isolated to prevent saliva contamination of the surfaces to be sealed. The isolation must provide adequate access to observe the field and to reach the tooth surfaces with the appropriate instruments. A rubber dam is the preferred method of isolation, but if a rubber dam cannot be used, cotton roll isolation can be effective.
- The tooth surfaces should be cleaned with a prophylaxis brush or rubber cup and a cleansing agent containing no oil or other substance that cannot be completely and quickly washed away using an air/water syringe with high-speed evacuation.
- When the teeth are effectively isolated from saliva contamination, the tooth surfaces are dried and then etched by an application of a 30 to 50 percent phosphoric acid solution for 15 to 20 seconds. Etching should cover all the areas to be sealed.
- The acid should be washed away with water. The surfaces are then carefully re-dried and inspected to ensure that the area intended for sealant has a "frosted" appearance. The **absolute** avoidance of contamination with saliva or air-line moisture or oil is critical from the time of acid removal and drying, until the sealant is

cured. If contamination is suspected, re-etching of the surface for 20 seconds is indicated.

- The sealant should be applied according to the manufacturer's instructions. Care should be taken to avoid entrapment of air bubbles, to extend the sealant into all the grooves and pits, and to avoid extension of the sealant onto unetched smooth surfaces or soft tissues. The sealant must remain uncontaminated and undisturbed until it is cured to hardness.

- The sealant should be examined by yourself first, and then checked by a dentist to ensure that

underextension, overextension, undercuring, voids, and high spots have not occurred. A reasonable attempt should be made to remove the sealant to determine if adequate bond strength has been established.

Fluoride should not be applied to the enamel surface immediately before a sealant procedure is initiated. Fluoride may be applied immediately after sealant application.

The most common reason for sealant failure is contamination of the etched surface with saliva or air-line moisture (from the air syringe) or oil.

## CHAPTER 4

# OPERATIVE DENTISTRY

### INTRODUCTION

Operative dentistry is the area of dental practice concerned with the prevention and treatment of defects in tooth enamel and dentin. Since many patients need treatment that is provided in operative dentistry, this is where most of the dental assistants are assigned. Operative dentistry includes the treatment and restoration of carious teeth with metallic and nonmetallic dental materials. These materials are usually amalgam, composite resins, and glass ionomer restorations.

### PURPOSE

Operative dentistry provides treatment to restore a patient's dental condition to a healthy, functional, and esthetically (pleasing to the eye) acceptable level. Operative dentistry primarily is responsible for the restoration of decayed or fractured teeth. This chapter provides information and procedures that you may be required to perform in operative dentistry.

### AREAS OF OPERATIVE DENTISTRY

You must be aware that each operative procedure may not be performed in the same manner. Basic procedures are usually performed during each operative appointment. Some of these procedures are also used in other dental specialties. The areas discussed in this chapter are as follows:

- Identification of operative instruments
- Miscellaneous instruments, materials, and equipment
- Four-handed dentistry
- Basic dental procedures
- Operative procedures
- Supply procedures

### IDENTIFICATION OF OPERATIVE INSTRUMENTS

Because of the many hard to reach areas in the human mouth and various functions required,

operative instruments come in a wide variety of sizes and shapes. To be an effective dental assistant, you must be able to understand why, where, and when the dentist will use them. We will discuss hand cutting instruments, amalgam instruments that consist of condensers, carvers and burnishers, and composite (resin) instruments.

### HAND CUTTING INSTRUMENTS

Many dental procedures require the use of hand instruments with sharp cutting edges. This cutting instrument group used in operative dentistry includes excavators, chisels, hatchets, hoes, and gingival margin trimmers. They are used in the cavity preparation of both amalgam and composite (resin) restorations.

#### Spoon Excavators

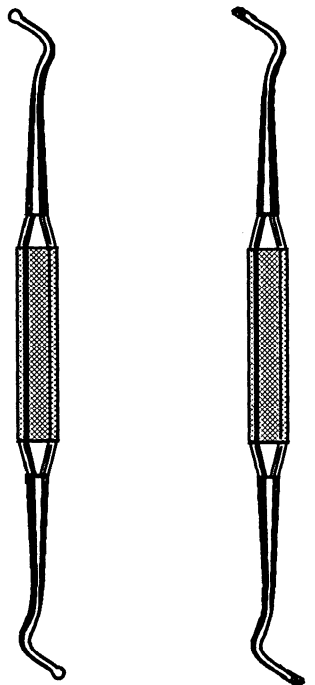
The spoon excavator is a double-ended instrument with a spoon, claw, or disk-shaped blade. Spoon excavators are used primarily to remove debris from tooth cavities. Their tips and sides are designed for cutting action. The most common sizes are the small and the large (fig. 4-1) spoon extractors.

#### Chisels

Dental chisels are commonly referred to as miniature chisels. Chisels are used to cleave (split) tooth enamel, to smooth cavity walls, and to sharpen cavity preparations. The two most common types used in operative dentistry are the Wedelstaedt and biangle chisels (fig. 4-2). The Wedelstaedts have slightly curved shanks and are used primarily on anterior teeth. The biangle chisels have two distinct angles—one at the shank, and one at the working end. This design allows access to tooth structures that would not be possible with straight chisels.

#### Hatchets

A dental hatchet (fig. 4-3) resembles a camper's hatchet, except much smaller. Like dental chisels, some have single cutting ends, and others have cutting edges on both ends of the handle. Hatchet blades are set

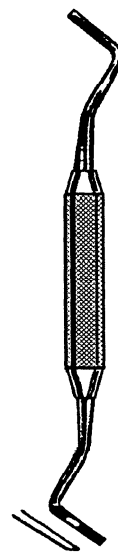


SMALL

LARGE

DTV2f401

Figure 4-1.—Small and large spoon excavators.



DTV2f403

Figure 4-3.—Hatchet.

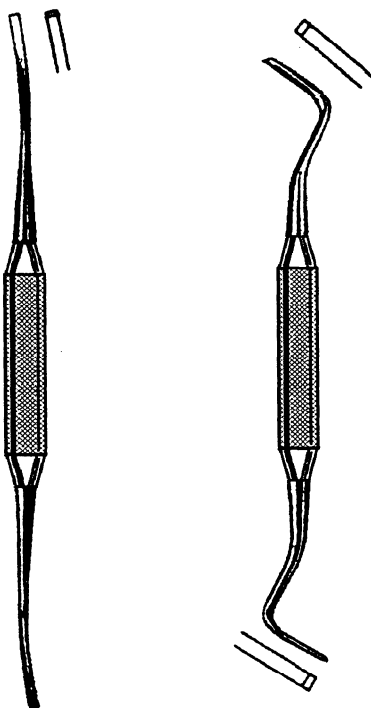
at a 45- to 90-degree angle from the shank. These instruments have different lengths and widths of blades. Hatchets are used on the wall of the cavity preparation to cleave enamel and cut dentin so there will be a sharp cavity outline.

### Hoes

Dental hoes (fig. 4-4) look like a miniature garden hoe. They are used with a pulling motion to smooth and shape the floor and sides of cavity preparations. Hoe blades are set at a 45- to 90-degree angle from their handle.

### Gingival Margin Trimmers (GMTs)

The gingival margin trimmers (GMTs) (fig. 4-5) are modified hatchets that have working ends with opposite curvatures and bevels. As the name implies, GMTs are used to trim, smooth, and shape the gingival floor of a cavity preparation. GMTs are available in double-ended styles and are used in pairs, such as the #26 and #27. This is because the working ends of the even-numbered instruments are designed for use on the **distal surfaces**, and the odd numbered are used on the **mesial surfaces**.



WEDELSTAEDTS

BIANGLE

DTV2f402

Figure 4-2.—Wedelstaedt and biangle chisels.

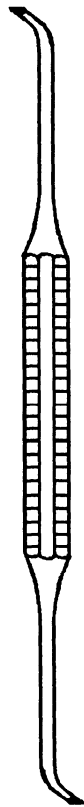
### AMALGAM RESTORATION INSTRUMENTS

The instruments discussed in this section are used when the dentist elects to use an amalgam or a temporary dental material to restore a tooth.

## Condensing Instruments

To deliver the amalgam to the cavity preparation and properly condense (pack) it, the dentist will use a variety of instruments. Amalgam carriers and condensers are used for this purpose.

**AMALGAM CARRIERS.**—Amalgam carriers (fig. 4-6) transport the freshly prepared amalgam restorative material to the cavity preparation. These carriers have hollow working ends, called barrels, into which the amalgam is packed for transportation. Both single and double-ended carriers are available with a variety of barrel sizes including: mini, large, and jumbo. When the lever (located on the top of the carrier) is depressed, the amalgam is ejected into the cavity preparation. Normally, two carriers are used during the amalgam placement procedure. This saves time for the dentist who is ejecting or condensing a carrier load while you are refilling the carriers. A poorly packed carrier of amalgam handed to the dentist may fall out before it is ejected into the cavity preparation. It is your responsibility to ensure that all carriers are properly packed before the transfer to the dentist. After amalgam material placement is completed, eject any remaining amalgam alloy from the carrier into the amalgam well. The carrier is no longer serviceable when the amalgam is allowed to harden in the carrier.



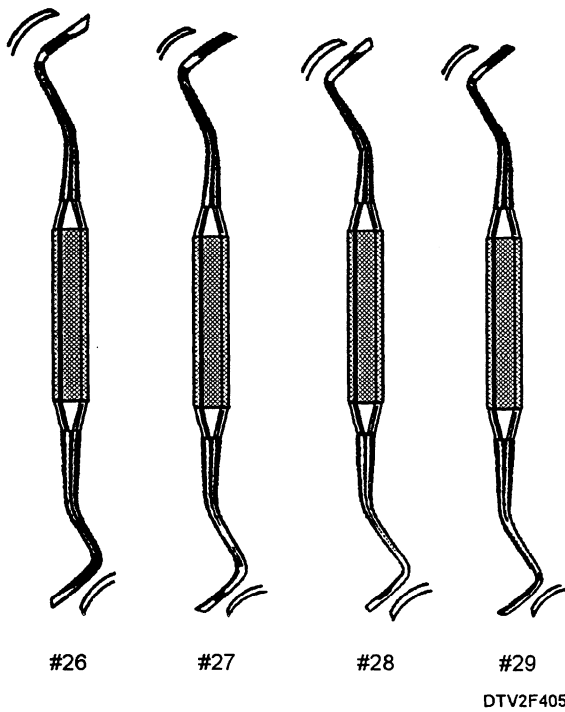
DTV2f404

Figure 4-4.—Hoe.

**CONDENSERS.**—Amalgam condensers, often called **pluggers**, are instruments used to condense or pack the amalgam filling materials into the cavity preparation. The hammer-like working end is large enough to compress the soft amalgam without sinking into it. Condensers come in single- and double-ended designs. They have various shaped and sized working ends, which may be smooth or serrated as shown in figure 4-7.

## Carvers

After the amalgam is condensed, it must then be carved to approximately the same original tooth structure. Carvers have sharp cutting edges that are used to shape, form, or cut tooth anatomy into amalgam restorations. Figure 4-8 illustrates these instruments that come in assorted shapes and sizes in double-ended designs. Many carvers were designed for carving specific tooth surfaces. The Interproximal and #1/2 Hollenback were designed for carving proximal (in between) tooth surfaces; whereas, the discoid-cleoid # 89/92 and Tanner #5 are used on occlusal surfaces. Carvers shaped similar to Vignon or Frahm #2/3 (also



#26

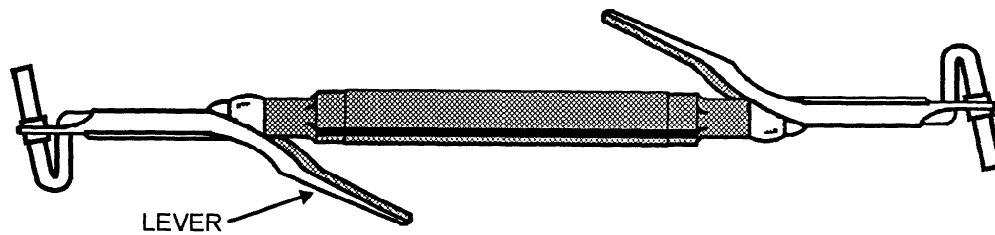
#27

#28

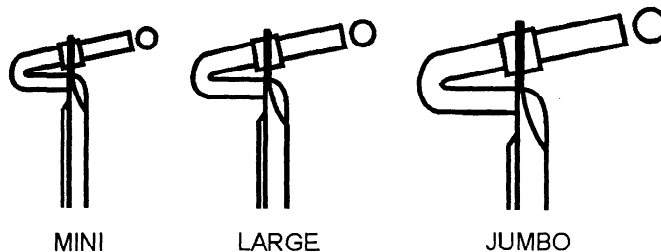
#29

DTV2F405

Figure 4-5.—Gingival margin trimmers (GMTs).

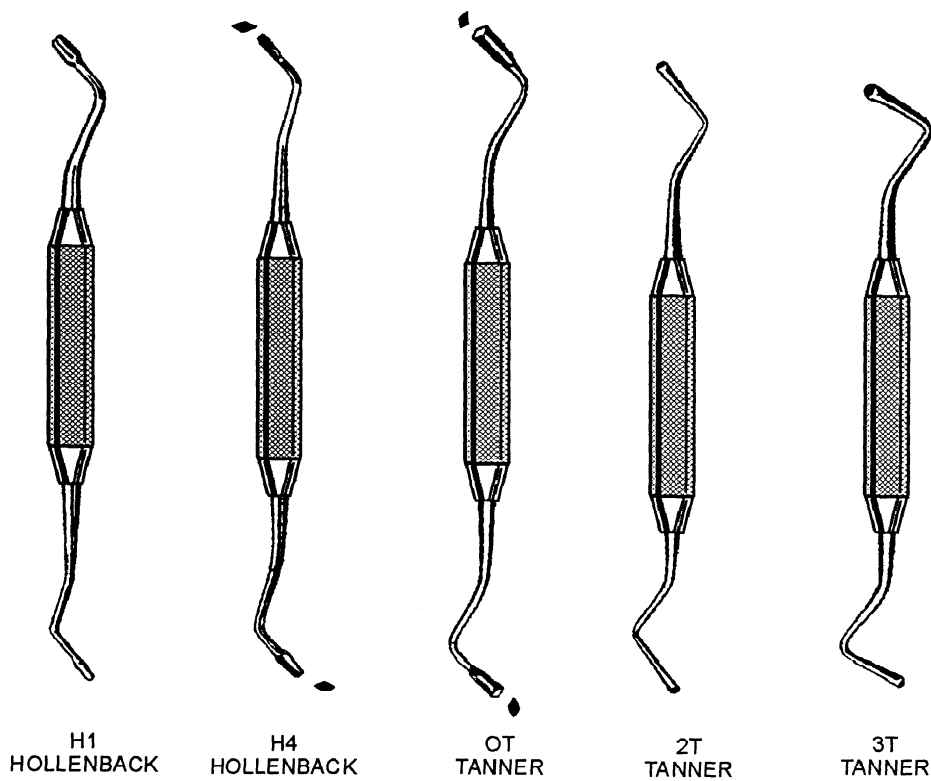


TIP SIZES FOR AMALGAM CARRIERS



DTV2f406

Figure 4-6.—Amalgam carriers.



DTV2f407

Figure 4-7.—Amalgam condensers.

called acorn carvers) are used to quickly carve the basic anatomy on occlusal surfaces. As with condensers, dentists also have favorite carvers that they use routinely. You must know the dentist's preference so that you can have the desired instrument ready when it is needed.

**Burnishers**

When the carving is complete, the dentist may use burnishers to smooth and polish the restoration, and to remove scratches left on the amalgam surface by a carving instrument. Burnishers have smooth rounded



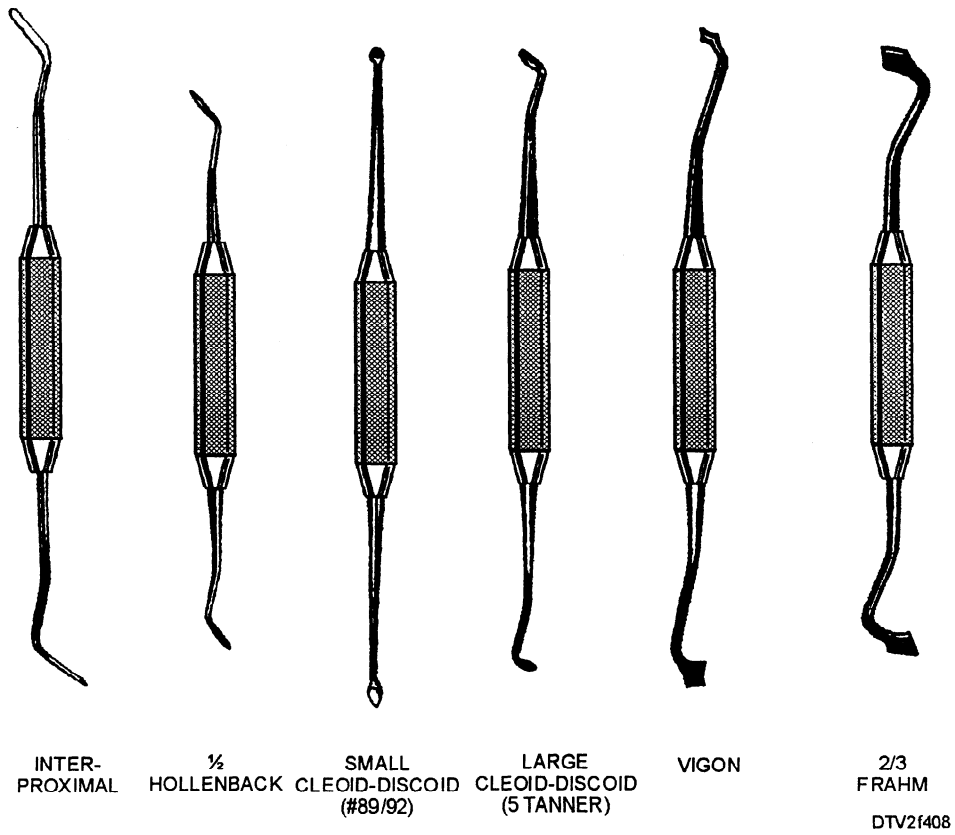


Figure 4-8.—Carvers.

working ends and come in single- and double-ended types. Some of the more commonly used burnishers are shown in figure 4-9.

**COMPOSITE RESIN INSTRUMENTS**

A variety of double-ended instruments make up this instrument group. They are used to transport and place dental cements, resins, temporaries, and insulating and pulp-capping materials. The working ends on composite resin instruments range from varying small cylinders to assorted angled, paddle-like shapes. Figure 4-10 illustrates the Woodson #3, #W3, and #11 (also know as Stellite), which are some of the commonly used instruments in this category.

Other types of composite resin instruments are made of plastic. Plastic instruments can be heat sterilized and used on composites and cements. They either come included in the kit of resin material from the manufacturer or, in some cases, can be ordered as a set as shown in figure 4-11. Some advantages to using plastic instruments are that they won't discolor or contaminate the composite restoration, and composite resin material will not cling to the instrument.

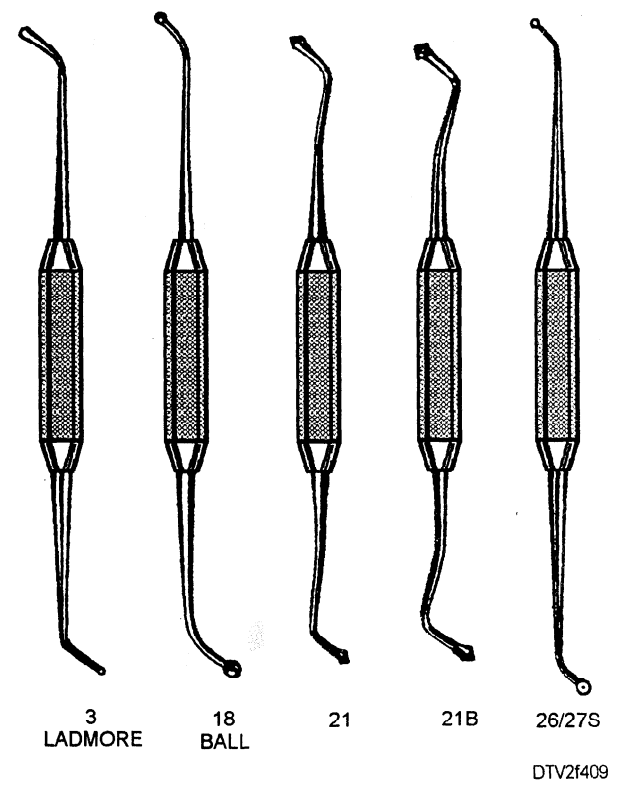


Figure 4-9.—Burnishers.

## CEMENT AND INSULATING BASE INSTRUMENTS

The instruments in this group are used for mixing and handling restorative resin, and various temporary restorative, insulating, and pulp-capping materials.

### Spatulas

Three different spatulas are available for mixing restorative materials, as shown in figure 4-13. Some of these spatulas can cause discoloration in the material being mixed. The selection of a mixing spatula is not critical **except** when preparing a permanent anterior composite restoration. Some composite restoration material discolors easily, so use the spatulas provided by the manufacturer when working with it. The single-ended #322 and #324 are suitable for mixing other materials other than composites. A smaller version for the #324 is the #313 spatula. The #313 is used for mixing small quantities of cement.

### Insulating Base Instruments

Insulating base instruments have a small metal ball at the working end and are often referred to as calcium hydroxide instruments. They are used to mix, carry, and place insulating bases, and are available as a

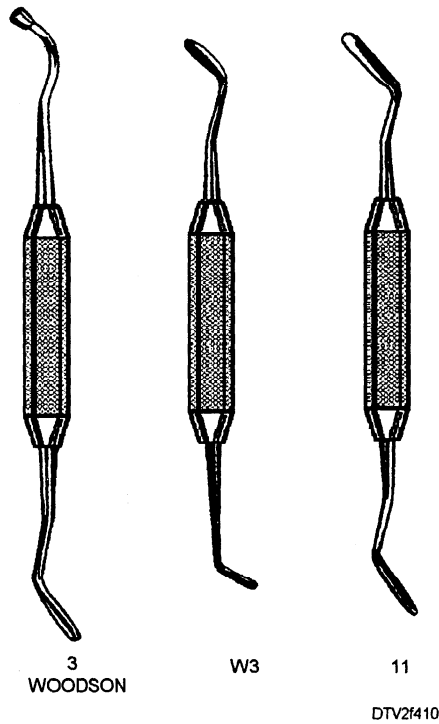


Figure 4-10.—Composite and cement instruments.




Figure 4-11.—Plastic composite instrument set.

Another instrument frequently used with etching and bonding procedures associated with composite resins is a disposable brush with a reusable handle. An example is shown in figure 4-12. Single-use disposal brushes are being used more frequently, aiding in good infection control practices.

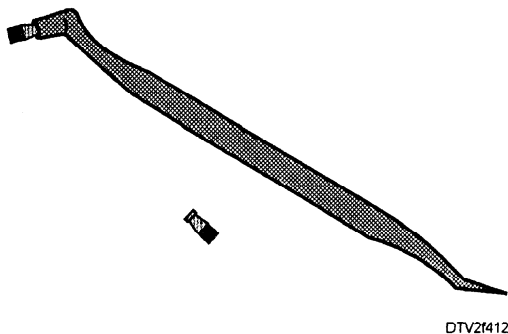


Figure 4-12.—Disposable brush and handle.

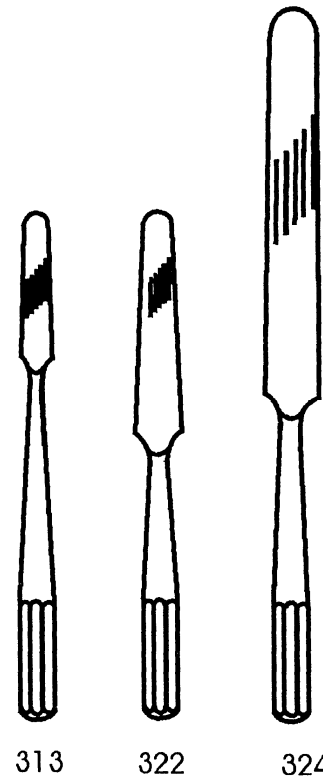


Figure 4-13.—Spatulas.


single-ended instrument or as a double-ended instrument, shown in figure 4-14.

## MISCELLANEOUS INSTRUMENTS, MATERIALS, AND EQUIPMENT

A number of miscellaneous instruments, materials, and equipment are used in operative dentistry. Instruments such as dental mirrors, explorers, and cotton forceps are called a basic dental set (BDS) and are usually used in all dental specialties.

### ASPIRATING SYRINGE

This syringe is used in dentistry to inject a local anesthetic. The aspirating syringe differs from most syringes in that it is designed to inject anesthetic from a carpule (fig. 4-15). The parts of an aspirating syringe consist of a threaded tip where the needle attaches, a barrel where the carpule is placed, a piston rod (plunger) with a harpoon attached that embeds itself into the rubber stopper of the carpule, a finger grip, and a thumb ring (fig 4-16). The harpoon allows the dentist to aspirate (draw back) the injection site to see if the needle tip is located in a blood vessel before injecting the anesthetic solution. Once the harpoon is engaged into the rubber stopper of the anesthetic carpule, the dentist can apply inward or outward pressure on the



DTV2414

Figure 4-14.—Double-ended calcium hydroxide instrument.



1-499

DTV2415

Figure 4-15.—Anesthetic carpule.

stopper by exerting pressure on the thumb ring. Pulling the thumb ring outward also pulls the plunger outward producing an aspirating effect; whereas, pushing inward forces the anesthetic solution through the needle.

### ASPIRATING SYRINGE NEEDLE

The aspirating syringe needles used in dental treatment arrive sterile and are disposable. They are designed for a single use, and are available in different gauges and lengths (fig. 4-17). The gauge of a needle refers to the diameter of the hollow shaft of the needle. The larger the gauge, the smaller in diameter the needle. The lengths of the needles vary, and are classified as long (L) or short (S).

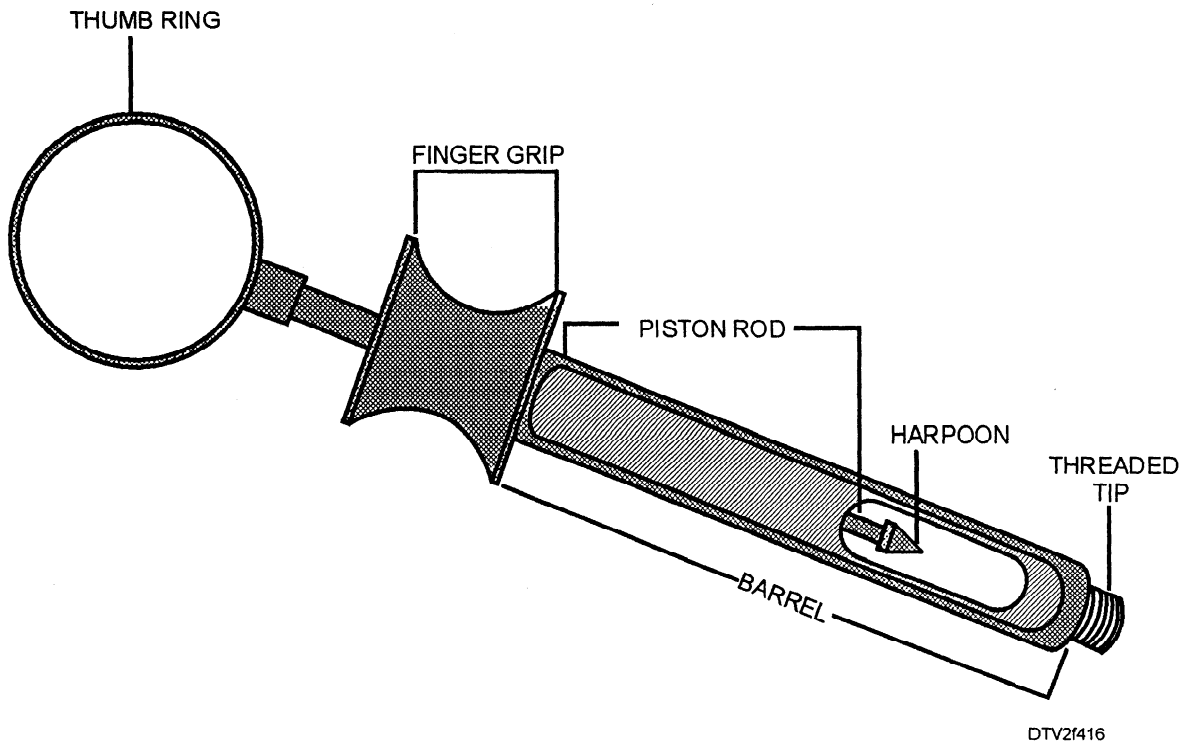
Each needle has either a plastic or metal hub designed to screw onto the threaded end of the syringe (fig. 4-18). This hub is positioned to permit the needle to extend inward to penetrate the rubber seal portion of a loaded anesthetic carpule.

The plastic caps covering the sterile needle are easily removed from both ends. When placing the needle onto the syringe, remove only the cap that covers the syringe end on the needle. This maintains the sterility of the needle portion used to inject the patient.

Normally, you prepare the anesthetic syringe with a short needle (13/16 inch in length) for maxillary injections, and a long needle (17/8 inches in length) for mandibular injections. The tip of the needle has a beveled angle, which is turned toward the alveolus to accurately deposit the solution.

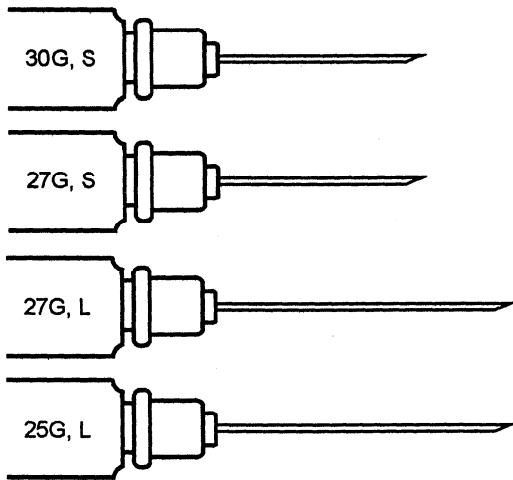
### RUBBER DAM INSTRUMENTS

Rubber dam instruments include the rubber dam punch, clamps, clamp forceps, and frame. These instruments prepare and maintain the position of thin sheets of latex rubber (rubber dam material). The rubber dam itself is used to isolate a designated tooth or teeth in the mouth before certain operative, endodontic and preventive dentistry procedures are performed. The rubber dam provides a clean, dry field of operation and improves the dentist's view of the operating site. It also keeps fluids, tissues, and the tongue away from the operating site and prevents the patient from accidentally swallowing or aspirating debris.



DTV2f416

Figure 4-16.—Parts of an aspirating syringe.

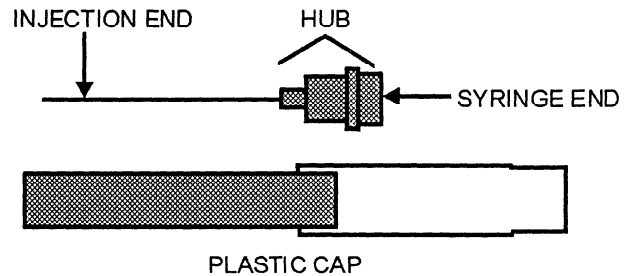


DTV2f417

Figure 4-17.—Different gauges and lengths of aspirating syringe needles.

### Rubber Dam Punch

The rubber dam punch is used to make necessary spaced holes in the rubber dam material. The working end is designed with a plunger on one side and a wheel on the other side (fig. 4-19). This wheel has different sized holes on the flat surface facing the plunger. These features let the operator select and adjust the



DTV2f418

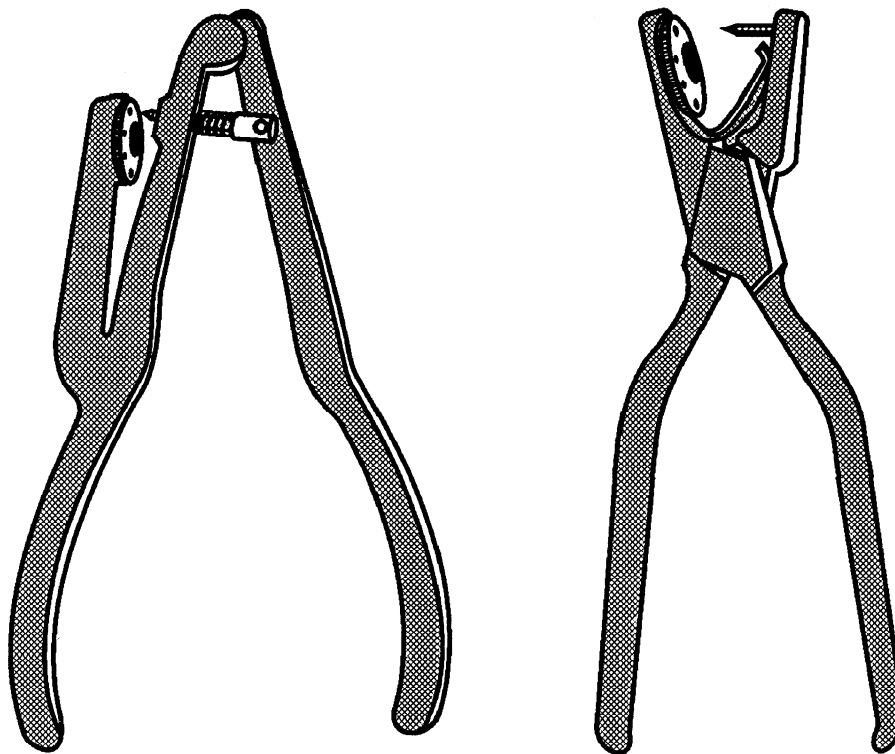
Figure 4-18.—Parts of the aspirating syringe needle.

wheel to punch the desired diameter hole in the rubber dam.

Figure 4-19 also illustrates the recommended holes on the wheel to use. The largest hole is used on the tooth that your clamp will go on. The last five remaining holes correspond to the teeth that are included in the isolation.

### Rubber Dam Clamps

After the required number of holes are punched in the rubber dam, it is stretched to fit over each designed tooth. To maintain a snug fit around the neck of the

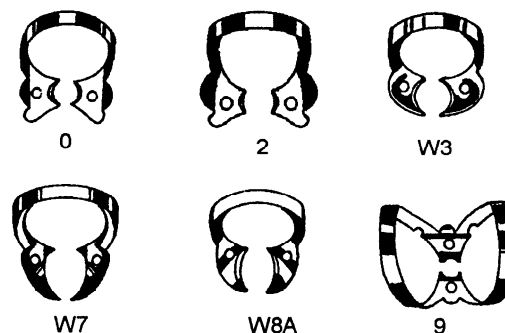


DTV2f419

Figure 4-19.—Two styles of rubber dam punches.

tooth, a rubber dam clamp is used. These clamps are made of spring steel in various sizes (fig. 4-20) to fit the general contours of the different teeth. You will need to know some of the commonly used clamps and their area of use, which are shown in table 4-1.

Clamps commonly used in pediatric dentistry include the #2, #4, #8A, and #14A. Clamps with "W" prefixes, such as the #W8A or W3, indicate that the clamps are **without wings** on the outer portions opposite the holes.



DTV2f420

Figure 4-20.—Rubber dam clamps.

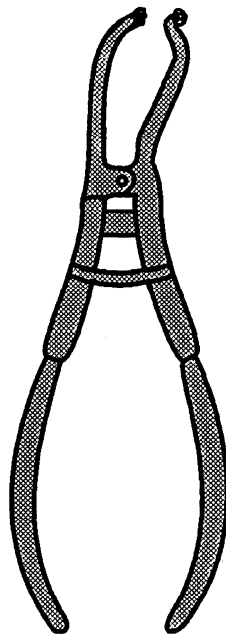
Table 4-1.—Commonly Used Rubber Dam Clamps and Their Area of Use

Clamp #	Area of use in the mouth
0	Primary teeth
2	Small bicuspid
W3	Bicuspid and small molars
7	Mandibular molars
W8A	Partially erupted molars
9	Anterior teeth
212	Anterior teeth

The space between the gripping edges of the clamp is narrower than the diameter of the corresponding tooth. Thus, to place the clamp around the tooth, it is necessary to spread the gripping edges wider than the tooth's diameter. To spread the gripping edges, rubber dam clamp forceps are used.

### Rubber Dam Forceps

The rubber dam clamp forceps (fig. 4-21) are designed to spread the two working ends of the forceps apart when the handles are squeezed together. The



DTV2f421

Figure 4-21.—Rubber dam clamp forceps.

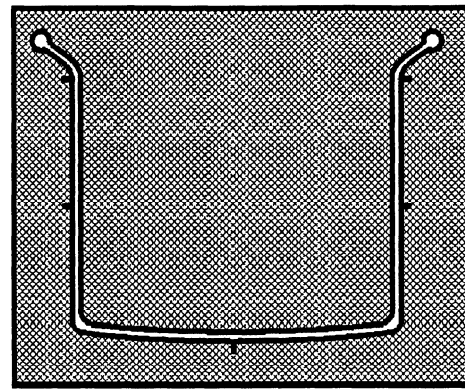
working ends have small projections that fit into two corresponding holes on the rubber dam clamps. The area between the working end and the handle has a sliding lock device. This sliding lock device locks the handles in positions while the provider moves the rubber dam clamp around the tooth.

### Rubber Dam Frame

To place and clamp a rubber dam around the tooth is not enough. The dentist still needs something to hold the loose outer edges of the rubber dam sheet so that the area is visible, and provides access to the tooth being treated. The need is met with an instrument called the rubber dam frame. Most of the rubber dam frames used today are U-shaped. One of the most popular is the Young frame, which is available in adult (fig. 4-22) and pediatric sizes. When the edges of the rubber dam are connected to the small, sharp projections on this U-frame, there is adequate access to, and visibility of the area of treatment.

### RUBBER DAM APPLICATION

The use of the rubber dam is an important part of quality dental treatment and infection control. To save valuable chairside time, place the rubber dam following the administration of local anesthetic (as directed by the dentist). To place the rubber dam, you



DTV2f422

Figure 4-22.—Adult rubber dam frame.

will need the rubber dam material, frame, punch, clamps, and clamp forceps.

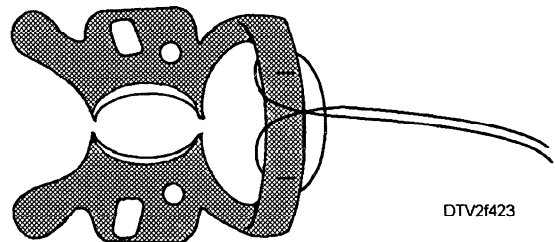
### Preparation

The first step in applying the rubber dam is to check the contact areas of the teeth to be isolated. Use a piece of dental floss to do this. The next step is to determine which tooth the rubber dam clamp will be placed upon. Once this is determined, select a rubber dam clamp for a trial placement.

### CAUTION

To prevent the patient from aspirating or swallowing the rubber dam clamp, always tie dental floss (ligature) on the bow of the clamp before placing it in the patient's mouth.

A simple and secure method is put both ends of a piece of floss together and place them on a flat surface. This forms a looped end where the floss is folded in half. Place the clamp over the floss with the bow of the clamp facing up. Now, place the two loose ends through the looped end and carefully pull the loose ends through the loop until the floss is secured tightly over the bow of the clamp (fig. 4-23). You should now



DTV2f423

Figure 4-23.—Ligature on rubber dam clamp.

have a securely placed ligature on the clamp. You are now ready to place the clamp on the rubber dam forceps.

Hold the clamp with the bow facing upward and away from the forceps. Place the small projections on the working ends of the rubber dam forceps into the corresponding holes on the rubber dam clamp. Squeeze the handles of the forceps together to align projections with the corresponding holes on the clamp. Once the clamp is placed on the forceps, tilt the forceps upright and slide the locking device on the forceps downward to lock the handles in position. Locking the forceps handles is necessary to continue the tension required to keep the clamp attached to the forceps. Now the clamp is ready for trial placement.

Pass the rubber dam forceps, with the working end covered, with the palm of your hand and the clamp pointed toward the placement position of the tooth. Be sure to hold on to the ligature while the clamp is checked for proper fitting. Normally, the clamp should fit near or slightly below the cemento-enamel junction. To stabilize the clamp, all the tips of the clamp must be in contact with the tooth to establish a facial lingual balance. Exercise care to ensure that the clamp tips do not impinge on the gingival tissues. If it does, it will cause the patient to experience pain. If the clamp is not placed properly, it may spring off the tooth and cause injury. Caution is advised to stabilize the clamp firmly on the tooth before the clamp forceps are loosened. Once the trial placement is complete, remove the forceps and attach the clamp until final placement.


To prepare the rubber dam material, you need the rubber dam punch to make the appropriate number of holes of varying sizes. The punch has an adjustable wheel with holes of varying sizes. By adjusting the wheel, holes of different sizes are produced in the material when the cutting tip strikes the hole in the wheel. The holes in the rubber dam material must be punched firmly and cleanly. A ragged hole or tag will tear easily as the dam is placed over the crowns of the teeth. A 'ragged hole also may cause leakage of moisture around the tooth.

Ideally, the rubber dam material is marked (fig. 4-24) with predetermined markings of an average arch using a rubber dam stamp and ink pad. This makes punching the rubber dam material easier because you have a pattern to follow with the normal shape of the arch and spacing alignment of the teeth. Before punching the material, always check the oral cavity for any missing, misaligned, or extra teeth. You will need to make adjustments from the standard pattern for

these items. Punch the hole for the tooth to be treated first. Then, determine what additional holes must be punched. Normally, you will punch holes for the two anterior and at least one tooth posterior to the tooth being treated. An **exception** to this is root canal therapy when only the involved tooth is exposed. After the holes are punched, apply a slight amount of water soluble (brushless shaving cream) lubricant to the back of the material over the crowns and contact areas of the exposed teeth. Now the rubber dam is ready for placement into the oral cavity.

## Placement

The rubber dam material and clamp can be placed using several methods. The first method usually requires assistance. Place the rubber dam frame on the outside of the dam with the bow of the frame facing out. Stretch the dam material from side to side to secure the corners of the dam on the four projections at the corner of the frame. The rubber dam material should appear baggy on the frame rather than tight to allow easier placement in the oral cavity. Pass the rubber dam and attached frame to the dentist for placement in the oral cavity. As the dentist stretches the rubber dam material over each tooth to be isolated, the assistant uses floss to slip the septum (rubber dam material between the holes) between the teeth without tearing the material. Always place the floss on the tooth, never directly on the rubber dam itself. Placement of the floss upon the tooth assists in bringing a single thickness of the dam through the



DTV2F424

Figure 4-24.—Marked rubber dam material.

proximal contact when the floss is carried through. Floss placed on the rubber dam itself tears the dam and requires the passing of two thicknesses of the dam through the contact. Once the floss passes the contact of the teeth, release the lingual end of the floss. Loop this end toward the opposite end and floss through the contact again. Now, gently remove the floss by pulling it from the side horizontally, rather than attempting to pull the floss back up through the contact vertically. Continue using the floss to invert the inter-proximal septum, mesially and distally as well. Inversion of the rubber dam turns the edges of the dam inward or under, around the isolated teeth, to provide a seal. After this is completed, pass the rubber dam clamp forceps and attached clamp to the dentist for final placement on the tooth. Adjustment of the rubber dam material on the frame can be made at this time to ensure a smooth and stable fit. Wrap the ligature attached to the clamp around a projection on the side of the frame. This prevents the clamp from becoming a dangerous projectile if it should spring off the tooth. Pass a dull instrument, such as a stellite instrument, to the provider for inversion of the rubber dam on the facial and lingual areas of the exposed teeth. Dry the exposed teeth with air from the three-way syringe as needed to assist in the inversion.

The second method places the rubber dam clamp on the tooth first. Then slip the rubber dam material over the clamp. Next, in either order, attach the frame and expose the remaining teeth through the holes. Secure the clamp ligature to the frame. Then invert the mesial and distal septum with floss, and the facial and lingual areas with a dull instrument accompanied with air from the three-way syringe.

In the third method, the clamp is held in the rubber dam forceps and the rubber dam placed over the bow of the clamp. Holding the edges of the rubber dam with your fingers, use the forceps to carry the dam and clamp into the patient's mouth. Place the clamp on the tooth and remove the forceps. Continue the placement as in the second method. The last two methods of rubber dam placement are valuable when a rubber dam must be placed by one individual rather than two. After the restoration is placed, remove the rubber dam.

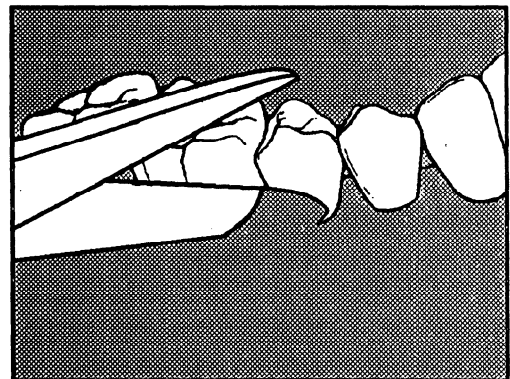
### Removal

Before the rubber dam is removed, use the water syringe and high-volume evacuator (HVE) to flush out all debris that collected during the procedure. Rather than pulling the septa through the contact of a newly placed restoration, the septa is cut. Stretch the rubber

dam material outward in the facial area of the isolated teeth. This pulls the septa facially to provide access for cutting. Use a pair of small blunt-nose scissors to cut each septum of the rubber dam from the facial aspect (fig. 4-25). When all the septa are cut, gently pull the dam lingually to free the rubber dam completely from the interproximal spaces. Use the clamp forceps to remove the clamp. Simultaneously, remove the clamp ligature from the frame. Set the clamp forceps and clamp aside. Now, remove the dam with the frame attached. Wipe the patient's mouth, lips, and chin with a tissue or gauze. Carefully inspect the dam on a flat surface for missing pieces. If a fragment of the rubber dam is missing, check the corresponding interproximal area of the oral cavity with a mirror and explorer. Pieces of the rubber dam left under the free gingiva cause severe gingival irritation. Use dental floss to remove any material stuck between the teeth. Rinse the patient's mouth with the water syringe and HVE to remove all debris from the oral cavity.

### MATRIX RETAINERS

Matrix retainers are used to hold the matrices (metal bands or strips) firmly in place around a tooth. Matrix retainers and metal bands are used in combination for a temporary mold while the filling material is being packed into place. The Tofflemire retainer (or matrix retainer) is available in three different designs: the universal straight, contra-angle, and contra-angle junior (pedodontic) shown in figure 4-26. These retainers are practically maintenance free. They can be heat sterilized along with other dental instruments. Your part in maintaining matrix retainers is to check them periodically and replace those with badly worn screw threads. You are also expected to attach the correct matrix band to the appropriate retainer in anticipation of the dentist's needs.



DTV21425

Figure 4-25.—Cutting rubber dam septum.



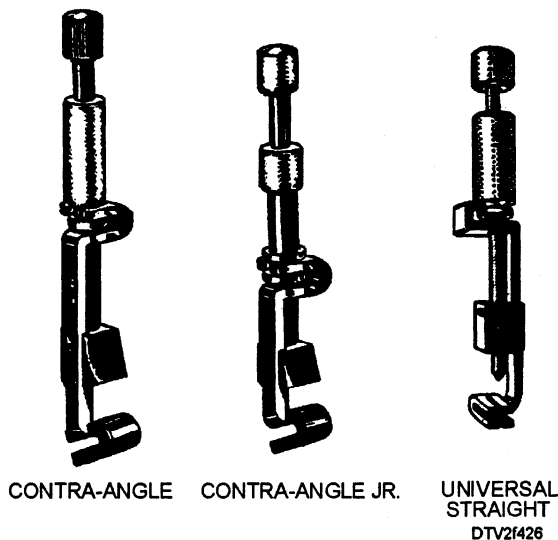


Figure 4-26.—Matrix retainers.

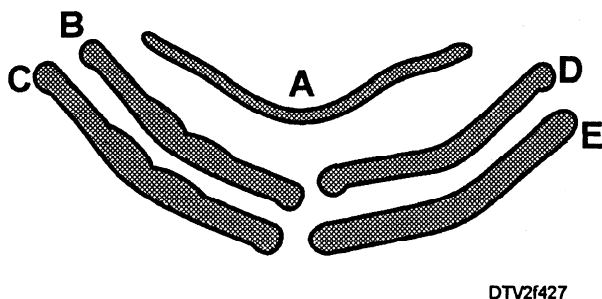


Figure 4-27.—Amalgam matrix bands. A: Precontoured. B: Junior (Pedodontic #15 with aprons). C: Wide #2 with aprons. D: Junior #13 (Pedodontic). E: Universal #1.

### Amalgam Matrices

Amalgam matrices are made of very thin flexible stainless steel available in either roll form or in bands. At times, the standard packaged matrix bands do not

provide the necessary length, width, or shape for a particular cavity preparation. When this is the case, the dentist can cut the metal matrix strips to form the needed band. Bands used with the Tofflemire retainers completely encircle the tooth. Matrix bands come in assorted sizes and shapes, as shown in figure 4-27. The **most commonly** used band is the Universal or Straight #1 size. The Junior #13 is the smaller pedodontic version of the #1 Universal. The Wide #2 and Junior #15, (which have extensions known as “aprons”) are used when additional length is needed for a preparation extending below the gingiva. A dentist usually prefers certain types of these bands over others. With practice, you should become very proficient in having the preferred band on the appropriate retainer.

### ASSEMBLING MATRICES

When multiple surfaces of the tooth are removed during the cavity preparation, a matrix is used to approximate the original surface and hold the restorative material in proper form and position until it sets. The type of matrices used depends on the type of restorative material placed. You will need to have the right type of matrix available and assembled ready for use during the procedure.

Amalgam matrices are made of very thin, flexible stainless steel available in either roll form or bands. The matrix band, retainer, and wedge are used in combination to form a temporary mold while the filling material is being packed.

The matrix is assembled and placed before the amalgam is mixed. After the amalgam has been packed, the matrix and wedge must be removed before the final carving can be accomplished.

The most commonly used retainer is the universal straight Tofflemire. Its components are shown in figure 4-28.

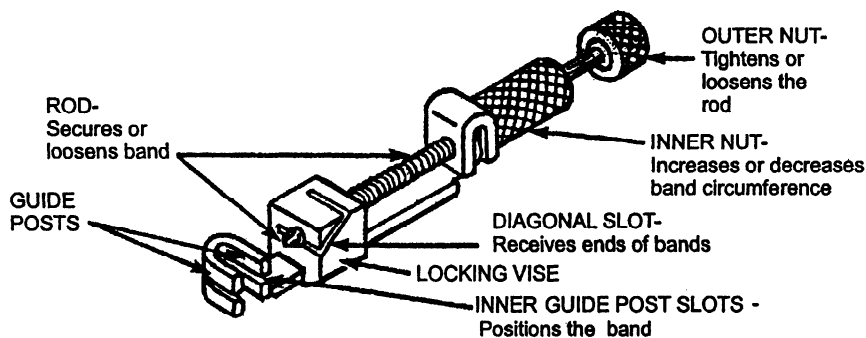


Figure 4-28.—Components of the matrix retainer.

To assemble the matrix, hold the retainer in one hand with the slots in the guide posts and locking vise facing upward. Turn the large inner nut counterclockwise to position the locking vise close to the guide post. Turn the small outer nut counterclockwise until the rod is not visible in the locking vise slot. In your other hand, grasp the band with the ends placed evenly together. Place the edge of the band with the larger circumference (occlusal edge) into the diagonal slot at the vise end of the retainer. With the band placed in this manner, the larger circumference is toward the occlusal surface and the smaller circumference toward the gingiva, as shown in figure 4-29. Continue to ease the band through the inner guide post slot. As figure 4-30 shows, position the band through the left guide post for teeth on the mandibular right or maxillary left quadrants. For teeth in the mandibular left or maxillary right quadrants, position the band through the right guide posts. Turn the outer nut clockwise until the rod tip presses firmly against the band in the lock vise to secure the band. Turn the inner nut counterclockwise to increase the size.

When the assembled matrix is placed over the prepared tooth, the slot opening of the retainer and the small circumference of the band are positioned toward

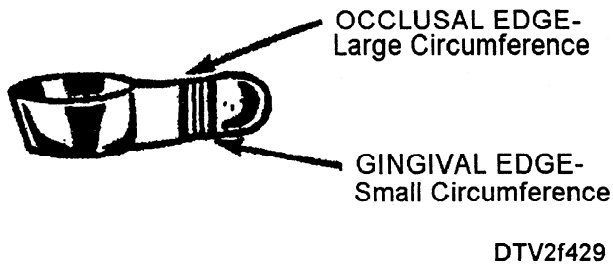


Figure 4-29.—Large and small circumferences of the band.

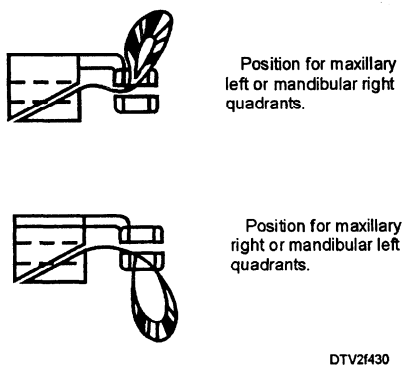


Figure 4-30.—Positioning the band to the right or left for the appropriate quadrants.

the gingiva, and the retainer is placed along the facial surface of the tooth. The handle of the retainer extends out of the oral cavity at the corner of the lips. The dentist gently manipulates the matrix band into the inter-proximal space on either side of the tooth. The dentist then places an index finger or thumb over the occlusal surface to hold the band in place and tightens the band by turning the inner nut clockwise to fit snugly around the tooth. At this time, the dentist may decide to place a wedge along the side of the matrix band.

### Wedges

Wedges are small, tapering, triangular pieces of wood or clear plastic about 1/2 inch in length. Wedges are available in various sizes, which may be color coded. They are either plain (straight) or anatomically shaped (fig. 4-31). Clear plastic anatomical wedges are designed for use with light-cured materials.

Since the general shape of tooth crowns varies, the matrix band around the tooth may not always produce a snug fit. This leaves space through which condensed restorative material can be pushed out to create an undesirable overhanging restoration. The dentist uses wedges to force the matrix band or strip tightly against irregular tooth surfaces to prevent these spaces. This snug fit then restricts the firmly condensed restorative material to the confines of the prepared cavity margins and the band itself.

### Matrix Removal

Because new restorations fracture easily, use extreme care when removing the matrix band. To remove the matrix band and retainer, the dentist, first

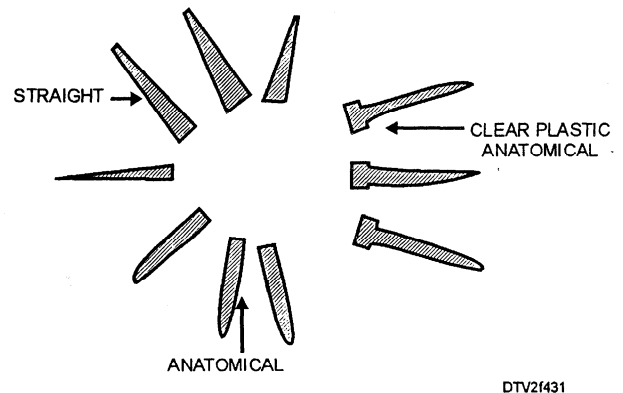


Figure 4-31.—Wedges.

gently manipulates the point of an explorer around the inside edge of the band. This contours the marginal ridge of the restoration and removes the excess amalgam around the matrix band. The assistant will pass the dentist hemostats or cotton forceps to remove the wedge if one was placed. With the thumb or finger over the occlusal surface of the restoration and matrix band, the outer and inner nuts are turned counterclockwise to loosen the retainer from the band. After the retainer is removed, the remaining band is carefully removed. A loose end of the band is grasped with the hemostats or cotton forceps and gently rocked back and forth until the band comes out of the interproximal space. Remove the band from the other interproximal space in the same manner.

### PIN AMALGAM SET

Extensive decay or a cusp fracture results in the loss of a major portion of the tooth structure. To restore such a tooth to its former healthy condition, the dentist may choose to rebuild the tooth. If the tooth is a posterior one, the dentist may use the pin amalgam technique. For a pin amalgam restoration, the dentist uses specific instruments. The pin amalgam instruments are packaged in kits in which pin burs (drills), self-threading pins, and pin (hand) wrenches are precision matched. It is extremely important to keep the set together since there are a large variety of types and sizes. The pins are placed with a hand wrench in the tooth preparation to anchor the amalgam or restorative material in place (fig 4-32). A **pin bender** is frequently used to bend or slightly adjust the position of inserted pins. Follow the manufacturer's instructions before handling these materials.

### FOUR-HANDED DENTISTRY

The goal of four-handed dentistry is to allow the dentist and assistant to function as a team in a seated

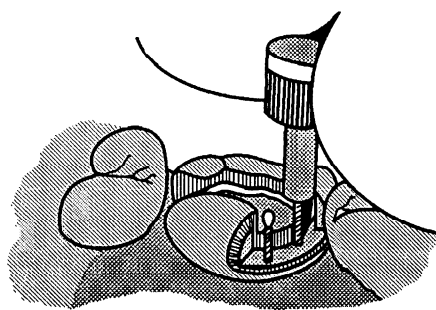


Figure 4-32.—Using a hand wrench to place pins in a tooth preparation.

position with maximal efficiency and minimal strain. Four-handed dentistry, as it has been developed, not only increases productivity, but also reduces stress and fatigue on the provider and assistant. Four-handed dentistry can be used in all of the specialty areas, and in operative dentistry. It is discussed here because instrument exchanges in operative dentistry require you to perfect this task. To be an effective dental assistant in four-handed dentistry, you must know the correct zones and positions that you are in and where you are in relation to the patient and dentist. Also correct passing and receiving of instruments and materials to the dentist is a task that must be practiced to work efficiently with the dentist.

### ZONES AND POSITIONS

The position of the patient is determined by the procedure to be performed. Most dental treatment is provided with the patient in the supine position. Once the patient has been seated, the dentist and the assistant should place themselves in the proper positions for treatment. These positions are best understood by relating them to a clock. In the clock concept, an imaginary circle is placed over the dental chair, with the patient's head at the center of the circle. The circle is numbered like a clock with the top of the circle at 12 o'clock. The clock, as shown in figure 4-33, is divided into four zones of operation:

- Static zone
- Assistant's zone
- Transfer zone
- Operator's zone

The use of these zones is the key to the efficient implementation of the principles of four-handed dentistry. For right-handed dentists, seated to the right of the patient, the **operator's zone** is between 8 and 11 o'clock, and the **assistant's zone** is between 2

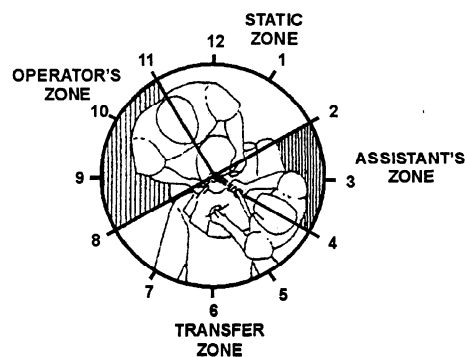


Figure 4-33.—Zones of operation for four-handed dentistry.

and 4 o'clock. For left-handed dentists, seated to the right of the patient, the **operator's zone** is between 1 and 4 o'clock position and the **assistant's zone** between 8 and 10 o'clock. Whenever the treatment site is on the lingual surfaces of anterior teeth, the dentist (right or left-handed) generally uses the 12 o'clock position.

The **transfer zone** is from 4 to 8 o'clock. Instruments and materials are passed and received in this zone over the chest and at the chin of the patient. All instruments and materials are located in the assistant's zone.

The **static zone**, from 11 to 2 o'clock, is a non-traffic area where equipment, such as nitrous oxide, can be placed with the top extending into the assistant's zone. When an object is heavy, or material or an instrument is objectionable if held near the patient's face, you may pass or hold it in the static zone. As an example, anesthetic syringes are sometimes passed to the dentist in this area so that the patient will not be alarmed at the sight of the syringe. Part of this area can also be used when the provider is positioned in the 12 o'clock position as previously mentioned.

Dentists and dental assistants should sit with their back straight and head relatively erect. This helps prevent curvature of the spine. The patient should be lowered to a position that places the treatment site as close to the dentist's elbow level as possible. When the patient is properly positioned, the dentist's eyes should be 14 to 16 inches from the treatment site.

As the assistant, you should sit as close as possible to the back of the patient's chair with your feet directed toward the head of the chair. This position lets you reach the treatment site, hose-attached instruments, and instruments and materials from the mobile cart or instrument tray without leaning, twisting, or overextending your arms. In this position you are also able to observe the patient's responses throughout the procedure. Adjust your stool so that your eye level is 4 to 6 inches above the dentist's eye level. Like the dentist, the assistant should sit in an erect position. The assistant's chair may have a curved, movable armrest. This armrest may be adjusted in front to support the body just below the rib cage. Using this armrest as a brace, you are able to lean slightly forward from the hips only. Place your feet firmly on the foot-support ring at the base of the assistant chair so that your feet are parallel to the floor. The mobile cart or instrument tray should be placed toward the head of the patient's chair, and positioned to allow you easy access to the needed instruments and materials.

## **PASSING AND RECEIVING INSTRUMENTS AND MATERIALS**

To increase production while reducing stress and fatigue of the dentist and the assistant, you and the dentist will need to work together as a team. You must be able to anticipate the dentist's needs and fulfill those needs without unnecessary delay. To accomplish this, you must know the sequence of the treatment procedure and have the required instruments and materials ready at the proper time. When you assist in four-handed dentistry, you must also irrigate with air and water as well as aspirate with the high-volume evacuator throughout the procedure. To enable you to pass and receive items efficiently during the procedure, we will begin with instrument transfers.

### **Instrument Exchange**

Instrument exchange between the dentist and assistant takes place in the transfer zone near the patient's chin. As the assistant, you must anticipate the dentist's needs, and be ready when signaled by the dentist to pass the next instrument and receive the used one in a smooth motion. An alert assistant does not need a verbal command to make the exchange, but should be constantly ready when the exchange signal occurs. Ideally, the instrument transfer is accomplished with a minimum of motion involving movement **only of your fingers, wrist, and elbow**. During the transfer, the dentist should **not** move the finger rest or eyes from the treatment site. When the exchange is completed, the dentist pivots the working hand back to the working position.

You should arrange the instrument setup in an orderly fashion. Usually the instruments are set up from left to right, in the sequence in which they are to be used. You should return them to their original position following use in case they need to be reused.

Let's assume that you are assisting a right-handed dentist and, therefore, are seated on the left side of a patient. Since your right hand is busy aspirating, you must learn to transfer instruments with your left hand. The one-hand instrument exchange is discussed next.

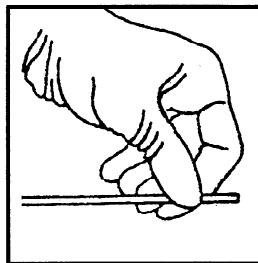
**ONE-HAND INSTRUMENT EXCHANGE.—**  
The actual instrument transfer is divided into four stages—**working, signal, pre-transfer, and mid-transfer**.

In the working stage, pick up the next instrument to be used from the instrument tray with your left

hand. Grasp the instrument between your thumb and first two fingers by the end opposite from the working end as shown in figure 4-34 (step A). Hold the working instrument close to the treatment area and parallel to the instrument being used. Extend your little finger to receive the instrument being used by the dentist as shown in figure 4-34 (step B).

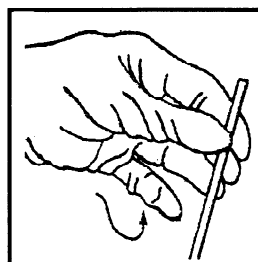
The signal stage takes place when the dentist signals for the next instrument by slightly raising the instrument from the tooth. During this stage, the dentist maintains his/her fulcrum (finger rest) and, with a pivotal action, rotates the working hand away from the patient's oral cavity. This positions the used instrument so that you can grasp it with your little finger.

## STEPS



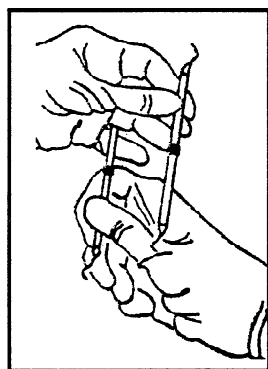
Hold instrument opposite the working end.

**A**



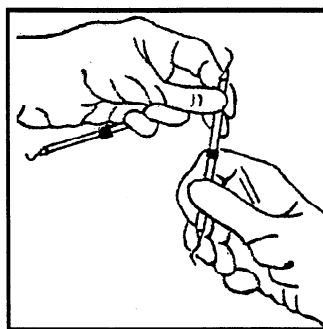
Hold instrument with thumb, index and ring fingers ready to pass. Prepare to receive used instrument with little finger extended.

**B**



Passing position

**C**



New instrument placed in dentist's hand with working end pointed towards working site. Used instrument pulled toward assistant's hand.

**D**

DTV2f434

Figure 4-34.—Instrument exchange (steps A through D).

In the pre-transfer stage, grasp the used instrument firmly using the little finger as shown in figure 4-34 (step C). Sometimes, you may prefer to use the last two or even three fingers to receive the used instruments. Immediately following this action, you carry out the mid-transfer stage.

In this stage, place the next instrument into the dentist's hand with the working end positioned toward the treatment site, as shown in figure 4-34 (step D). When the treatment site is located on the maxillary arch, point the working end of the instrument **up**. Likewise, when the treatment site is on the mandibular arch, position the working end **down**. Do not release your grip of the new instrument until the dentist has firmly grasped the instrument. If the instruments become tangled during the exchange, this is usually caused by failure to parallel the handles before the exchange. The exchange of all instruments is done with firm, deliberate movements to give both the dentist and the assistant the feeling of confidence and to eliminate lost time and motion. Return the used instrument to its original position on the instrument tray and prepare to repeat the procedure with the next instrument required.

Refer to figure 4-35 for an overhead view (left-handed) of an instrument exchange during patient treatment. When you assist from the right side of the

patient, use your **right hand** in the same manner described for the left hand.

**OTHER INSTRUMENT EXCHANGE TECHNIQUES.**—Other instrument exchange techniques may have to be used depending on what type of instrument is being exchanged. These other techniques have been described in "Oral Surgery Assistance," Volume 2, chapter 5.

### Handpiece and Bur Exchange

The dental handpiece can be exchanged for another instrument in the same manner described in this section. If two handpieces are exchanged, exercise caution to avoid tangling the hoses during the exchange.

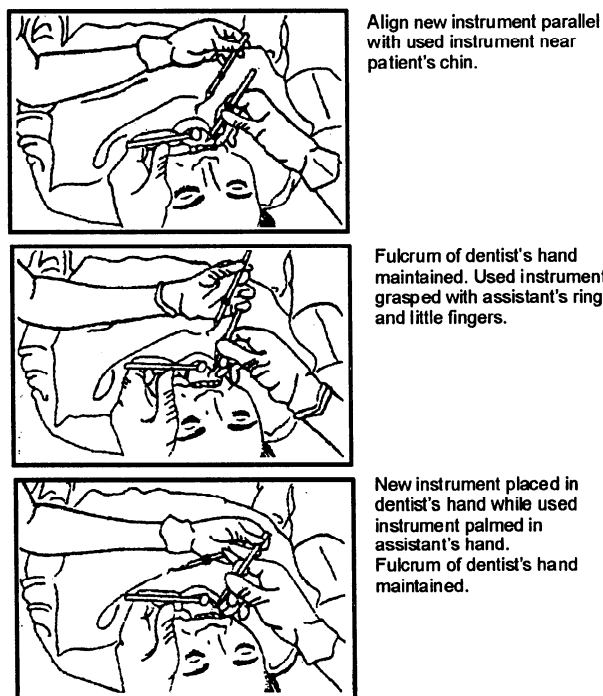
During the operative procedure, the dentist holds the handpiece firmly over the patient's upper chest in the transfer zone, and then the assistant will loosen and remove the bur. The assistant next retrieves the bur that was selected by the dentist and places it into the dental handpiece and secures it. Always give the bur a gentle tug to ensure that it is firmly seated in the handpiece. If the dentist uses a different instrument between bur exchanges, change the bur outside the transfer zone, usually over the tray setup.

If the dentist changes handpieces and requires an exchange of burs in the returned handpiece, be sure to use the lock-out toggle switch for the handpiece before attempting to change burs. If you fail to do this, you could cause harm to yourself when the provider steps on the foot control to activate the other handpiece.

### Preparing and Passing Materials

Dental materials are exchanged at the patient's chin in the transfer zone. This prevents materials from being dropped on the patient's face. Small amounts of dental materials may be mixed and passed on a glass slab, paper pad, or dappen dish.

As a dental assistant, you must prepare dental materials at the proper time during the procedure. A material mixed too soon does not allow sufficient handling time. Knowing when to mix is equally as important as knowing how to mix. As with instruments, knowing the routine of the procedure lets you anticipate when the dentist will need the specific material. You should have the mixing equipment ready and the material in position and in place slightly before the time it is needed. Begin mixing only when you know the dentist is ready.



DTV2f435

Figure 4-35.—Overhead view of instrument exchange.

When you are assisting during an amalgam restoration, load the amalgam into the carrier and pass the loaded carrier to the dentist. You may sometimes use two or more amalgam carriers, which lets you fill the barrel of one while the dentist is using the other. You must also add into this sequence of filling and refilling the amalgam carriers the passing of condensing instruments to the dentist during the amalgam restoration process.

During the use of cements, most dentists prefer that you leave the mixed cement on the glass slab or mixing pad and then hold the pad or slab in your hand near the treatment site. The dentist can select the amount desired. In your other hand, you can hold the air syringe to dry the area for application and placement of the material. With the use of some materials, you may need to hold a gauze sponge in your hand (rather than the air syringe) to wipe excess material from the application instrument.

The overall idea in passing and receiving dental instruments and materials is to have the needed item at the right place, in the right position, at the right time. In doing this, the dentist is then free to concentrate more on the area of treatment.

## **BASIC DENTAL PROCEDURES**

Some basic dental procedures, such as administration of local anesthetic, irrigation, aspiration, and retracting of tissues, are performed in nearly all aspects of all clinical dentistry. Others such as rubber dam application and assembling of matrices are performed in operative procedures. Except for the administration of local anesthetic, you must be able to perform these procedures. When administration of local anesthetic is required, you need to prepare all the items used for this procedure.

### **LOCAL ANESTHETIC**

Before doing a possibly painful dental procedure, the dentist will give the patient a local anesthetic to make the treatment site insensitive to pain. You must be knowledgeable of the various techniques used to prepare for the correct type of injection. These techniques such as topical, infiltration, and block injections have been discussed in Volume I, chapter 7, "Oral Pharmacology."

### **Pre-Injection Items**

Before giving a local anesthetic, the dentist may use the following pre-injection items to prepare the injection site:

- Antiseptic solution
- 2 x 2 inch gauze sponges
- Cotton tip applicators
- Topical anesthetic

The dentist may have the patient use an antiseptic mouthwash to rinse the oral cavity before applying a topical anesthetic. The gauze sponges are used to dry the injection site mucosa before applying the topical anesthetic. The topical anesthetic, usually supplied in an ointment, is applied with a cotton tip applicator to reduce the pain associated with the injection of the needle.

### **Injection Items**

The items used to give local anesthetics are an aspirating syringe, needle, and carpule. It is also important to know the different types of anesthetic and how to assemble and disassemble the aspirating syringe properly for the dentist's use.

You'll find many types of anesthetic carpules in Navy dentistry. As discussed in Volume I, chapter 7, "Oral Pharmacology," the two most common local anesthetics used in dentistry are 2% lidocaine hydrochloride and 2% mepivacaine. Each type of anesthetic is sealed in a 1.8-cc glass carpule. The needle end of each carpule is sealed with rubber membrane held in place by a metal band. The other end has a different colored rubber stopper. Each type of anesthetic has a different colored rubber stopper.

### **Assembling An Aspirating Syringe**

Based on the patient's health history and the procedure to be performed, the dentist will inform you which type of anesthetic (including vasoconstrictor content), needle length, and needle gauge to use to prepare the syringe. You will become familiar with each dentist's preference and various procedures for needle length and gauge. However, always verify the type of anesthetic solution. Assemble the syringe out of the patient's view to reduce unnecessary patient apprehension. Assembly can be done while the dentist administers the topical anesthetic.

First, always check the carpule for cracks or suspended articles floating in the solution. If you find any, discard the carpule and notify the dental and dental supply to ensure other batches of anesthetic are usable. Disinfect the rubber diaphragm on the carpule before loading it in the syringe. **Do not** touch the rubber diaphragm after you disinfect it. Placing the carpule end in the aspirating syringe is fairly easy. Use the following steps:

- Use the thumb ring to pull the plunger back against the syringe body.
- Place the cartridge into the barrel of the syringe with the rubber stopper end in first, positioned toward the plunger.
- Break the seal on the needle container and remove only a small portion of the plastic needle cover.
- Insert the needle into the syringe and screw the hub onto the syringe.
- Engage the harpoon into the rubber stopper of the cartridge by holding the body portion of the syringe with one hand while lightly tapping the end of the thumb ring with your other hand.

#### **CAUTION**

Do not tap the thumb ring with too much force; this might cause the glass carpule to shatter.

- Make a quarter turn with the thumb ring to ensure that the harpoon is firmly engaged in the rubber stopper. If it is, the thumb ring will rotate back to its original position.
- Force a small, but visible amount of anesthesia through the needle to expel air.
- Loosen the needle cap, but keep the plastic needle covering in place until you pass the syringe to the dentist to guard against possible contamination.
- The plastic needle cover must be removed to check the syringe's operation and during the injection.

#### **Passing and Receiving the Syringe**

The dentist will be ready to administer the local anesthetic after the topical anesthetic is applied. The assistant passes the syringe with the needle cover in place. Hold the barrel of the syringe in your hand. Place the thumb ring of the syringe over the dentist's thumb and the finger grip between the dentist's index

and middle fingers. While you are still holding the syringe by the barrel, use the other hand to remove the needle cap.

After the dentist gives the injection, carefully remove the syringe by grasping the barrel and lifting the syringe out of the dentist's hand. Remember to exercise extreme caution when grasping the barrel of the syringe because the needle is exposed and contaminated. **DO NOT** attempt to recap the needle while the syringe is in the dentist's hand. If it is necessary to recap the needle, it must be done using some type of mechanical device or the one-handed scoop technique discussed in Volume I, Chapter 9, "Infection Control."

#### **Disassembling the Aspirating Syringe**

After the patient is dismissed, the syringe must be disassembled safely. It is vitally important to prevent needle sticks from the contaminated needle. It is advisable to first remove the carpule with the needle remaining in place. This provides an air vent to prevent the glass carpule from shattering. To unload the carpule, pull the piston rod back as far as possible to disengage the harpoon from the rubber stopper without pulling the stopper from the carpule. The carpule can then be easily removed from the syringe. Remove the used needle and dispose of it into a puncture-resistant container according to established infection control standards.

#### **IRRIGATION AND ASPIRATION**

Immediately after the dentist administers the local anesthesia, you will irrigate and aspirate the injection site. This is necessary because the anesthetic solution produces a bitter taste in the patient's mouth. Additionally, you are required to irrigate and aspirate (drawn by suction) often throughout the treatment procedure to maintain a clean treatment site.

#### **Irrigation**

The dentist expects you, as the dental assistant, to irrigate the oral cavity when necessary. By applying water or saline solutions to the treatment site in the oral cavity, small tooth particles, dried blood, and other debris are flushed from the area and removed by aspiration. Handpieces with water spray systems provide some irrigation, but additional irrigation is always necessary. At times, the dentist may decide not to use the water spray system on the handpiece for a particular procedure. During routine operative procedures, you will use the three-way syringe on the

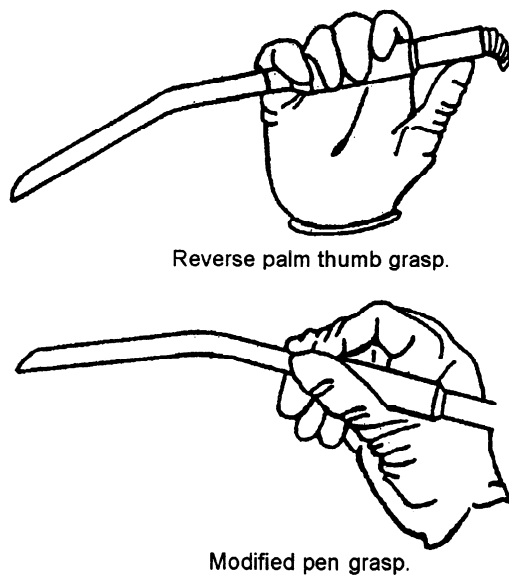


dental unit to irrigate the treatment site with water or water spray. The tip of the three-way syringe rotates easily to direct the water, spray, or air at the specific treatment sites. The tip disconnects to allow for sterilization.

When you irrigate treatment sites during surgical procedures, you will use a sterile saline solution or sterile water as the irrigation solution. Sterile saline or sterile water is applied by using a bulb-type or Luer (piston-barrel) syringe. The main purpose for irrigation during surgical procedures is to keep a clean treatment site. The cleansing is not complete until the irrigating solution is aspirated from the mouth.

### Aspiration

Aspiration is necessary to remove blood, pus, saliva, and debris from the treatment site and oral cavity. This is done by using the high-volume evacuator (HVE) or saliva ejector. Figure 4-36 illustrates the reverse palm grasp and modified pen grasp that should be used when you are using the HVE. As the dental assistant, you must assure that a sterile or disposable tip is in place for each patient. When using either of these, always place the tip in the upright position before turning the aspiration off. This helps prevent materials from dripping out or clogging the hoses. You must also clean and maintain the evacuation system as instructed in the manufacturer's operation and maintenance instructions.



DTV2f436

Figure 4-36.—Reverse palm grasp and modified pen grasp using an HVE.

## OPERATIVE PROCEDURES

Operative dentistry strives to restore decayed or fractured teeth to their original functional ability and esthetic quality of healthy dentition. In general, procedures include the following:

- Determining the procedure to be done
- Administering anesthesia
- Placing a rubber dam
- Preparing the cavity or cavities to be filled
- Placing filling material into prepared cavity preparations
- Carving and finishing restorations
- Smoothing and polishing restorations

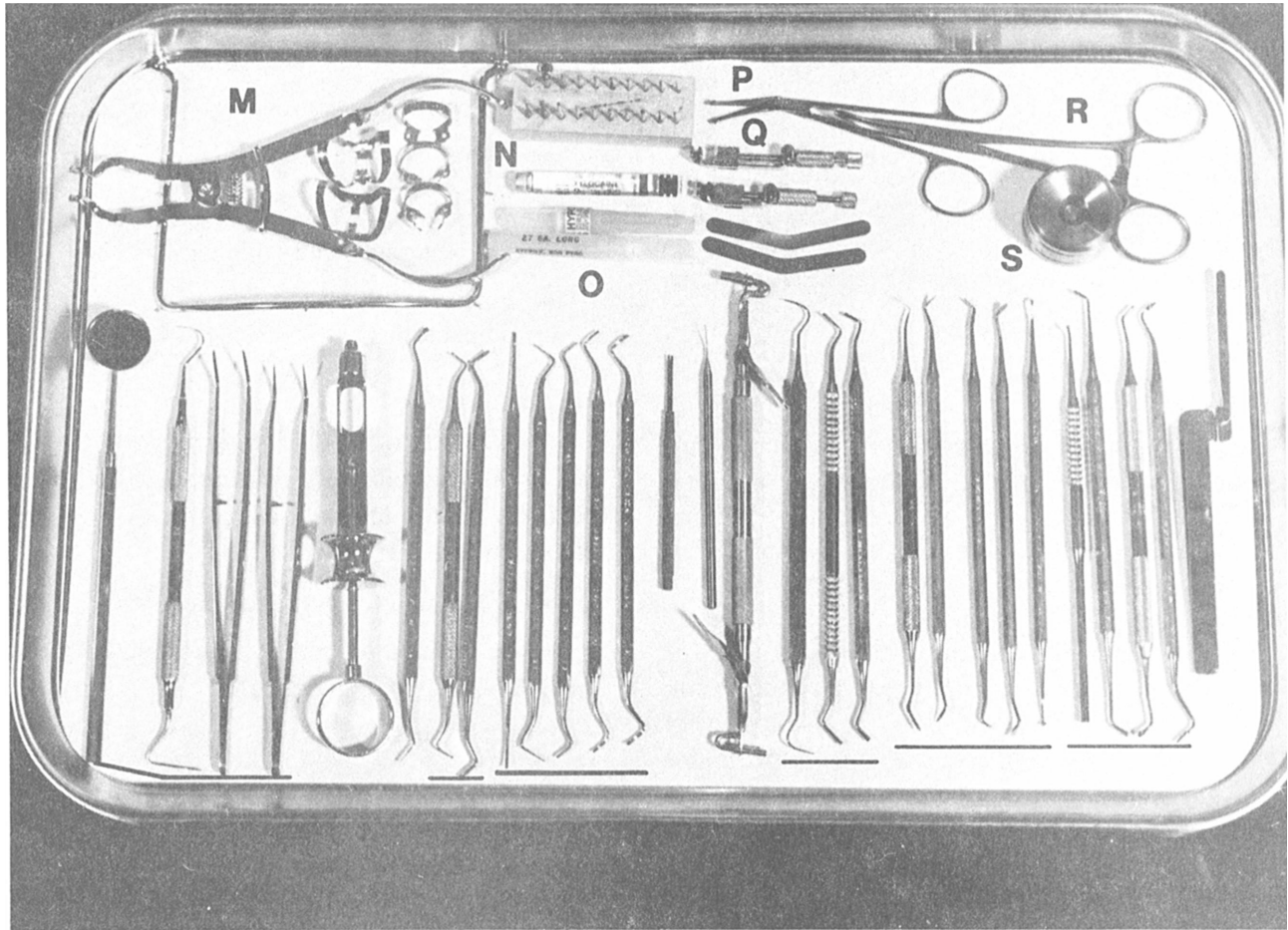
As an assistant in operative dentistry, you will perform many of the basic clinical procedures discussed earlier, such as:

- Preparing the dental treatment room (DTR)
- Performing proper infection control procedures
- Wearing appropriate personal protective equipment
- Selecting and arranging instruments and materials required for the procedure
- Receiving and preparing the patient
- Preparing local anesthetic
- Irrigating and aspirating throughout the procedure
- Retracting tissue to maintain a clear field of vision
- Preparing and assisting with the placement of the rubber dam
- Preparing, passing, and receiving instruments and materials

Figure 4-37 illustrates a typical selection and arrangement of instruments for a routine operative procedure. Items should be arranged in sequential order of the procedure to proceed smoothly without delay.

## TERMINOLOGY AND CLASSIFICATION OF CAVITIES

For the necessary treatment procedures to proceed smoothly and without delay, you need to understand some basic terminology and classification of cavities.



- |                                       |                                                                             |                                                                  |               |                                                                                  |                                               |                                                                                                                                                                                 |
|---------------------------------------|-----------------------------------------------------------------------------|------------------------------------------------------------------|---------------|----------------------------------------------------------------------------------|-----------------------------------------------|---------------------------------------------------------------------------------------------------------------------------------------------------------------------------------|
| A                                     | B C D                                                                       | E                                                                | F GH          | I                                                                                | J                                             | K L                                                                                                                                                                             |
| A. BDS with extra cotton forceps      | B. Anesthetic Syringe<br>C. Stellite<br>D. Small and Large Spoon Excavators | E. Handcutting Instruments<br>Chisel, Hoe, Hatchet, Paired GMT's | F. Pin Bender | G. Dycal Instrument<br>H. Double Ended Amalgam Carrier<br>I. Assorted Condensers | J. Assorted Carvers<br>K. Assorted Burnishers | L. Articulating Forceps<br>N. Burs<br>O. Anesthetic Carpule & Needles<br>P. Blunt Tipped Scissors<br>Q. Toffelmire Retainers and Bands<br>R. Curved Hemostat<br>S. Amalgam Well |
| M. Rubber Dam Frame, Forceps, & Clamp |                                                                             |                                                                  |               |                                                                                  |                                               |                                                                                                                                                                                 |

Figure 4-37.—Typical operative dentistry instrument tray setup.

A cavity preparation is a mechanical procedure that removes caries or existing restorative materials and a limited amount of healthy tooth structure to receive and retain restorative materials in the cavity preparation. A cavity wall is a side or surface of the cavity preparation that aids in enclosing the restorative material. You should already be familiar with the terms used to describe the various tooth surfaces, such as mesial, distal, lingual, facial, incisal, and occlusal. A bevel is a slanting of the enamel margins of the tooth

preparation cut at an angle with the cavity wall. There are numerous types of bevels, such as full, long, chamfer, and dovetail.

Cavities can occur on one or more surfaces, and can be of various sizes, ranging from very small to those that include all five surfaces of the tooth. Simply, cavities are those which occur on one surface of the tooth. When two surfaces of the tooth are involved, the cavity is called a compound cavity. A cavity is

considered a complex cavity when three or more surfaces are involved. Compound and complex cavities may include one or both of the proximal surfaces as well as portions of the facial and lingual surfaces. When caries attack the proximal surfaces of posterior teeth, the cavity preparation must also include preparation of the occlusal surfaces.

Cavities may be classified according to the location where the carious lesion begins. Caries frequently start in the developmental **pits and fissures** of the teeth. These areas are deeper than the surrounding tooth substance and are nearly impossible to clean thoroughly, creating ideal conditions for bacterial plaque formation. Locations of pit and fissure caries can be located in any of the following areas:

- Lingual pits of maxillary incisors
- Lingual grooves and pits of maxillary molars
- Occlusal surfaces of posterior teeth
- Facial grooves and pits of mandibular molars
- Pits occurring in areas because of irregularities in the formation of enamel

Smooth surface cavities can be found on all teeth on the proximal surfaces, and gingival one-third of the facial and lingual surfaces.

## **STEPS IN CAVITY PREPARATION**

After the dentist decides which tooth or teeth to restore, the anesthesia is administered and the rubber dam placed. If you are well prepared, the steps in the cavity preparation should proceed smoothly without delay, and the patient will be more at ease and confident. Watch closely during the procedure and be ready to irrigate and aspirate as needed, as well as, pass the instruments and material to the doctor when needed. The initial cavity preparation generally is done using the high-speed handpiece and a variety of rotary instruments.

### **Cavity Design**

The design of the cavity preparation for either a tooth with initial caries or replacement restoration is based on the location of the caries, the amount and extent of the caries, the amount of lost tooth structure, and the restorative material to be used.

Some basic principles should be considered when preparing a cavity preparation. The dentist must

establish an **outline form**, which determines the overall shape of the preparation along the cavity margins of the restoration and the tooth surfaces. The outline form is determined by the size and shape of the carious lesion and by the need for a suitable design that will hold a restoration firmly in place. Usually, the dentist is able to visualize the shape of the completed cavity before cutting the preparation by viewing the extent of the caries on the radiograph and examining the tooth and soft tissues.

### **Removal of Remaining Caries**

Cariou dentin not removed during the design of the cavity preparation is removed by using either round burs or spoon excavators. When the dentin has a firm feel with the explorer, removal of the tooth structure should cease, even if stained dentin remains.

### **Finishing the Enamel Walls and Margins**

The last cutting step in the preparation of the cavity is finishing the enamel walls. This is a process of angling, beveling, and smoothing the walls of the cavity preparation to achieve the best marginal seal possible between the restorative material and tooth structure. The dentist may use burs, diamond stones, or hand-cutting instruments (chisels, hoes, hatchets, and gingival margin trimmers) to complete the walls by removing loose or unsupported enamel to create the strongest possible enamel wall.

### **Cleansing the Cavity**

The final step in cavity preparation is cleansing the cavity. This includes the removal of accumulated debris, drying the cavity, and final inspection before placing restorative materials. All debris must be removed from the cavity, especially on the margins, because deposits left on them subsequently dissolve, resulting in a leak that invites recurrent caries.

Irrigating the cavity preparation with warm water usually removes all debris. Stubborn particles of debris may be removed with a small cotton pellet dampened with water or hydrogen peroxide. Following irrigation and aspiration to remove the debris, the cavity must be dried thoroughly with pressurized air from the 3-way syringe or dry cotton pellets.

## Placement of Restorative Materials

After the cavity preparation is completed, your attention as the assistant is especially critical. You must rapidly anticipate each step in the procedure to have the necessary material ready at the proper time. You must prepare and pass restorative materials, mix them at the right time, and follow the manufacturer's instructions. More instruments are needed to place the restoration than to prepare the tooth; therefore, more instrument transfers are necessary and occur more rapidly than in cavity preparation. Once the restorative materials have been placed in the oral cavity, the dentist then begins to finish the restoration.

**CAVITY LINERS AND BASES.**—Most dentists use some type of cavity liner or base in almost all cavity preparations. They are used primarily to **protect the pulp and to aid the pulp in recovering from irritation resulting from cavity preparation.** Liners and bases are placed when the cavity preparation is completed, just before insertion of the restorative material.

Glass ionomer cements and dentin bonding agents are used primarily to seal the dentin and protect the pulp from bacterial invasion. Calcium hydroxide can be used in extremely deep areas as an antibacterial agent and/or as a pulp capping material.

Most bases are applied best when the assistant wipes the instrument clean between each small application. You will hold a gauze sponge in the transfer zone and quickly wipe the end of the instrument as the dentist moves toward the base mix. If the dentist inadvertently gets the base on the enamel walls of the cavity preparation, you will pass an instrument for removal of the material.

Cavity varnish is a liner used to seal the dentinal tubules to help prevent microleakage and is placed in a cavity to receive amalgam alloy after any bases have been placed. Cavity varnish is being used less and less with amalgam restorations, and dentin bonding agents are replacing cavity varnish as the liner of choice. Cavity varnish has an organic solvent of ether or chloroform that quickly evaporates, leaving the resin as a thin film over the preparation. This varnish should be slightly thicker than water. If it becomes very thick, discard it. Cavity varnish is **not used** with composites since the varnish retards the set of composites and interferes with the bonding of composites.

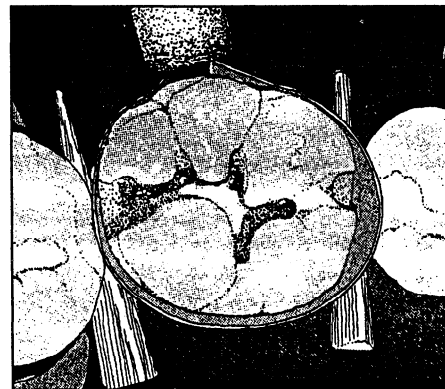
A small cotton pellet held by cotton forceps is dipped into the varnish just enough to wet the pellet.

The cavity varnish is applied to the pulpal area, walls of the cavity preparation, and onto the edge of the margins of the preparation. Any excess varnish can be removed from the enamel with a fresh cotton pellet. A second application of cavity varnish is placed over the first to thoroughly coat the surfaces of the dentin and fill any voids from bubbles created when the first application dries. After liners and bases are placed into the cavity preparation, the tooth may be restored with materials, such as amalgam, composite resin, or glass ionomer.

**AMALGAM RESTORATIONS.**—Amalgam is used as a restorative material on the surfaces of both permanent and primary teeth. Amalgam also is aesthetically acceptable for distal restorations of the cuspid when the restoration is not readily visible. Amalgam can also be used to prepare a sound base for a tooth before the preparation of a full artificial crown. This is commonly referred to as an amalgam buildup.

When multiple surfaces of the tooth are removed during the cavity preparation, a matrix is required to approximate the original wall and hold the restorative material in proper form and position until it sets. During the final stages of the cavity preparation, if not sooner, you should acknowledge the need for the matrix band and assemble it. While the liner and base materials set, the dentist places the assembled matrix band and retainer around the tooth, along with wedges if needed. Figure 4-38 illustrates a properly contoured and wedged matrix band.

While the dentist makes the final adjustments to the matrix, you will need to ensure the precapsulated amalgam is placed securely in the amalgamator and ready to triturate (mix). The operation and maintenance of the amalgamator is discussed in chapter 11, Volume 1, under Dental Equipment. Wait for a signal from the dentist to begin mixing the



DTV2/438

Figure 4-38.—Properly contoured and wedged matrix band.

amalgam. When the amalgamator stops, remove the amalgam capsule for the amalgamator, open the capsule, and empty the mixed amalgam into the amalgam well. Use caution with the amalgam mix because any moisture contamination causes the finished restoration to expand. Load the amalgam into the amalgam carrier (fig. 4-39). Some dentists permit the assistant to dispense the amalgam into the cavity preparation. Other dentists prefer to have you pass the loaded amalgam carrier and dispense the amalgam themselves. In either case, you must pass the amalgam condenser to the dentist. The dentist uses the condenser to pack the amalgam firmly into all the areas of the prepared cavity. During the condensing procedure, the dentist indicates when a change of condensers is needed. As you gain experience, you will know when a change is needed by observing the stage of completion. The exchange of amalgam carrier and condensers continues until the cavity preparation is slightly overfilled. When the condenser is used for the last time, the dentist may use a burnisher and or an explorer on the restoration before removing the matrix band.

The dentist uses a burnisher to bring any excess mercury from the amalgam placed to the top of the restoration. Next the explorer is used to slightly contour the restoration between the tooth and the band before removal of the matrix and retainer. For dentists who choose to initially carve the occlusal anatomy into the restoration before removal of the matrix, have an amalgam carver ready to pass when you receive the explorer. You will also need to have the cotton forceps

or hemostat ready to pass when the dentist is ready to remove the wedge, retainer, and matrix band.

The dentist uses an interproximal carver to smooth the gingival margin of the amalgam restoration at the interproximal area. Only the excess amalgam is removed near the gingival margin to allow the proximal contact to be retained. The dentist continues carving the proximal surfaces to conform to the contour of the inter-proximal area of the tooth. The dentist uses another carver, such as the discoid-cleoid, to carve the primary grooves on the occlusal surface and remove excess amalgam. You may need to have another carver ready to pass to the dentist to carve the facial and lingual margins of the amalgam, if applicable. In addition to passing and receiving a variety of carvers to the dentist, you will need the high-volume evacuator (HVE) tip in your other hand to aspirate the shavings from the carving procedure at various times. When carving the amalgam restoration is completed, remove the rubber dam. Irrigate and aspirate the patient's mouth and check the occlusion of the new restoration for any needed adjustments.

Have the articulating paper ready for use by placing it into a hemostat or articulating paper holder. Pass this to the dentist to check the occlusion of the restoration. The articulating paper is placed in the teeth of the opposing quadrant and the patient is instructed to gently close the teeth together. If the patient closes the teeth together too suddenly or with too much pressure, the new amalgam restoration will fracture if it is too high. Have an amalgam carver ready to pass to the dentist to reduce any high spots on the amalgam restorations. The restoration is checked with the articulating paper and carved until the proper occlusion is obtained. Have a burnisher, such as a ball or ovoid, ready to pass to the dentist to burnish the amalgam restoration. When the restoration is completed, the oral cavity is irrigated and aspirated using the water syringe. Use the HVE to remove amalgam shavings resulting from the occlusal adjustment. Before dismissal, ensure the patient is given the postoperative instructions and understands them.

**MERCURY CONTROL PROGRAM FOR DENTAL TREATMENT FACILITIES.**—All dental personnel will follow BUMEDINST 6260.30 because of the health hazard potential of mercury. This instruction discusses control procedures for the handling and disposal of amalgam or mercury-contaminated items and is discussed in Volume I, Chapter 11, "Dental Safety and Equipment."

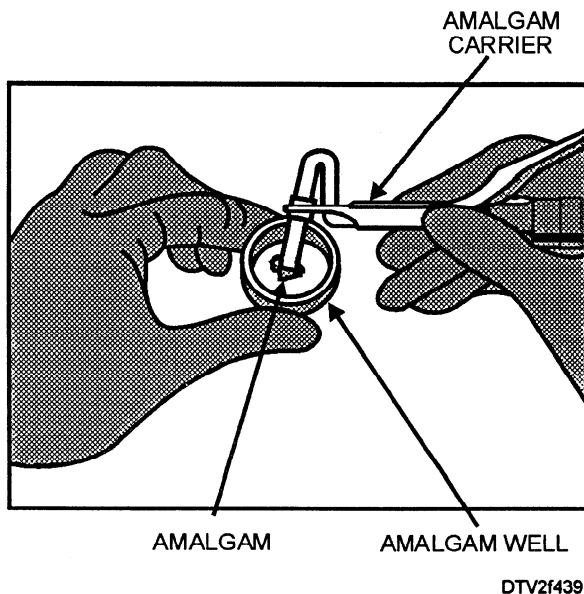


Figure 4-39.—Loading amalgam into the amalgam carrier from amalgam well.

**FINISHING AND POLISHING AMALGAM RESTORATIONS.**—When amalgam restorations are placed in the tooth, finishing and polishing of the restorations generally take place at another appointment. The appointment should be at least 24 hours after the placement of the amalgam. Polishing the amalgam smooths the surface so that plaque does not adhere to it readily and makes the restoration look more attractive. The dentist checks the margins and proximal contacts of the restoration initially. A metal filing strip can be used to remove any roughness or overhand of the restoration in the proximal area. The dentist may use finishing burs or stones in the handpiece, followed by discs and abrasive points. Before use, discs may be coated with a lubricant, or in some cases, wet with water. The abrasive points progress from a more-abrasive to a less-abrasive point until a smooth mirror-like surface is obtained on the amalgam restoration. Extra-fine pumice and dry tin oxide, or commercial silicone-mounted polishing cups, may be used for a final polishing.

**COMPOSITE RESIN RESTORATIONS.**—The restoration of tooth surfaces that are normally easily visible are restored with tooth-colored restorative materials for an esthetic appearance. One of the most commonly used tooth-colored restorative materials is the composite resin. The three types of composite resins available are

- macrofilled,
- microfilled, and
- hybrid.

The classification of each composite resin depends on the particle size of its inorganic filler. The macrofilled and hybrid resins have higher amounts of inorganic fillers and lower amounts of organic resin than the microfilled resins. This provides the strength needed for proximal-incisal restorations. These restorations may be prepared with or without the pin retention technique. On the other hand, because microfilled resins have a smaller particle size, they are easier to polish than macrofilled resins. Many of the recently developed hybrids achieve good polishability and esthetics—one reason for their increased popularity.

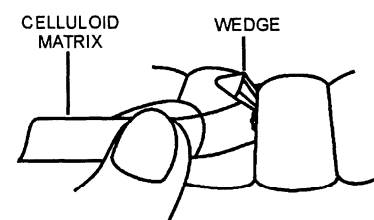
Composite resin materials are available in **self-curing two-paste systems** and **light-curing single-paste systems**. Some brands offer several color selections; whereas, others are supplied in a universal shade. The shade must always be selected before the

teeth are allowed to dry because dehydration results in lighter shades.

The restorative material is retained in the cavity preparation by mechanical retention. Chipped or fractured teeth rely mostly on acid-etch enamel for retention of the restorative material. Acid-etching the enamel portion of cavity preparations with a 35 to 50 percent solution of phosphoric acid results in improved retention for resin restorations. A celluloid matrix may be placed before the acid-etching procedure to protect the adjacent teeth. The phosphoric acid is applied to the enamel surface of the cavity preparation and is allowed to be in contact with the enamel for 1 minute. Then the area is rinsed thoroughly with water and dried. The etched enamel surface, when dried, appears chalky white because of a slight dissolving of the surface enamel that leaves microscopic undercuts (retention). After etching the tooth, a bonding agent is applied.

The dentist may need an instrument to pack the composite resin material into the cavity preparation and to avoid formation of air bubbles. When the composite resin material is applied to the etched and bonded surface, the resin invades the surface void, undercuts, and irregularities. When surfaces in the proximal area are restored, the dentist will place a celluloid matrix that will assist in preventing the composite material from adhering to adjacent teeth and also acts as a form to properly place the material (fig 4-40). If using a light-cured system of composite resin, the light source is positioned near the restoration and exposed according to the manufacturer's instructions. These light-curing systems are discussed in Chapter 11, Volume I, "Dental Safety and Equipment." The dentist, assistant, and the patient should wear protective glasses during the light exposure.

Once the resin material cures, a mechanical bond forms. This type of surface union between the restorative material and the enamel improves the retention qualities and provides a smoother cavity



DTV21440

**Figure 4-40.—Using a celluloid matrix for a proximal composite restoration.**

margin, improving the esthetics of the restoration. In addition, less marginal leakage is likely to occur because of the improved union of the enamel and restoration.

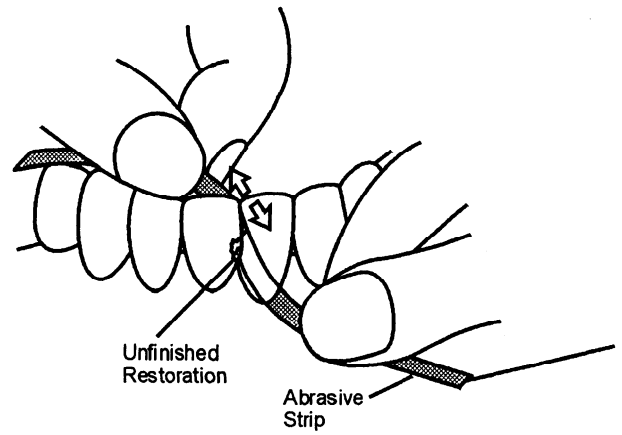
To finish the restoration, the matrix is removed and any rough areas are smoothed with composite-type finishing burs. If the restoration involves proximal surfaces, abrasive strips similar to those shown in figure 4-41 are used to smooth these surfaces. If applicable, the gingival margin of the restoration is checked to remove any excess composite material. The surface of the restoration is smoothed further with a fine and an extra-fine disc of silicon carbide and zirconium silicate. These smooth surfaces prevent retention of food debris or plaque. If a higher gloss of the facial surface is desired, a coating of sealant material is placed over the finished restoration. After completion of the restoration, the rubber dam is removed and oral cavity irrigated and aspirated. If necessary, the dentist checks the occlusion and makes adjustments.

#### **GLASS IONOMER RESTORATIONS.—**

Usually, the gingival areas on the facial aspect of the maxillary anterior teeth are restored with one of the tooth-colored restorative materials for an esthetic appearance. Restorations located on the gingival third of the tooth may be necessary because the tooth is carious or because it has been worn away or abraded by incorrect brushing habits. Since glass ionomer cements bond directly with enamel, dentin, and cementum, they may be used for such restorations where minimal preparation of the tooth is desired, or where the fluoride release from the cement is desired to resist recurrence of caries. During placement of the glass ionomer cement restoration, the cavity area must be kept totally dry because moisture will cause a failure of the restoration.

#### **SUPPLY PROCEDURES**

A competent dental assistant can increase the efficiency, productivity, and reduce the operational



DTV2441.

**Figure 4-41 .-Using an abrasive strip to finish a proximal surface.**

costs in a DTR by using proper supply procedures. It costs time and money to run out of necessary items. It is also wasteful and expensive to order and store items that are never used.

You will use a supply catalog to order supplies. Some facilities make up a catalog for local use, listing frequently ordered items.

To order an item, look it up in the catalog and then fill out the appropriate "request for issue" form. These forms may vary slightly in format but they all require the same basic information. It is important that you fill out the form accurately and completely. It is important to know item nomenclature, identification, and distribution data.

When your supplies arrive, check the items against your order form to ensure you receive the items and quantities that you ordered. Also check broken seals or loose parts. If you discover anything out of the ordinary, notify your supervisor. After supplies have been checked, store them in a manner consistent with the manufacturer's instructions to prevent spoilage or damage.





## CHAPTER 5

# ORAL SURGERY ASSISTANCE

### INTRODUCTION

Oral surgery deals with the surgical treatment or correction of diseases, defects, or injuries of the oral cavity, teeth, and adjacent tissues. A sound knowledge of surgical assisting procedures is essential if you are to be an effective oral surgery assistant.

### ORAL SURGERY FUNCTION

Oral surgery provides surgical treatment or correction of diseases, defects, or injuries of the oral cavity and facial structures. A wide variety of surgical procedures takes place in the oral-maxillofacial surgery area. *Exodontics* is the term used to describe the extraction of teeth in oral surgery. General dentists are trained in surgical procedures; however, they may choose to refer the patient with a more complicated case to an oral surgeon who has specialized training in the area. A maxillofacial surgeon is an oral surgeon who specializes in the reduction of bone fractures and reconstruction of the maxilla or mandible, and performs reconstructive surgery.

### INDICATIONS AND CONTRAINDICATIONS

Before a surgical procedure can be done, the oral surgeon will evaluate each patient's record for indications and contraindications to treatment. Some indications for oral surgery include:

- Carious teeth unrestorable by restorative procedures.
- Nonvital teeth when endodontic treatment is not indicated or has little chance of success.
- Removal of teeth to provide space in the arch for orthodontic treatment.
- Teeth without sufficient bone support.
- Supernumerary or impacted teeth interfering with normal dentition.
- Malpositioned teeth that cannot be aligned.
- Root fragments from prior extractions or surgery.
- Removal of soft-tissue.

- Removal of exostosis (overgrowth of bone), such as torus mandibularis and torus plantinus.
- Accidental fracture or reconstruction of the mandible or maxilla.

The oral surgeon will also evaluate the patient for possible contraindications to surgical treatment. Extractions should be avoided when an active infection is present because local anesthesia is difficult to achieve and the infection can spread to other parts of the body. Patients suffering from any potentially serious disease, such as heart disease, diabetes, and blood disorders, should first be evaluated by a physician to determine if they can withstand the prescribed treatment. Patients in the early stages of pregnancy should have the surgery postponed until they are in the second trimester.

### EXAMINATION AND INFORMED CONSENT

Examination and informed consent are essential to determine what treatment is required, and provide all relevant information to the patient to make an informed decision regarding proposed treatment.

#### Examination

The oral surgeon examines the patient to confirm the findings of the referring dentist and gather any other additional information to make treatment recommendations. Oral surgeons should order radiographs of the teeth, mandible, maxilla, or other facial areas to verify the treatment recommendations if not already taken. The radiographs may include periapical, extraoral of the skull or facial aspects, panoramic, temporomandibular, and occlusal. A comprehensive medical history review is essential for the surgical patient because of the strain surgery places on the body. If there are any questions regarding the patient's health or ability to withstand surgery, the surgeon should consult with the patient's physician before surgery. During the examination, the oral surgeon also discusses appropriate pain-control methods for the surgical treatment recommended, and informed consent with the patient or legal guardian.

**Informed Consent**

Providing proper informed consent is an integral part of appropriate patient-provider relations. Dental providers should make every attempt to disclose all relevant information to the patient or legal guardian in

order for them to make an informed decision regarding any proposed treatment. The Standard Form 522, Request for Administration of Anesthesia and for Performance of Operations and other Procedures (fig. 5-1) should be used when informed consent is required, including the use of intravenous conscious

<b>MEDICAL RECORD</b>	<b>REQUEST FOR ADMINISTRATION OF ANESTHESIA AND FOR PERFORMANCE OF OPERATIONS AND OTHER PROCEDURES</b>	
<b>A. IDENTIFICATION</b>		
1. OPERATION OR PROCEDURE _____		
<b>B. STATEMENT OF REQUEST</b>		
1. The nature and purpose of the operation or procedure, possible alternative methods of treatment, the risks involved, and the possibility of complications have been fully explained to me. I acknowledge that no guarantees have been made to me concerning the results of the operation or procedure. I understand the nature of the operation or procedure to be _____ <small>(Description of operation or procedure in layman's language)</small>		
_____		
_____		
which is to be performed by or under the direction of Dr. _____		
2. I request the performance of the above-named operation or procedure and of such additional operations or procedures as are found to be necessary or desirable, in the judgment of the professional staff of the below named medical facility, during the course of the above-named operation or procedure.		
3. I request the administration of such anesthesia as may be considered necessary or advisable in the judgment of the professional staff of the below-named medical facility.		
4. Exceptions to surgery or anesthesia, if any, are: _____ <small>(If none, so state)</small>		
5. I request the disposal by authorities of the below-named medical facility of any tissues or parts which it may be necessary to remove.		
6. I understand that photographs and movies may be taken of this operation, and that they may be viewed by various personnel undergoing training or indoctrination at this or other facilities. I consent to the taking of such pictures and observation of the operation by authorized personnel, subject to the following conditions:		
a. The name of the patient and his/her family is not used to identify said pictures.		
b. Said pictures be used only for purposes of medical/dental study or research.		
<small>(Cross out any parts above which are not appropriate)</small>		
<b>C. SIGNATURES</b> <small>(Appropriate items in Parts A and B must be completed before signing)</small>		
1. COUNSELING PHYSICIAN/DENTIST: I have counseled this patient as to the nature of the proposed procedure(s), attendant risks involved, and expected results, as described above.		
_____		
<small>(Signature of Counseling Physician/Dentist)</small>		
2. PATIENT: I understand the nature of the proposed procedure(s), attendant risks involved, and expected results, as described above, and hereby request such procedure(s) be performed.		
_____	_____	_____
<small>(Signature of Witness, excluding members of operating team)</small>	<small>(Signature of Patient)</small>	<small>(Date and Time)</small>
3. SPONSOR OR GUARDIAN: (When patient is a minor or unable to give consent) I, _____		
sponsor/guardian of _____ understand the nature of the proposed procedure(s), attendant risks involved, and expected results, as described above, and hereby request such procedure(s) be performed.		
_____		
<small>(Signature of Witness, excluding members of operating team)</small>	<small>(Signature of Sponsor/Legal Guardian)</small>	<small>(Date and Time)</small>
<b>PATIENT'S IDENTIFICATION</b> <small>(For typed or written entries give: Name—last, first, middle; grade; date; hospital or medical facility)</small>	<b>REGISTER NO.</b>	<b>WARD NO.</b>
_____	_____	_____
<b>STANDARD FORM 522 (Rev. 10-76)</b> General Services Administration & Interagency Comm. on Medical Records FPMR 101-11.806-8 522-109		
☆ GPO : 1984 O - 421-526 (184)		
NSN 7540-00-630-8165		

DTRV2063

Figure 5-1.—Request for Administration of Anesthesia and for Performance of Operations and Other Procedures, SF 522.

sedation or general surgery, and certain oral or periodontal surgery procedures. Most routine informed consent can be easily accomplished during the verbal verification of diagnosis and treatment presentation.

## **PAIN AND ANXIETY CONTROL**

When dental surgery is indicated, whether oral or periodontal, there are several pain and anxiety control methods available to make the surgery as smooth as possible and put the patient at ease. The three basic levels of anesthesia are local, conscious sedation, and general. You should review *Dental Technician*, Volume 1, Chapter 7, "Oral Pharmacology," to help you better understand the following information

### **Local Anesthesia**

The primary effect of local anesthetic agents is to penetrate the nerve cell membrane and block the conduction of nerve impulses from the point where the local anesthetic is active. This produces anesthesia in the local area. Local anesthesia, using infiltration, nerve block, or a combination of both techniques, is used in surgery cases to numb the surgery area.

Most dental surgery procedures require two or more injections of a local anesthetic. For this reason, it is a good practice to include two aspirating syringes with each instrument setup. This will let you supply the dentist with a loaded anesthetic syringe for as long as needed with minimum loss of time. Since anesthetic solutions are bitter and there is leakage from the injection sites, you will need to irrigate and aspirate the fluids from the patient's mouth after injection.

### **Conscious Sedation**

Conscious sedation is a minimally depressed level of consciousness that retains the patient's ability to independently and continuously maintain an airway, and respond appropriately to verbal commands. Conscious sedation involves using various drugs or a combination of drugs to achieve pain and anxiety control while maintaining the patient in a conscious state at all times. The common routes of administration of conscious sedation are oral premeditation, inhalation, and intravenous. Local anesthesia is administered with all types of conscious sedation.

### **General Anesthesia**

General anesthesia is a controlled state of unconsciousness accompanied by a partial or complete

loss of protective reflexes, including the ability to maintain an airway independently and respond to verbal commands. General anesthesia renders the patient unconscious through depression of the central nervous system, thus eliminating patient cooperation as a factor. The administration of general anesthesia is performed by an anesthesiologist in the hospital operating room. Local anesthesia is also administered at the treatment site.

## **ORAL SURGERY PROCEDURES**

While there are many oral surgery procedures, some are more commonly performed than others. You should be knowledgeable of those that are commonly performed. In the following paragraphs, we discuss surgical procedures you will need to know.

### **TOOTH EXTRACTIONS**

Tooth extraction is an oral surgery procedure classified into three types: simple, complicated, and impacted extractions. These are explained briefly in the following paragraphs.

#### **Simple Extractions**

Simple extractions involve removal of a tooth or root that does not require bone removal or sectioning. The deciduous (nonpermanent) or permanent tooth extracted is erupted and usually diseased or malposed. Retained roots may be buried in the tissue and not visible in the oral cavity. Retained root tips may be present because of fractured teeth, advanced decay, or any incomplete post-surgical procedure. They can be identified on radiographs.

#### **Complicated Extractions**

Complicated extractions involve removal of a tooth or root that requires surgical sectioning and/or bone removal.

#### **Impacted Extractions**

Impacted extractions involve removal of a tooth that is partially or completely covered by bone and or soft tissue. This extraction may involve tissue incision, excision, or bone removal. Two types of impactions are associated with oral surgery: soft tissue and bony impaction.

- Soft tissue—occurs when the tooth is blocked from eruption due to the gingival tissue. It may be partially erupted with a portion of the tooth visible in the mouth.

- **Bony impaction**—occurs when the tooth is blocked by both bone and soft tissue. The soft tissue must be removed to gain access to the tooth before it can be extracted. The oral surgeon removes the alveolar bone over the impaction using a bur or chisel and mallet. Removal of the bone provides access for elevators or extraction forceps to extract the tooth. A surgical handpiece with a bur may also be used to section the tooth into four pieces and then each piece is removed separately. A commonly performed impacted extraction is the removal of unerupted third molars.

## **ALVEOLOPLASTY**

Alveoloplasty involves contouring the alveolar structures. It may be done in conjunction with multiple surgical extractions to eliminate sharp bone edges that could cause discomfort to the patient, and to provide suitably contoured bone structure for denture fabrication and insertion. An alveoloplasty may also be performed to contour the bone without being in conjunction with extractions.

## **OSTEOTOMY**

Osteotomy literally means cutting away of bone. Osteotomies include maxillofacial surgery performed to modify or correct facial abnormalities, such as protrusion of the mandible or maxilla where the bone is placed as far forward as possible, or retrusion of the mandible or maxilla where the bone is placed as far back as possible. The oral surgeon may also perform an osteotomy on a patient who has a fractured mandible or maxilla. The patient's teeth are splinted to bind them together into one unit using arch bars, elastic bands, and interdental sutures using wire. This keeps the bones in place, while they heal into the correct position. After healing takes place, the splint and wiring are removed.

## **EXOSTOSIS**

Exostosis is the surgical removal of bony growths projecting past the normal contour of a bony surface. It includes **torus mandibularis** often found on the lingual surfaces of the body of the mandible, and **torus palatinus** located on the center of the hard palate. Usually, tori removals are performed to permit fabrication and insertion of dentures, or to improve speaking or eating functions.

## **FRENECTOMY**

A frenectomy is a surgical procedure used to remove a malattached facial or lingual frenum. A

frenum is the tissue that attaches the tongue, cheeks, and lips to the alveolar process of the upper and lower jaw. The malattached tissue restricts movement of the tongue (lingual frenum) or lips (labial frenum). The frenum may be removed, loosened, or repositioned. The excision of the lingual frenum is done to help correct a condition known as tongue-tie. The labial frenum may require surgery to enable better lip movement, and to help prevent large diastemas (spaces) between erupting central incisors. Frenectomies are commonly performed on children.

## **BIOPSY**

A localized area of abnormal tissue is referred to as a lesion. A biopsy is a surgical procedure to remove a piece of tissue from the lesion for diagnostic and microscopic examination. The information obtained from a biopsy procedure assists the dentist in arriving at a diagnosis and predicting the prognosis of the disease. It is common in dentistry to remove both normal and abnormal tissue from the surgical site for comparison.

The tissue specimen should be handled carefully to prevent crushing or tearing. Immediately place it into a specimen bottle containing a sufficient amount of 10 percent of buffered formalin to preserve it. Before submitting the specimen, ensure that the bottle is tightly closed and labeled properly. At a minimum, the label should include the patient's name, age, sex, and the dentist's name, your command's name, and the date of the biopsy. The dentist will include a Tissue Examination, SF-515 Form, with the specimen along with a tentative diagnosis that is sent to an oral histopathology center. If the histopathology report of an oral biopsy has a premalignant or malignant diagnosis, the dentist must notify the patient of the results. Two common biopsy methods used in dentistry are incision and excision methods.

### **Incision Method**

The incision method involves the removal of a sample of the lesion for examination. A wedge-shaped section of the tissue from the lesion along with adjacent normal tissue is removed for comparison. The biopsy site is sutured and the patient is dismissed.

The incision method generally is used when the lesion is large or in a strategic area where complete removal of the lesion would create significant esthetic or functional impairment. Complete surgical removal of the lesion is not indicated until a final diagnosis is

made. If the lesion is not malignant, it is allowed to heal without further surgery. If a laboratory test shows the tissue is malignant, complete removal is indicated.

### **Excision Method**

The excision method involves removal of the entire lesion along with some adjacent normal tissue. This procedure is done on small lesions where complete removal would not create significant esthetic or functional impairment.

### **FOREIGN BODY REMOVALS**

This is the removal of any foreign body, such as a needle, metallic restoration, or pieces of elevators, forceps, or even bullets. Such a removal is considered a surgical procedure. It is not always indicated, and is often left up to the judgment and discretion of the dentist.

### **SEQUESTRECTOMY**

Sequestrectomy procedure involves the removal of devitalized portions of the bone that have separated from the adjacent bone. Often the devitalized portion of bone will work its way partially through the tissue and be sharp and rough.

### **TRAUMATIC WOUND REPAIR**

Simple and complicated wounds of the facial and or oral soft tissues may be repaired and or sutured in oral surgery.

### **INCISION AND DRAINAGE**

Incision and drainage involves surgical inter-vention for drainage of an abscess, cyst, or hematoma. A surgical rubber drain can be sutured in the area to establish drainage.

### **IMPLANTS**

There are several types of surgical implant devices and associated procedures. An **endosseous implant** is a device placed in the alveolar bone to support an oral or facial prosthesis. A **transosteal** or **superiosteal implant** is a device placed to support an oral or fixed prosthesis. A **surgical abutment procedure** involves uncovering the implant and connection of the abutment used in the prosthetic reconstruction of single or multiple teeth.

### **ALVEOLAR OSTEITIS**

After the extraction of a tooth from its alveolus, healing begins immediately when blood oozes into the alveolus and forms a clot. The clot is later replaced by scar tissue and ultimately bone as healing progresses. The blood clot also protects the alveolus from food, air, and fluids. If the blood clot does not form or dislodges from the tooth socket, a painful condition called alveolar osteitis (also known as a **dry socket**) may occur from 2 to 4 days after the removal of a tooth. With the clot missing, healthy granulation is absent and the tissue within the socket appears grayish in color and often presents a foul odor. The patient is usually in severe and persistent pain because of the exposed bone in the open socket. In *Dental Technician*, Volume 1, chapter 6, we describe emergency treatment for this condition.

### **PERICORONITIS**

The procedure for pericoronitis involves the treatment of the gingival tissue surrounding a partially erupted or malposed tooth, that develops painful, localized inflammation. In *Dental Technician*, Volume 1, chapter 6, we also describe emergency treatment for this condition.

### **SURGICAL INSTRUMENTS**

Many surgical instruments are used in both oral surgery and periodontic procedures. All surgical instruments are made of high-grade steel, either stainless or chrome-plated. Each instrument has a particular purpose and should be handled with extreme care. The instruments with cutting edges must be kept sharp to prevent slippage. Hinged instruments should be lubricated with a milk bath and sterilized in the wide open position to keep them in good operating condition and to prevent rusting.

### **MISCELLANEOUS SURGICAL INSTRUMENTS**

No matter what kind of dental surgery is being performed, some miscellaneous instruments will almost certainly be required. Among these are surgical suction, retractors, scalpels, suture needles and materials, and surgical scissors. A few other instruments, such as mouth props, mouth gags, and a surgical mallet, will also be included with the miscellaneous surgical instruments.

## Surgical Suction Apparatus

Whenever a surgical procedure is performed, sterile instruments are essential. Since it is not possible to sterilize all parts of the suction apparatus attached to the dental unit, it is necessary to modify it with a sterile surgical suction apparatus. In some cases, you may use a mobile suction unit that also uses similar items. These items are composed of the hose, handle, and tips. The hose is used to connect the handle to the suction apparatus and has a sterile tubing that is available in various lengths. The handle has a bulbous portion on one end and a chuck on the other end. The bulbous portion is slipped into one end of the hose, and the chuck holds the tips. There are several tips available ranging from #1 to #4. The smaller #2 is suitable for use in a tooth socket. When these parts are properly joined and the loose end of the tubing is connected to the suction, they function as a single suction unit (fig. 5-2). Your job is to connect the parts, operate the suction, and manipulate the handle and tip. With experience, you should be able to perform these tasks quickly and efficiently to keep the surgical site clear for the dentist.

### Retractors

There are different kinds of retractors, but the purpose is the same for each. Retractors are used to hold back objects in the oral cavity.

**TISSUE RETRACTORS.**—In oral surgery, tissue retractors hold tissue flaps away from the treatment site to provide better visibility. Some retractors have forklike prongs, as shown in figure 5-3. This allows the handling of the tissue without causing excessive damage.

**TONGUE AND CHEEK RETRACTORS.**—These retractors are designed to hold and retract the cheeks, tongue, or a portion of the mucosa during




Figure 5-3.—Tissue retractors.

surgical procedures. The retractors are made of metal or plastic, and may be large, curved, or angled. A commonly used retractor is the Minnesota retractor, shown in figure 5-4, which is a bent, angled piece of steel.

### Mouth Props and Gags

Mouth props and gags hold the patient's mouth open mechanically. The mouth prop, shown in figure 5-5, is a solid piece of rubber, whereas the mouth gags



DTBV2065

Figure 5-4.—Minnesota tongue and cheek retractor.


- 1 COUPLAND TIP
- 2 COUPLAND TIP
- 3 COUPLAND TIP
- 4 COUPLAND TIP

WITH INTERCHANGEABLE TIPS  
WITH OR WITHOUT SIDE HOLES.



DTBV2064

Figure 5-2.—Surgical suction handle and tip.



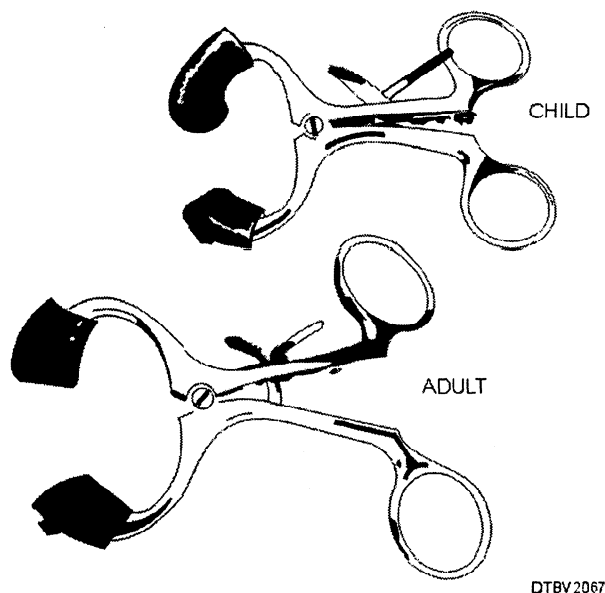
DTBV2066

Figure 5-5.—Mouth prop.

(fig. 5-6) are lock-type forceps with rubber-covered extensions. The rubber provides protection against injury to the enamel of the teeth. The use of mouth props and gags is by no means limited to surgery. They are also commonly used in restorative and pediatric dentistry when patients have difficulty keeping their mouths open during the procedure.

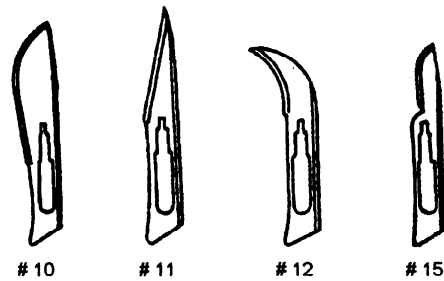
### Surgical Scalpels

Surgical scalpels are composed of handles and blades used to incise or excise soft tissues, and come in various sizes and shapes. The use of each type depends upon the type and accessibility of the tissue to be cut. The blades come in presterilized packages and should be discarded after one use. Attach and remove the blades from the handles with hemostatic forceps. This prevents accidental cuts and possible infection. The two commonly used surgical scalpel handles are the #3 and beaver style. Each handle uses a different kind of blade and attachment method.



DTBV2067

Figure 5-6.—Mouth gags.



DTBV2069

Figure 5-7.—Scalpel Handle #3 and blades.

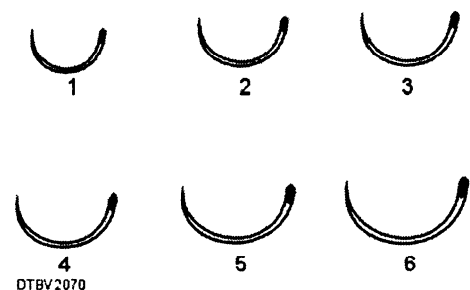
The #3 handle, shown in figure 5-7, is short and wide; it uses a slotted blade that slides onto the handle. The four blades most often used with this handle are the #10, #11, #12, and #15. Blades #10 and #15 have similar working ends. The greatest difference is that the #10 blade is longer. The cutting edge on both of the blades is on the curved part of the blade.

### Suture Needles and Materials

Suture needles and materials are packaged in sterile packs with the needles and have already been attached to the suture material. There is a wide variety of both needles and suture materials.

**NEEDLES.**—Most suture needles used in dentistry are semicircular. They have either smooth sides or cutting sides, and vary greatly as to the diameter of the semicircle, as shown in figure 5-8. The smaller sizes are used most often because of the limited space in the oral cavity.

**MATERIALS.**—Dentists use suture material with a suture needle to close wounds in and around the oral cavity. Suture materials are usually classified as either **absorbable** or **nonabsorbable**. Almost all sutures used in oral surgery are nonabsorbable. These sutures must be removed after the wound heals enough to hold together. Absorbable sutures are dissolved and



DTBV2070

Figure 5-8.—Suture needles.

absorbed in the body. Examples of absorbable sutures are the natural (plain and chromic) gut and synthetic types.

A variety of materials are used to make nonabsorbable sutures. Some of these are silk, cotton, nylon, polyester, and corrosion-resistant steel wire. The most common suture material used in oral surgery is made of silk.

All of these suture materials are available in different diameters. The smaller the number, the larger the diameter of the suture material. The 3-0 size is commonly used in periodontal surgery. The most commonly used suture material for oral mucosa is the 4-0 silk. To suture facial lacerations, the 5-0 suture size is commonly used.

**WOUND CLOSURE.**—When assisting with wound closures, grasp the suture needle with the needle holder approximately one third of the way between the eye of the needle and the needle point, and pass it to the dentist. When the needle is inserted into the tissue, the dentist may require you to hold the tissue firmly with tissue forceps.

As each suture is tied, the dentist may have you cut the suture above the knot with surgical scissors, being careful not to cut it too short, since this may cause the suture to come untied.

### Surgical Scissors

Scissors are used in dental surgery to cut tissues and sutures. The scissors used to trim excess or irregular soft tissues have one serrated blade to eliminate slippage. Those with smooth blades are normally used for cutting sutures or other fabric materials. Figure 5-9 illustrates the Dean surgical scissors. Many types of surgical scissors are commonly used such as the Kelly curved or sharp, Mayo curved or straight, and the Iris curved or straight.

### MISCELLANEOUS SURGERY FORCEPS

With the exception of the rongeur forceps, which are used to cut bone, most forceps are grasping-type



DTBV2071

Figure 5-9.—Dean surgical scissors.

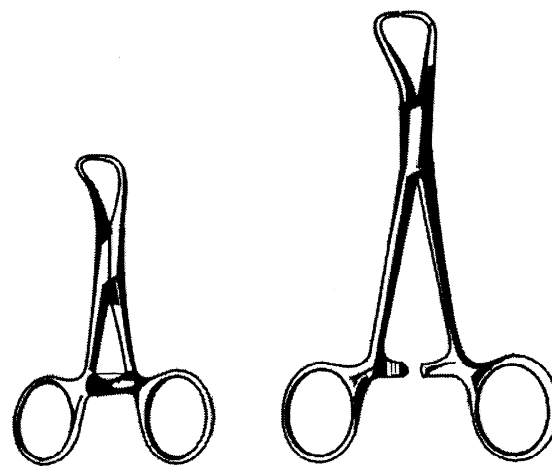
instruments. The forceps that secure patient towels and drapes, hold suture needles, control hemorrhage, and grasp oral soft tissues are commonly used in most dental surgeries. We will consider them a miscellaneous group for our purposes.

### Towel-Clamp Forceps

Towel-clamp forceps (fig. 5-10) are used to maintain surgical towels and drapes in the correct position during an operation. The working ends may have either sharp points or blunt flat tips that overlap in the closed position.

### Needle-Holder Forceps

Needle-holder forceps hold needles during suturing procedures. The typical needle holder has two short, rather blunt, serrated beaks with a distinct groove in each beak (fig. 5-11). The grooves provide space for the placement and retention of the needle. At the end of the handles, there is a graduated, notched-locking device that lets the dentist secure the suture needle in the suturing position as if the needle were an extension of the needle holder.

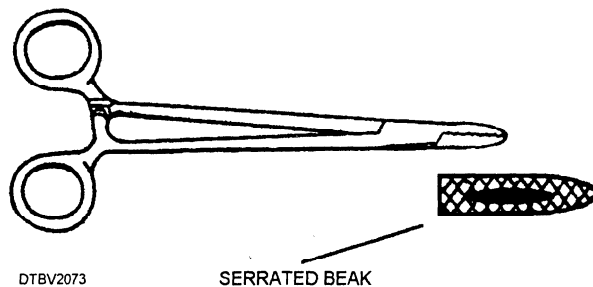


SMALL

DTBV2072

LARGE

Figure 5-10.—Small and large towel-clamp forceps.



DTBV2073

SERRATED BEAK

Figure 5-11.—Needle-holder forceps.



## Hemostatic Forceps

Hemostatic forceps (fig. 5-12) look very much like needle-holder forceps. The main difference is that the beaks of the hemostatic forceps are longer and more slender. They also have both curved and straight beaks, and there is a locking device on the handle to keep the beaks closed. These forceps are used in surgery to control hemorrhage by clamping or constricting blood vessels. In dental surgery, they are more commonly used to remove bits of debris, such as bone chips or parts of teeth, from the oral cavity.

## Tissue Forceps

Tissue forceps (fig. 5-13) look like cotton forceps, but they have two very small, sharp-pointed extensions that form a W-shape when in the closed position. Although the tissue forceps are used in oral surgery to grasp and stabilize loose tissue ends during suturing procedures, they are mainly used to hold tissue being excised.

## CUTTING INSTRUMENTS USED IN DENTAL SURGERY

When most people hear the word "surgery," the first thing they think about is the cutting of the body

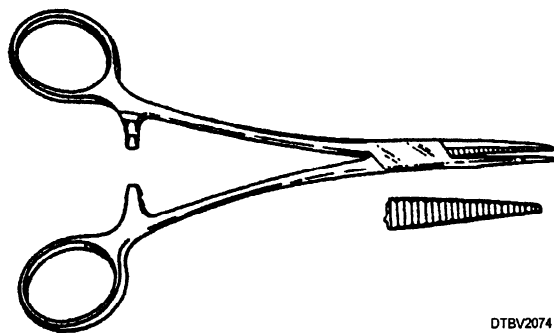


Figure 5-12.—Hemostatic forceps.

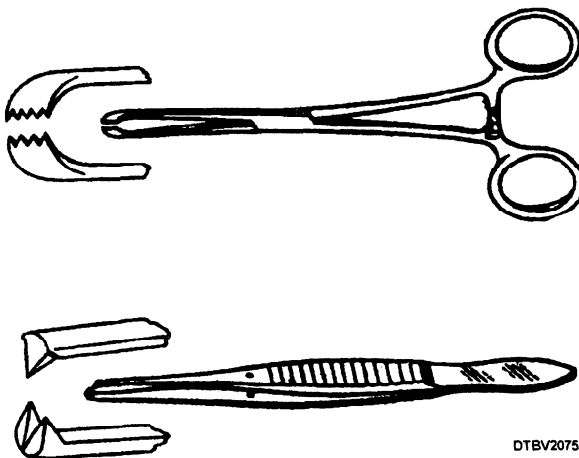


Figure 5-13.—Tissue forceps.

with scalpels. Scalpels are not the only cutting instrument used in surgery, particularly dental surgery; for instance, curettes, chisel, rongeur forceps, and bone files are also used in some cutting functions.

## Surgical Curettes

While surgical curettes are not strictly cutting instruments, they must do some cutting. Curettes are sharp, spoon-shaped instruments used to clean out infected cavities in bone and remove debris from the tooth sockets. They come in many sizes and in straight or angled shapes. The type used depends on the nature of the socket, curvature of the roots that were in the socket, and the location of the cavity. The single-ended Molt curettes have large handles. They are the straight #2 and #4 and the paired, angled #5L and #6R (L for left, and R for right). They are shown in figure 5-14. Other curettes in dental surgery may be double-ended and have slender handles.

## Surgical Chisels

Surgical chisels may also be classified as cutting instruments. Like surgical burs, chisels are used to remove bone and to split teeth. Because their cutting




Figure 5-14.—Single-ended surgical curettes.

edges are easily dulled, you must sharpen them after each use. Surgical chisels are much larger than enamel chisels used in restorative dentistry. The surgical mallet (fig. 5-15) is used along with a selected chisel to split teeth or reduce alveolar bone.

### Rongeur Forceps

Rongeur forceps (fig. 5-16) are used to trim projecting, uneven, or overhanging bone (alveolectomy), usually after multiple extractions and before tissue suturing. It has a steel spring spreader, which opens the beaks when pressure is released from the handles.

### Bone File

Although most of the bony projections are removed with the rongeur forceps, some rough edges usually remain. The bone file (fig. 5-17) may be used to further shape and smooth the alveolar bone. They are double-ended instruments, with both large and small working ends.




Figure 5-15.—Surgical chisels and mallet.

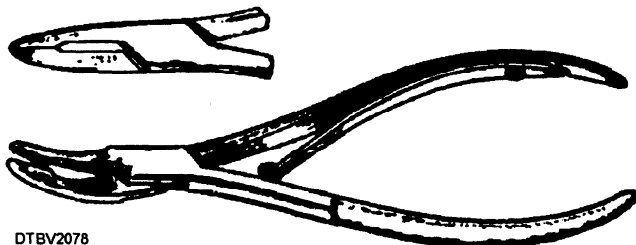


Figure 5-16.—Rongeur forceps.




Figure 5-17.—Bone file.

## SURGICAL ELEVATORS

Three types of surgical elevators are used in oral surgery: the periosteal, root, and malar. Root picks are classified as root elevators and will also be discussed.

### Periosteal Elevators

During surgery the dentist often needs to separate a bone or tooth from the fibrous membrane, called the *periosteum* that covers it. This is done with a periosteal elevator. The dentist may also use it to gain access to retained roots and surrounding bone. Two periosteal elevators are the Molt #9 and Seldin #23 shown in figure 5-18. The Molt #9 is used exclusively as a periosteal elevator. The Seldin #23, because of its wide working ends, is also used as a retractor.

### Root Elevators

Root elevators come in many sizes and shapes. At least one (and sometimes more) is used in every tooth extraction. Which elevator or elevators that are used will depend upon the desire of the dentist. A root elevator has three functions:

- To loosen the teeth in their sockets.
- To remove parts of teeth (broken root tips or retained roots).
- To remove a complete tooth.


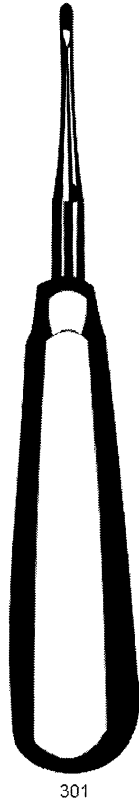


Figure 5-18.—Periosteal elevators.

In the last case, the tooth is usually an underdeveloped third molar. The elevators are actually levers. The fulcrum (support point) for the elevator is usually the bone supporting the tooth.

**STRAIGHT ROOT ELEVATORS.**—The elevators composing the straight working end group are the #301 and the #34S (figs. 5-19 and 5-20). The



301  
DTBV2081

Figure 5-19.—Root elevator #301.



34S  
SELDIN  
DTBV2082

Figure 5-20.—Root elevator #34S.

working ends are in line with the handle and have a concave surface. The #301 has the smallest working end and is used when roots are deeply seated. The #34S has the largest end and is commonly used for anterior roots. The #92, shown in figure 5-21, also has a straight working end; however, it is serrated and the shanks are angled rather than straight as in the #301 and #34S.

**SPADE/WEDGE-TYPE ROOT ELEVATORS.**—Another style of elevator has spade or wedge-type working ends. The Stout #11 (fig. 5-22) and the Cogswell A (fig. 5-23) are examples of this style. The Cogswell B, also shown in figure 5-23, is a pick-shaped root elevator that has a working end shaped similar to a rounded toothpick tip.

**ANGLED-TYPE ROOT ELEVATORS.**—In several sets of elevators, the handles are in line with the shank, but the working ends are set at an angle. The



92  
SERRATED

DTBV2083

Figure 5-21.—Serrated root elevator #92.



11  
STOUT  
DTBV2084

Figure 5-22.—Stout #11 root elevator.

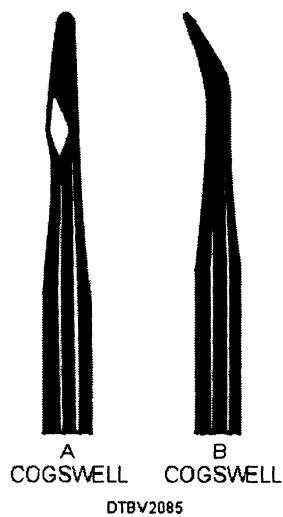


Figure 5-23.—Cogswell A and B root elevators.

Miller #73 and #74 elevators, shown in figure 5-24, have curved, thin working ends with smooth, rounded tips. These elevators are designed to elevate a tooth or large root fragment. The Seldins #1L and #1R, shown in figure 5-25, have sharp-tipped working ends with an abrupt 90-degree angle. The Seldins, sometime referred to as *East- West* elevators, are designed for use on molar roots. The Cryer #25 and #26 are similar to the #1L and #1R Seldins; however, the working ends are angled at angles greater than 90 degrees (fig. 5-26).

**APICAL ROOT TIP PICK ELEVATORS—**

This group of elevators are used to remove fractured root tips lodged deep in the root socket. These elevators are often called *root picks*. Elevators that make up this group are the #5 and #6 West, and the #9 apical, #9L, and #9R. The working ends on these elevators are very thin, sharply pointed, and small. The

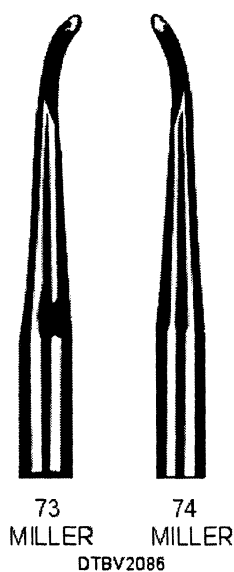


Figure 5-24.—Miller root elevators.

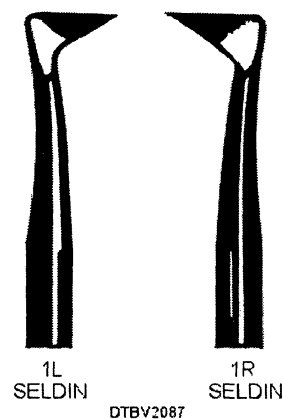


Figure 5-25.—East-West (Seldin) root elevators.




Figure 5-26.—Cryer root elevators.

#5 and #6 West, shown in figure 5-27, have much shorter shanks and are designed to remove extremely small apical fragments. The #9L and #9R are set at left and right angles to the handles (fig. 5-28). The handles are also small in diameter but longer than those on other elevators discussed earlier.

**Malar Elevator**

The facial bone that forms the cheek is called the zygoma or malar bone. An injury to this bone often causes a depressed fracture. If this occurs, the dentist will use a malar elevator to raise the bone to its normal position.

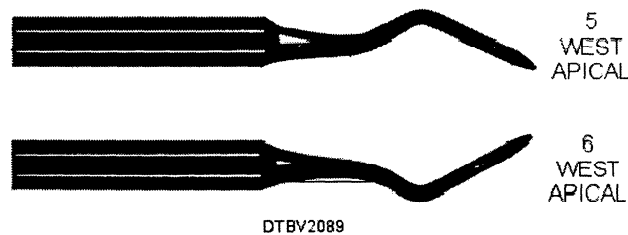


Figure 5-27.—Apical root tip picks (#5 and #6 west).

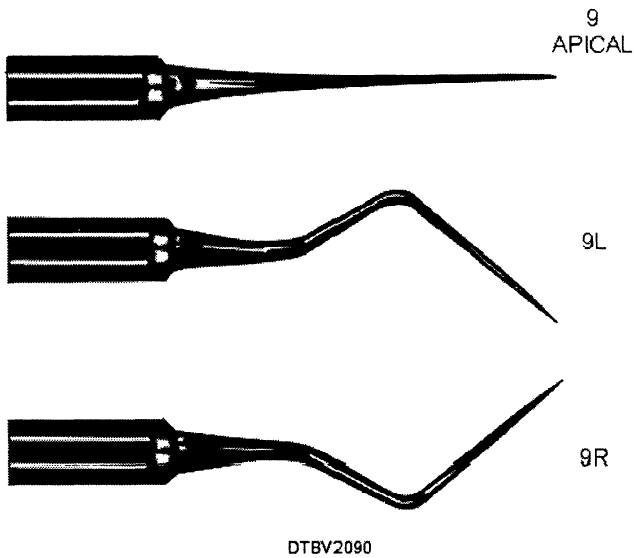


Figure 5-28.—Apical root tip picks (#9L and #9R).

### TOOTH EXTRACTION FORCEPS

There are several types of tooth extracting forceps. Except for those made for some specific operation, they generally have the same features: beaks, a neck, and handles, as shown in figure 5-29. The beaks of tooth extracting forceps are designed to grasp the tooth with maximum contact on the facial-lingual surface of the root(s) just below the cervix. The inner surface of each of the two beaks is concave and the outer surface is convex.

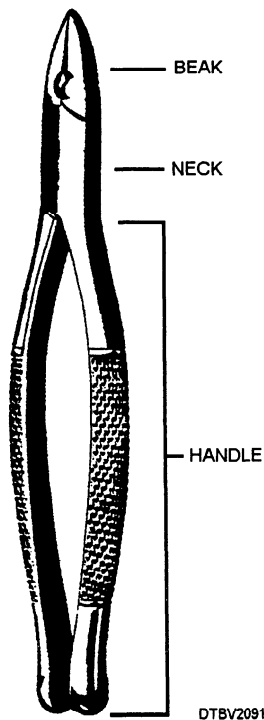


Figure 5-29.—Parts of forceps.

Tooth extracting forceps are designed for use in specific areas of the mouth. The beak is always shaped to conform snugly to the contour of the tooth. For example, both beaks of maxillary forceps are usually angled **away** from the curvature of the handles. These varying angles make it easier to reach various parts of the arch. The beaks of mandibular forceps are usually at a much sharper angle and in the **same** direction as the curvature of the handles. This makes it easier to reach different parts of the lower arch.

Another way of identifying the general area of the mouth in which tooth extracting forceps should be used is by its **neck**. The neck is shaped so that the beak can be placed on the tooth and still be parallel with the long axis of the tooth. The handles are shaped so that a maximum amount of force can be applied to the beaks, while the handles are still in a comfortable position for the oral surgeon. The beaks are also shaped so that a force on the handles tends to force the tooth out of its socket.

The overall shape of the forceps, from the beak to the handle, can usually provide quick identification of the arch for which it's designed. The **S**, **I**, and **Z** shaped forceps are used on the maxillary arch (fig. 5-30). Forceps which are **C** and **L** shaped are used on the mandibular arch (fig. 5-31).

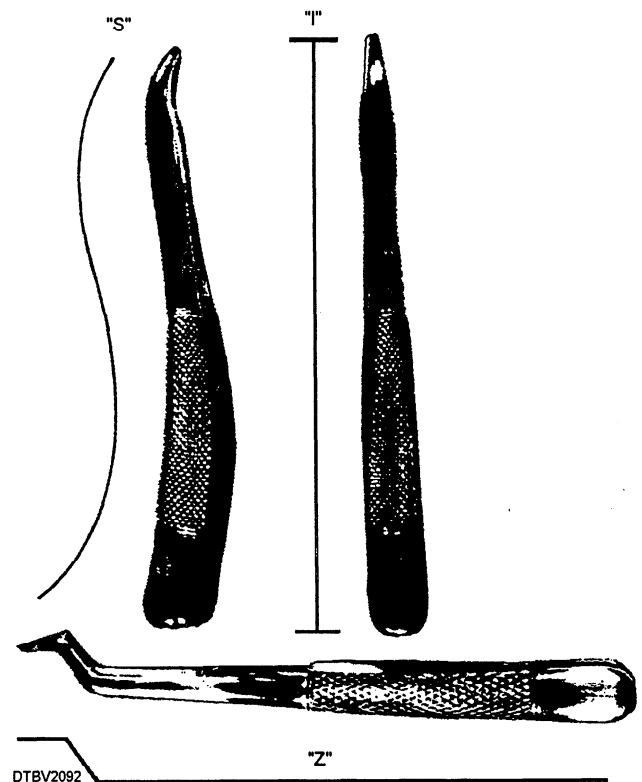
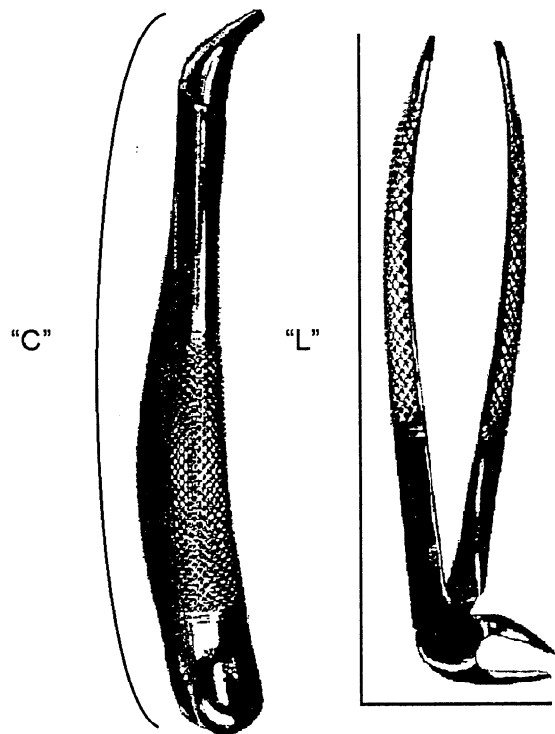


Figure 5-30.—Maxillary shaped extraction forceps.



DTBV2093

Figure 5-31.—Mandibular shaped extraction forceps.

Dentists and oral surgeons will select forceps that are the most comfortable and provide the best results. So you can better assist during oral surgery procedures, you need to know where particular forceps are used. We will cover some of the more common tooth extracting forceps and where they are used in the mouth.

### Maxillary, Incisors, Cuspids, and Bicuspid

Some of the more commonly used extraction forceps designed for use in maxillary, incisor, cuspid, and bicuspid areas of the mouth include the #1, #65, #150, and #286.

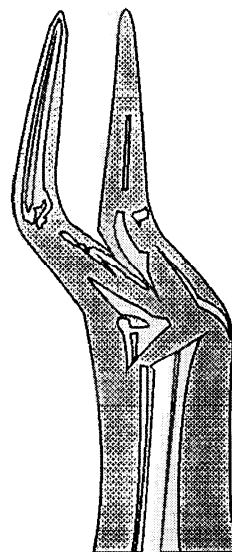
**FORCEPS #1.**—Forceps #1 are used to remove maxillary incisors and cuspids. The beaks (grasping parts) are in line with the handle (fig. 5-32). Because of the straight line design, a dentist can exert a lot of leverage.

**FORCEPS #65.**—Forceps #65 are used on overlapping maxillary incisors and root tips. The handles of the #65 forceps are straight and the beaks are offset (fig. 5-33). When the forceps are closed, they resemble a bayonet. The beaks are short, very narrow, and slender.



# 1  
DTBV2094

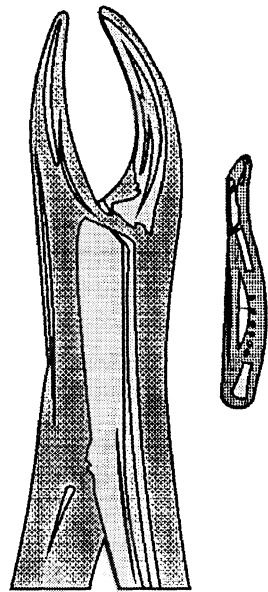
Figure 5-32.—Forceps #1.



# 65  
DTBV2095

Figure 5-33.—Forceps #65.

**FORCEPS #150.**—The Forceps #150 are sometimes referred to as maxillary universal forceps. Even though the #150 forceps can be used in any region of the maxillary arch, they are specifically designed to remove maxillary incisors, cuspids, bicuspid, and residual roots. The beaks are set at an angle to the handles, which makes them accessible to any part of the maxillary arch (fig. 5-34). When the handles are closed, the beaks are noticeably close



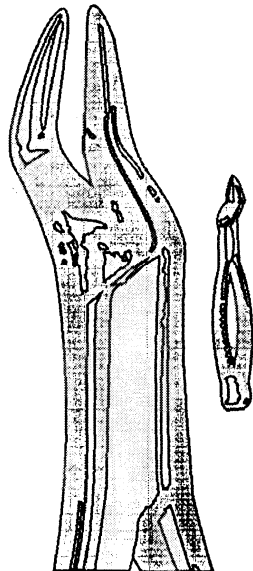
#150

DTBV2096

Figure 5-34.—Forceps #150.

together at the tips and curve opposite each other to resemble "parentheses."

**FORCEPS #286.**—Forceps #286 are similar to forceps #65. The biggest differences are that the #286 beaks are wider, and there is a wider space between the beaks nearest the handles when they are closed. These characteristics make the #286 (fig. 5-35) a little more suitable than the #65 for removing maxillary bicuspid. The #286 also is used to remove maxillary incisors and residual roots.



#286

DTBV2097

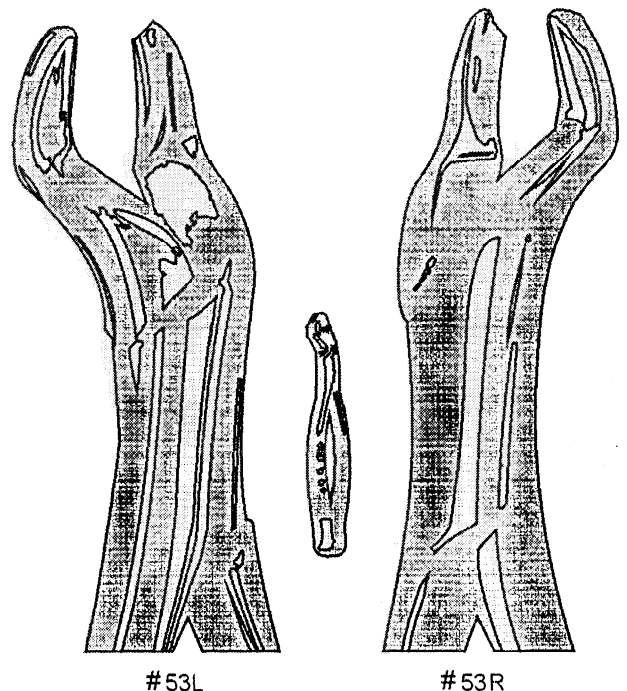
Figure 5-35.—Forceps #286.

## Maxillary Molars

Extraction forceps for maxillary first and second molars are designed as left and right forceps because these teeth are trifurcated. Some of the commonly used forceps for these teeth are the #53L, #53R, #88L, and #88R. Forceps designed for third molars include the #210H and #210S.

**FORCEPS #53L AND #53R.**—Forceps #53L and #53R are used to extract maxillary first and second molars. The letters "L" and "R" indicate that the forceps are used on the left and right sides of the maxillary arch. They have straight handles with offset bayonet-type beaks (fig. 5-36). The design lets the dentist grasp the tooth securely for rocking and elevating movements.

**FORCEPS #88L AND #88R.**—Forceps #88L and #88R are often called *cowhorns*. Like the #53L and #53R, they are used on the maxillary first and second molars. They differ slightly from the #53L and #53R in the way they remove a tooth. The primary use of the #53L and #53R forceps is to grasp the crown and root portion of a tooth so the dentist can rock the tooth from its socket. The #88L and #88R forceps (fig. 5-37) operate on a wedging principle. They are inserted between the tooth and roots and the surrounding bone. The wedging action of these straight handled forceps lifts the tooth from its socket.



#53L

DTBV2098

#53R

Figure 5-36.—Forceps #53L and #53R.

## Mandibular Incisors, Cuspids, and Bicuspid

Two commonly used extraction forceps for the mandibular anteriors and bicuspid are the #151 and #203.

**FORCEPS #151.**—Forceps #151 are used primarily to extract mandibular anteriors, bicuspid, and roots and are often known as the mandibular universal forceps. These forceps are similar to the #150 forceps except the beaks are set at an angle opposite to the slightly curved handles (fig. 5-39).

**FORCEPS #203.**—Forceps #203 are used on mandibular anterior, bicuspid, and roots. These forceps are like the #101 (mentioned later), except the beaks are more sharply angled from the handles. Like the #101 handles, the #203 handles are straight (fig. 5-40).

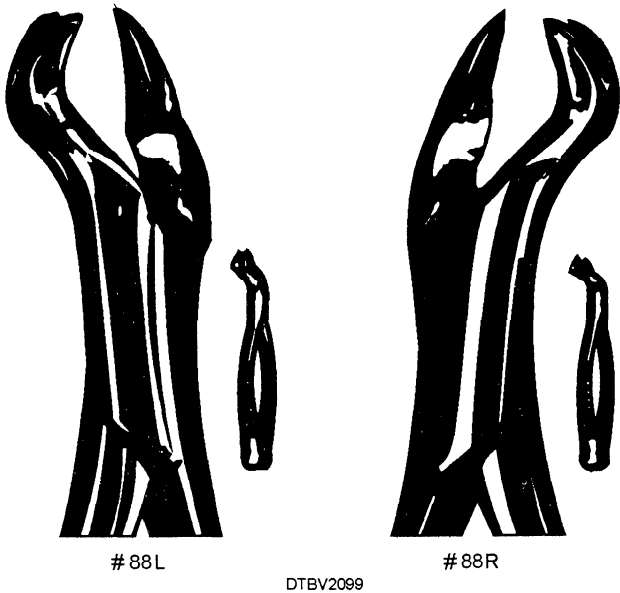


Figure 5-37.—Forceps #88L and #88R.

**FORCEPS #210H AND #210S.**—Forceps #210H and #210S are used to remove maxillary third molars (fig. 5-38). The #210H has short beaks and smooth rounded tips and a wide concave inner surface. The end of the left handle is noticeably curled to form a finger rest. The #210H is particularly effective in grasping the generally underdeveloped maxillary third molar crowns. The #210S forceps have a slightly wider beak than the #210H, and there isn't a finger rest curl. It is also used to extract maxillary third molars.

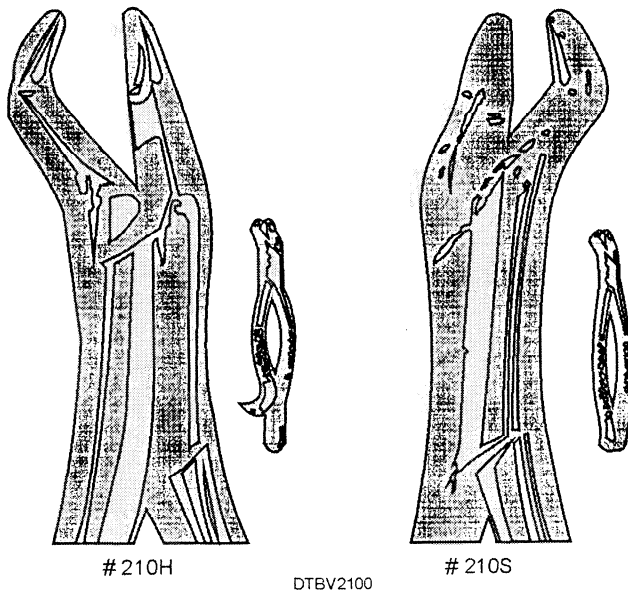


Figure 5-38.—Forceps #210H and #210S.

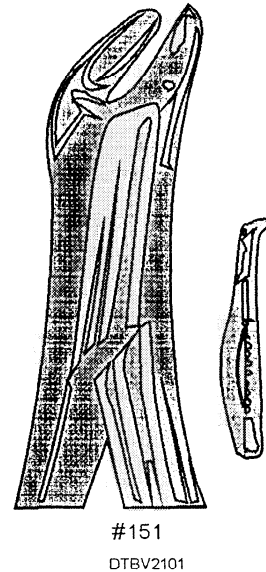


Figure 5-39.—Forceps #151.



Figure 5-40.—Forceps #203.



## Mandibular Molars

There are several popular extraction forceps for the mandibular molars, including the #15, #16, #17, #217, and #222.

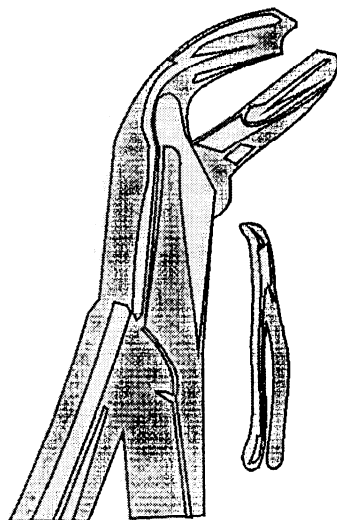
**FORCEPS #15.**—Forceps #15 are used to remove mandibular first and second molars. The beaks have concave inner surfaces with pointed projection on the tips. These forceps work well in grasping the crown with the two projecting tips extending to the bifurcation between the two roots on mandibular third molars. The left handle on the #15 has a finger rest.

**FORCEPS #16.**—Forceps #16 are used to remove mandibular molars. The #16 forceps are nicknamed mandibular *cowhorns* when they are open. The left handle on the #16 has a finger rest.

**FORCEPS #17.**—Forceps #17, like the #15 and #16 forceps, are used on lower first and second molars. The beaks of the #17 forceps are similar to the beaks of the #15 forceps; however, the handle of the #17 is straight.

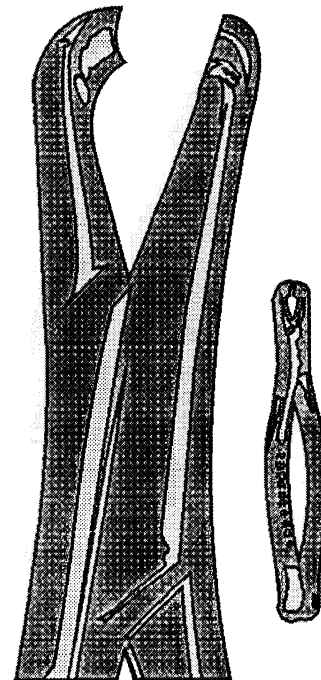
**FORCEPS #217.**—Forceps #217 are used to remove mandibular second and third molars (fig. 5-41). The beaks have inner concave surfaces and pointed projections much like those of the #15 forceps. The handles have a slight curvature and resemble those of the #151 forceps.

**FORCEPS #222.**—Forceps #222 are used on mandibular third molars. The beaks on the #222 forceps are rounded with concave inner surfaces, and angle sharply from the handle (fig. 5-42).



# 217  
DTBV2103

Figure 5-41.—Forceps #217.



# 222  
DTBV2104

Figure 5-42.—Forceps #222.

**HAWKBILL-TYPE FORCEPS.**—There are three hawkbill-type forceps: the Mead #MD3, the #13, and the #22 (fig. 5-43). The Mead #3 forceps are used on mandibular anteriors and bicuspid, the #13 forceps are used on mandibular first, second bicuspid, and the #22 forceps on mandibular first, second, and third molars. The beaks are perpendicular to the working action of the handles. This design gives the dentist a great deal of leverage with minimum effort. The major difference between these forceps is the width of the beaks, because they are used to remove different teeth.

**FORCEPS #101.**—Forceps #101 are used to remove both maxillary and mandibular cuspids, bicuspid, and any remaining roots (fig. 5-44).

**PEDIATRIC FORCEPS #150S AND #151S.**—The pediatric forceps #150S is used to remove maxillary deciduous teeth and is a scaled down version of the #150. The #151S, a smaller version of the 151, is used to remove mandibular deciduous teeth. Both forceps are shown in figure 5-45.

## PASSING AND RECEIVING OF SURGICAL INSTRUMENTS

Instrument exchange between the dentist and assistant takes place in the transfer zone near the

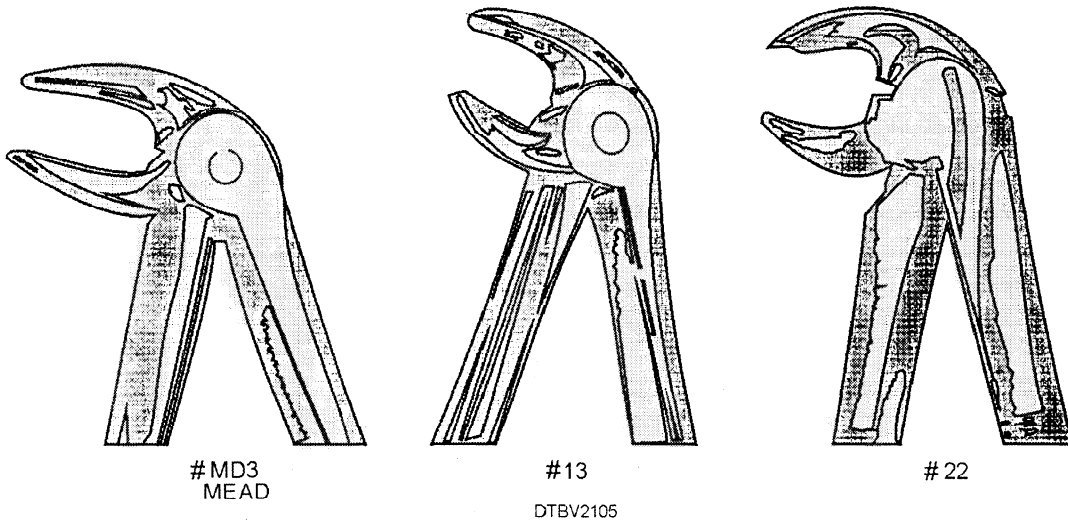


Figure 5-43.—Hawkbill-type forceps used on mandibular teeth.

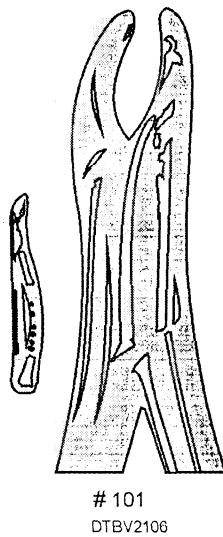


Figure 5-44.—Forceps #101.

patient's chin. As an assistant, you must anticipate the dentist's needs and be ready when signaled by the dentist to pass the next instrument and receive the used one in a smooth motion.

Double-handed instruments, such as scissors, hemostats, and forceps, along with single-ended instruments with bulb-type handles, such as elevators, are transferred somewhat differently as discussed in previous chapters. As figures 5-46 and 5-47 illustrate, when passing these types of instruments, grasp the working end and place the handle into the palm of the dentist's hand. The working end of the passed instrument should be pointed toward the correct arch. When the dentist finishes with the instrument, you will receive the instrument by grasping the working end.

### SURGICAL AIR DRILL

Many different makes and models of surgical air drills are used in oral surgery. A common surgical air drill used in the Navy is shown in figure 5-48. It is a high-speed hand piece used in oral surgery procedures to remove bone and section teeth. The drill enables the dentist to accomplish these procedures quickly and reduces the trauma to oral tissues. It operates by a hand control lever while other makes and models operate by a foot pedal.

Bur guards (fig. 5-49) are used with the air drill. Surgical burs are then inserted into the drill after the bur guard is in place. Bur guards are available in three lengths: medium, long, and extra long. They are designed to protect the dentist and the patient from the long shaft of the burs. Selection of a bur guard is directly dependent on the length of the bur to be used.

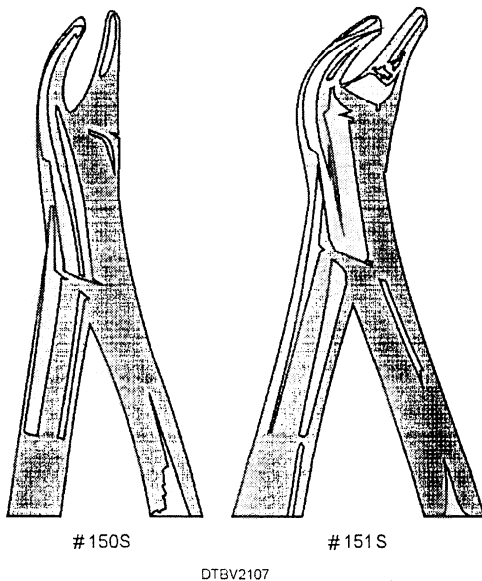
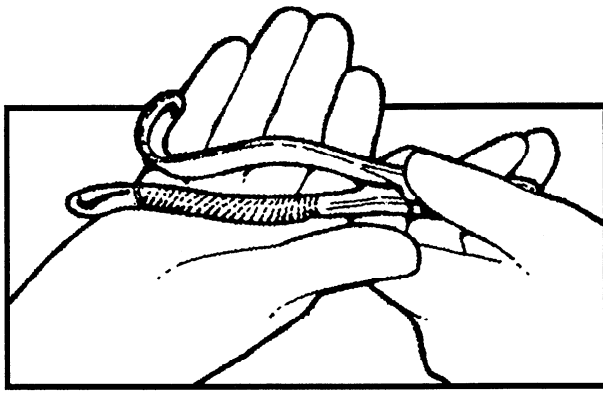
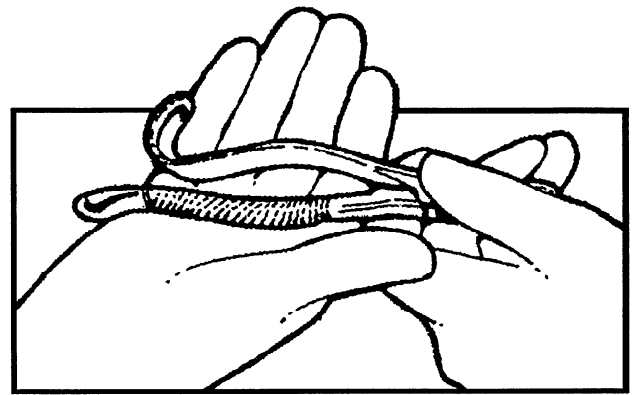


Figure 5-45.—Pediatric Forceps #150S and 151S.



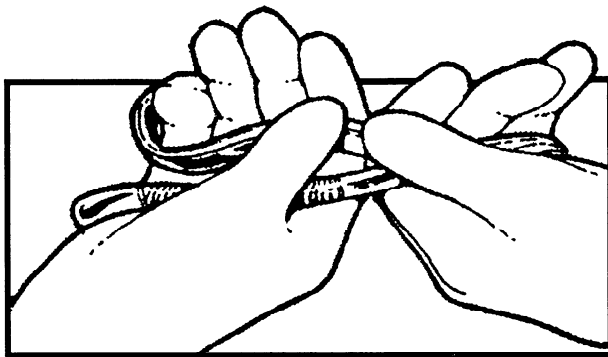
A

GRASP THE FORCEPS NEAR THE WORKING END AND PLACE IT FIRMLY IN THE DENTIST'S HAND WITH THE WORKING END POINTED TOWARD THE CORRECT ARCH.



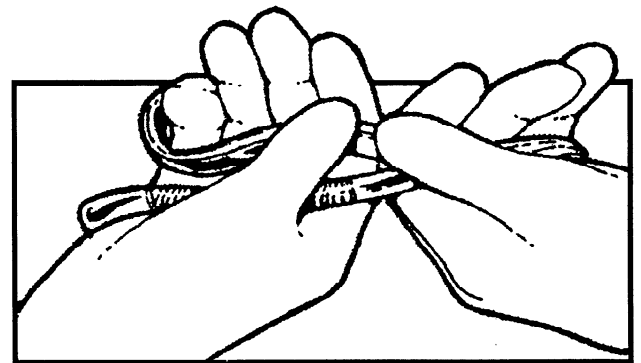
A

GRASP THE ELEVATOR BY THE WORKING END WITH THE PALM THUMB GRASP.



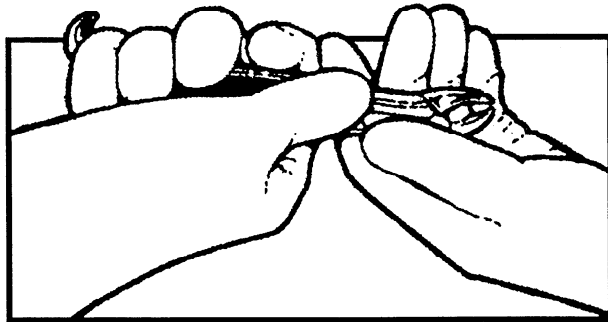
B

PLACE THE HOOK ON THE HANDLE AROUND THE DENTIST'S LITTLE FINGER TO PROVIDE ADDED LEVERAGE.



B

PLACE THE ELEVATOR IN THE PALM OF THE DENTIST'S HAND.

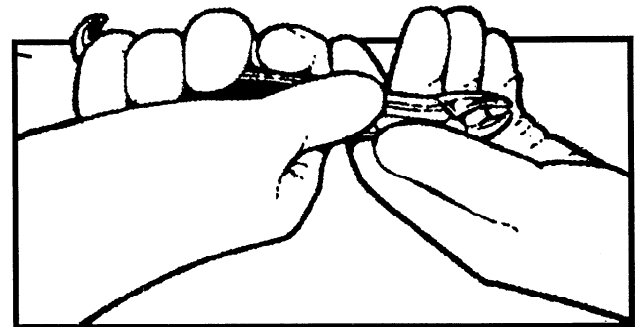


C

RELEASE THE FORCEPS AS THE DENTIST GRASPS IT SECURELY.

DTBV2108

Figure 5-46.—Transfer of surgical forceps.



C

RELEASE THE INSTRUMENT AS THE DENTIST GRASPS IT SECURELY.

DTBV20109

Figure 5-47.—Transfer of a surgical elevator.

Surgical burs (fig. 5-50) are designed specifically for surgical procedures with extra-long shanks. They are made to fit both straight and contra-angle handpieces.

The attachments required to assemble and operate the surgical air drill consist of a power source (compressed dry nitrogen tank), a pressure regulator, and a pressure/exhaust hose. Consult the

manufacturer's operating instructions for use and maintenance of the surgical air drill.

### ASSISTING IN DENTAL SURGERY

Before the surgery, you should discuss the essentials for each dental surgery procedure with the dentist. Advance preparation is essential to establish and maintain asepsis during the surgical procedure. With such preparation, you can be sure to have the necessary instruments, equipment, and materials ready for each patient.

The types of assistants that are commonly used during most outpatient dental surgery in clinics and aboard ships are the circulating and the scrub assistant.

### CIRCULATING ASSISTANT

The circulating assistant plays an important role during the dental surgery procedures and is responsible for many tasks which include, but are not limited to:

- Maintaining the chain of asepsis.
- Preparing the surgical room.
- Receiving and seating the patient.
- Taking pulse and blood pressure.
- Positioning the dental chair.

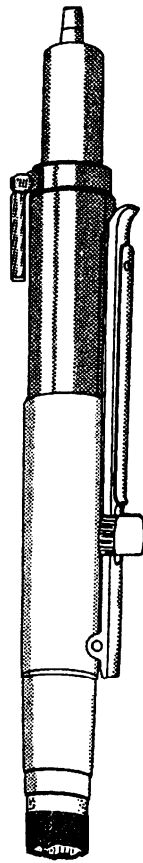
When the dentist is ready to begin surgery, the circulating assistant will bring the surgery tray and place it on the Mayo stand (adjustable tray stand). To avoid contaminating the contents of the pack, touch only the outside edges of the wrappers.

After the extraction tray is opened, the circulating assistant will stand by to assist the dentist and the scrub assistant. When the procedure has been completed and the patient has been dismissed, disinfect and clean the room for the next patient.

### SCRUB ASSISTANT

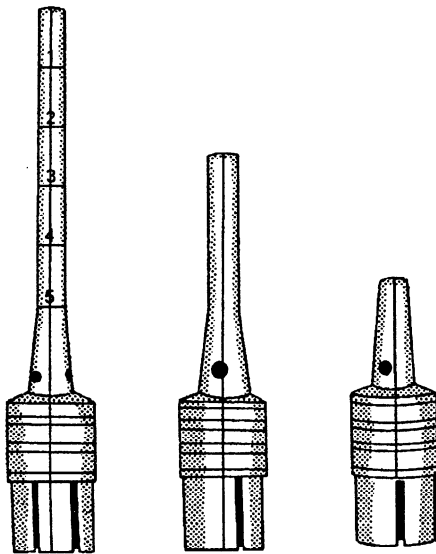
The scrub assistant will assist the dentist during the surgery procedure. Transferring of instruments, and keeping the surgical site clean and clear of debris and blood for the dentist to operate efficiently are the major duties of the scrub assistant.

Once the surgical procedure is completed, the dentist may use sutures to close the surgical wound. If the sutures have been placed, the dentist may want a pressure pack (dressing) over the extraction site to stop the flow of bleeding. Proper post-surgical instructions will also be given to the patient before dismissing.



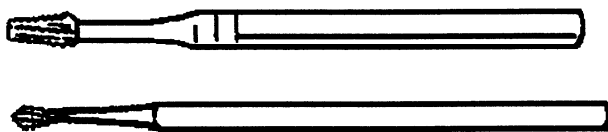
DTBV2110

Figure 5-48.—Surgical air drill.



DTBV2111

Figure 5-49.—Bur guards used with the surgical air drill.



DTBV2112

Figure 5-50.—Surgical burs.

## PRESURGICAL PROCEDURES

During the presurgical procedures, you will receive the patient, and prepare the surgical room. To maintain asepsis in the surgical room, you may need to take a number of special measures. The members of the surgical team may wear sterile, disposable gowns over their regular working uniforms, surgical caps, masks, and hoods (if bearded). Scrub the patient's face and drape the patient with sterile drapes. The dentist and the scrub assistant (or other team member) must perform a surgical scrub and put on sterile surgical gloves and gowns before any oral surgery procedures begin.

### RECEIVING THE PATIENT

As the circulating assistant, you will receive the patient once the surgical suite is prepared. Surgery patients may be nervous or fearful; take special care when receiving them.

Seat the patient and make them as comfortable as possible. Direct the patient to loosen any tight clothing, remove eyeglasses and any removable dentures. If the patient has dentures, place them in a container of water and put their eyeglasses in a safe place.

Before starting any surgical procedure, the circulating assistant will take the patient's pulse and blood pressure. The patient's vital signs will be recorded on the EZ603.

The dentist will usually stand when performing oral surgery. Position the dental chair so that the patient's head is at the level of the dentist's elbow. If the surgery is to be performed on the maxillary arch, position the chair so that the patient's alaragus line is at a 35° angle to the floor. For surgery on the mandibular arch, position the chair so that the patient's alaragus line is parallel with the floor.

### PREPARING THE SURGICAL ROOM

After the patient has been seated, the circulating assistant prepares the surgical room for the surgical procedure. Arrange the instrument stand (Mayo stand) with the following instruments and materials:

- Patient scrub setup.
- Surgical drape pack.
- Two packs of disposable, sterile gloves.

- A simple or complex surgical extraction pack, plus any additional instruments or materials requested by the dentist. Place the pack(s) on the Mayo stand. Position the stand to the rear of the dental chair so that the instruments are within easy reach of the dentist and the scrub assistant.
- Anesthesia pack (if one is not included in the extraction pack).

**NOTE:** Do not open any of the packs at this time.

Once the instruments and materials have been set out, the circulating assistant gets ready to perform the patient scrubbing procedures.

### PATIENT SCRUBBING PROCEDURES

The circulating assistant scrubs the patient's face. During the scrub procedure, take special care to see that patients with facial hair, makeup, sores, or skin infections are thoroughly cleansed. The scrubbing procedures are as follows:

**NOTE:** The circulating assistant must wear gloves when performing the following steps.

- Place a hand towel on the patient's chest to keep the patient's clothes from being stained. Tuck the top of the towel inside the patient's collar. (Use another hand towel if you need more coverage.)
- Saturate two 4 x 4 sterile gauze sponges with the surgical soap solution.
- Use both sponges to scrub the patient's cheeks, nose, and chin. Work up a good foaming lather and be sure to scrub the area beneath the chin. After 1 minute, discard the two sponges, then with two new sponges, continue the scrub. The entire process should take approximately 2 minutes.
- After the scrubbing procedure is completed, blot the excess lather with a sterile towel.

### SURGICAL TEAM SCRUBBING, GLOVING, AND DRAPING

While the circulating assistant finishes preparing the patient, the dentist and scrub assistant will prepare for surgery. The circulating assistant will help the other team members during the following procedures.

#### Scrubbing

The dentist and the scrub assistant will perform the same procedures, which requires an antimicrobial

surgical product, a nail cleaner, and a sterile hand brush or sponge. These materials are available in the scrub area. Before scrubbing, remove all rings, watches, or other jewelry from your hands and arms. Ensure that your fingernails are short, smooth, free from polish, and the cuticles are trimmed. Then, complete the following procedures:

1. Wet your hands and arms with water. Put a small amount of antimicrobial surgical product in the palm of your hand and spread the solution over your hands and arms. Work the solution into a good lather.
2. Clean your nails and cuticles with a nail cleaner under running water. When you are through, discard the nail cleaner.
3. Rinse your hands and arms under running water.
4. Wet the brush or sponge and place a small amount of the antimicrobial solution on the bristles. Scrub each hand and arm in the following manner:
  - Place your fingers together and scrub across the tips for 30 strokes.
  - Starting with your thumb, scrub each finger on all surfaces. Use 20 strokes for each finger, and make sure that the webbed areas between the fingers are scrubbed.
  - After you have scrubbed each finger, scrub your palm. Use a circular motion and scrub for 20 strokes.
  - Scrub from your wrist to 2 inches above your elbow. Brush in one direction only (away from the wrist) and scrub for 20 strokes.
  - **WITHOUT RINSING**, wash your other hand and arm in the same manner. Then discard the hand brush or sponge.
5. Rinse both hands and arms. Hold your hands higher than your elbows and allow the water to flow from your fingertips to your elbows. **NEVER** move your hands back and forth through the water. Allow the water to drip from your elbows for a few seconds before leaving the scrub area. When leaving the scrub area, hold your hands close together and away from your body. **DO NOT** touch anything.
6. While the scrub assistant and the dentist scrub, the circulating assistant will open the surgical drape pack, being careful to touch only the

outside edges of the pack. When the scrub assistant enters the operating room, use a sterile towel from the pack to dry the hands and arms, being careful not to drip on the sterile field.

7. On one half of the towel, use a blotting action to dry one hand and arm, from the fingers to above the elbow. Dry your other hand and arm in the same manner with the other half of the towel. **NOTE:** When drying, bend at the wrist and hold your hands and arms away from your body. This will keep the sterile towel from coming in contact with your unsterile scrub suit.
8. When this procedure is complete, pass the towel to the circulating assistant.

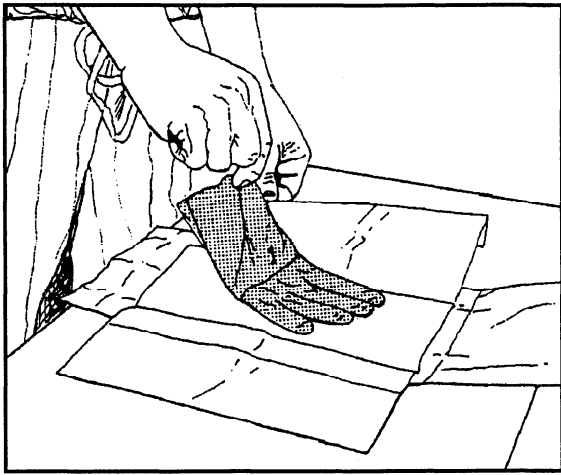
**NOTE:** The above scrubbing routine is normally performed for the first case in the morning and again after lunch. Otherwise, an abbreviated scrub procedure, consisting of a 2-minute washing procedure of your hands and arms with antimicrobial surgical product should be performed.

### Gloving

After the scrubbing procedure is completed, the surgical team will don sterile surgical gloves. Gloving procedures are the same for the dentist and the scrub assistant.

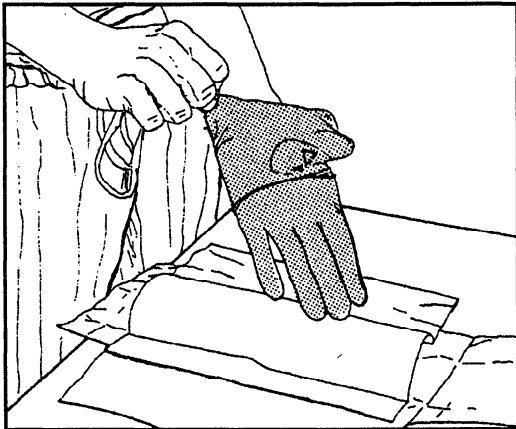
The circulating assistant will open the packages of disposable sterile gloves, touching only the outside edges of the packages. The procedures for putting on the gloves are as follows:

1. Without touching the gloves, fold back the tissue paper covering. The cuff of each glove is folded so that the inside of the cuff is partially exposed. **NOTE:** Touch only the inside portion of the glove with your bare hand.
2. Grasp the first glove at the cuff fold (fig. 5-51). Gently pull the glove onto your free hand and anchor the cuff over your thumb (fig. 5-52).
3. Slip the fingers of your gloved hand under the folded cuff of the second glove. Keeping your fingers under the folded cuff, begin to work the second glove onto your bare hand (fig. 5-53). Do this gently so that the cuff remains folded. Work the glove up, and over your hand and wrist, and onto your arm (fig. 5-54). As you do this, gradually unfold the cuff so that its inner side is now against your skin. Remember that you cannot touch this exposed inner side with your gloved hand. Finally, grasp the outside of the




DTBV2113

Figure 5-51.—Grasping the first glove at the cuff fold.



DTBV2114

Figure 5-52.—Anchoring the cuff over the thumb.

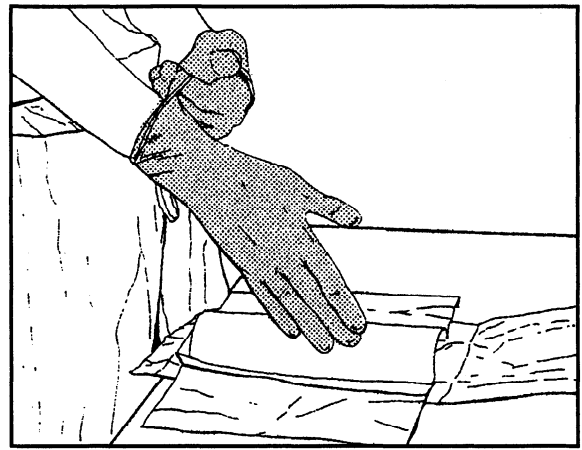


DTBV2115

Figure 5-53.—Working the second glove onto your bare hand.

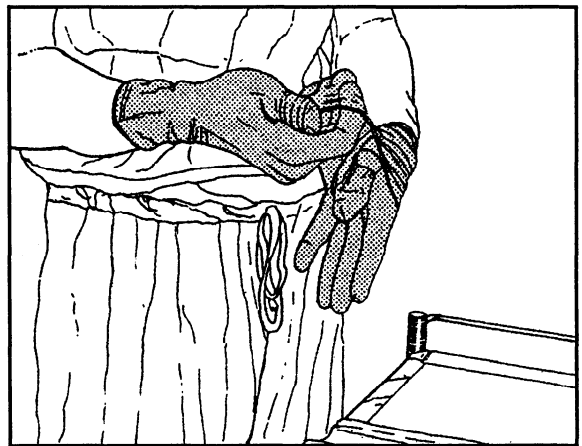
glove and pull it completely on. One hand is now fully gloved.

4. Slip the fingers of your gloved hand under the folded cuff of the first glove (fig. 5-55). Work the cuff over your wrist and onto your arm. Gradually unfold the cuff so that its inner side is



DTBV2116

Figure 5-54.—Working the glove up over the hand and wrist and onto the arm.



DTBV2117

Figure 5-55.—Slipping gloved fingers under the cuff of the first glove.

now against your skin. Then grasp the outside of the glove and pull it completely on.

## Draping

Both the dentist and the scrub assistant will drape in the following manner:

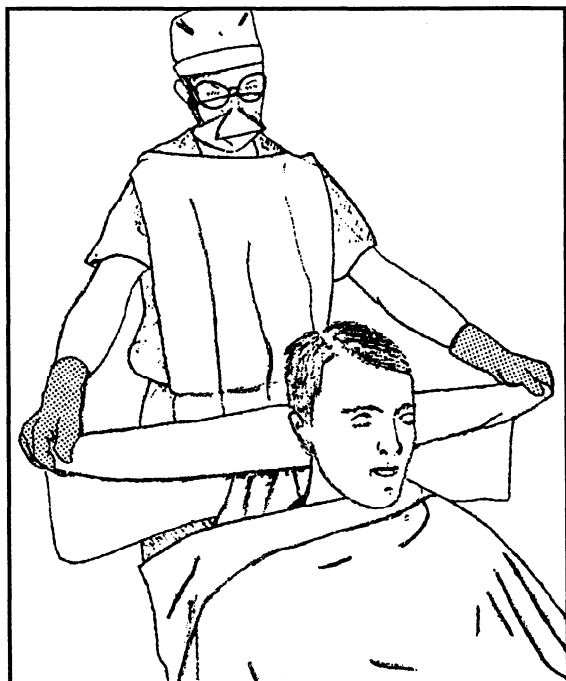
1. Remove a sterile hand towel from the drape pack. Hold it away from your body and allow it to unfold. Make sure that the towel does not come into contact with your scrub suit or any unsterile item.
2. Raise the towel to shoulder height, holding it so that a small cuff is formed at the top of the towel.
3. The circulating assistant will grasp one of the top edges at the cuff and fasten it to the shoulder of the scrub suit with a towel clip. Then the circulating assistant will fasten the other top

edge in the same manner. After the dentist and scrub assistant are draped, the circulating assistant will drape the patient.

## Draping The Patient

The drapes remaining in the drape pack are for the patient. The drape pack consists of a body drape, head drape, and four sterile towel clamps. Additional drapes may be used, depending on the preference of the dentist. The scrub assistant will drape the patient in the following manner:

1. Grasp the corners of the body drape. Lift it up and away from the pack, allowing it to unfold. Hold the drape so that a small cuff is formed across the top. Be sure that the drape does not come into contact with unsterile items. Do not shake the drape.
2. Carry the drape to the patient and place the top edge directly under the patient's chin and over the shoulders. The remainder of the drape should cover the patient's chest and upper thighs.
3. Grasp the corners of the head drape and remove from the pack in the same manner as the body drape. The cuffed portion of the inner drape should be up and folded away from you.
4. Place the top of the drape over the headrest of the dental chair (fig. 5-56).



DTBV2118

Figure 5-56.—Top of the head drape placed over the headrest.

5. Grasp the inner drape by the corners and draw the left side of the drape over the patient's left eye and the bridge of the nose. Then draw the right side of the drape over the patient's right eye and the bridge of the nose. Using a sterile towel clamp, fasten the two sides of the head drape together.
6. Using a sterile towel clamp, fasten the left side of the head drape to the left side of the body drape; then do the same thing on the right side. The patient is now completely draped and ready for the surgical procedure.

## SURGICAL PROCEDURES

Surgical procedures cover the duties of the circulating assistant and the scrub assistant during the procedure. Because of the importance of maintaining asepsis in the operating room, this section will begin with a discussion of certain rules of the aseptic technique.

### RULES OF THE ASEPTIC TECHNIQUE

These rules are designed to help you avoid contaminating instruments and materials during oral surgery. By following them closely, you will greatly reduce the possibility of introducing cross-contamination into the oral cavity during the surgical procedure.

1. An article is either sterile or unsterile. If there is any doubt, consider the article unsterile and discard it immediately.
2. Do not open a sterile pack or container until the article(s) is/are required.
3. If you are the circulating assistant, touch only the outside edges of the wrapper when opening a sterile pack. Take care when unfolding the wrapper so that the inside does not brush against your clothing. If you are the scrub assistant, never touch the outside of a pack.
4. Wear sterile gloves and change gloves if they become punched or torn. Make sure you discard the contaminated gloves.
5. Remove sterile articles from a pack or a container by lifting them straight up and out. Never drag an article over the edge of a pack or a container.
6. Once an article is removed from a sterile pack or a container, do not place it back in the pack.



7. Place sterile articles on a dry, sterile surface. Moisture will contaminate the articles.
8. Only the top portion of a draped instrument stand should be considered sterile. Sterile gloves must be used in this area. Any portion of the wrap hanging over the edge of the stand is considered unsterile.
9. If an instrument becomes contaminated, discard it immediately.
10. If a delay occurs in the procedure, the scrub assistant should cover all unwrapped packs with sterile drapes.
11. All sterile articles set out for a procedure must be cleaned and sterilized or disposed of after the procedure is completed. This pertains to articles that were not used.
12. Never reach behind another draped member of the surgical team.
13. Always keep your hands above your waist.
14. Always face the draped patient and the other members of the surgical team. If it becomes necessary to pass another draped member of the team, pass back to back.
15. Always pass an unsterile object in the operating room with your back toward the object. Unsterile objects include chairs, desks, cabinets, and similar items.

## **INSTRUMENT SETUP AND MATERIALS**

It is critical that you establish and maintain a sterile field when preparing for a surgical procedure. A scrub assistant must have on sterile gloves when a sterile surgical tray is opened for a surgical procedure. The corners of the wraps are carefully unfolded and allowed to drape over the surface where the tray is positioned to provide a sterile field. The instruments and materials should be arranged in the sequence in which they are most commonly used during the procedure. This expedites the exchange of instruments between the scrub assistant and the dentist, and avoids searching the tray for an out-of-place instrument. Once instruments are used, they should be returned to their proper location whenever possible. Both the scrub and circulating assistants should know all the surgery instruments to be used by name, number, purpose, and sequence of use.

As part of the preparation, the scrub assistant must assemble several items on the tray setup, such as

anesthetic syringes, scalpel and blade, irrigation syringe and tip (or bulb syringe if used), surgical suction tip, and handle with tubing. First, the circulating assistant fills the metal cup with sterile saline. After that the scrub assistant fills the irrigation syringe from the cup.

Figure 5-57 illustrates a tray setup for a complex or impacted surgical extraction. Please note that all the instruments shown in figure 5-57 may not be in the same setup that you may use at your command. The surgical tray setup should be kept covered with a sterile towel until the procedure begins.

## **POST-OPERATIVE PROCEDURES**

Some of the more common post-operative procedures that the dentist may direct you to perform include control of bleeding, post-surgical instructions, and suture removal.

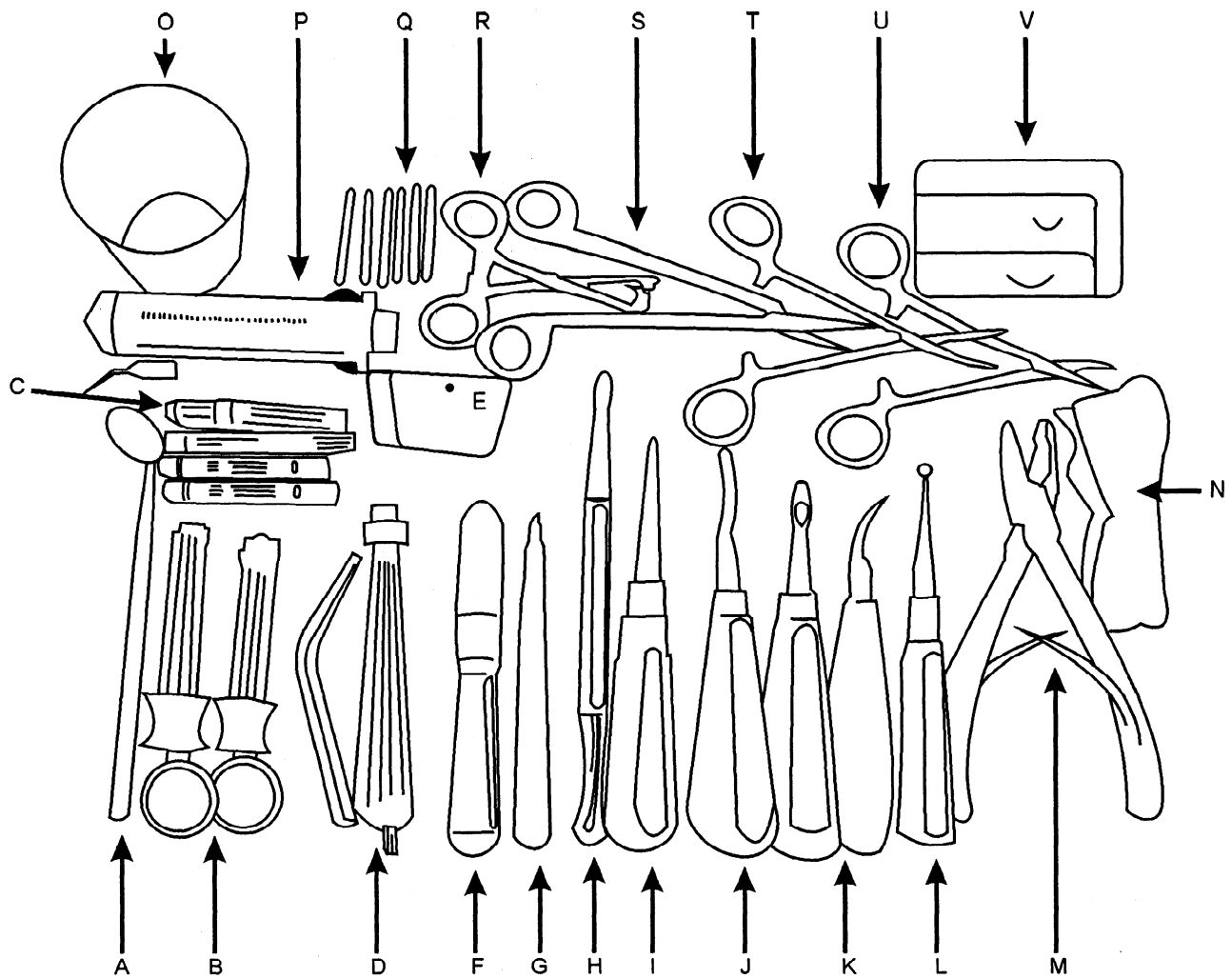
### **CONTROL OF BLEEDING**

After an extraction, place a moistened pressure pack made of folded, sterile gauze squares over the socket (fig. 5-58). It is important that this pack stays in place to control bleeding and encourage blood clot formation. Instruct the patient to keep the pack in place for at least 30 minutes to an hour. Warn the patient that removing the compress too soon will disturb blood clot formation, and may increase the tendency of hemorrhage and delay healing. Give the patient extra gauze to place an additional pressure pack if hemorrhage has not stopped after the original pack is removed. Advise the patient to limit activity and avoid strenuous work or exercise for a few days after surgery to avoid hemorrhage at the surgical site.

### **POST-SURGICAL INSTRUCTIONS**

Post-surgical instructions to patients are important guidelines that they should follow to prevent complications and unnecessary discomfort. In many instances, the dental assistant may be responsible for giving the post-surgical instructions to the patient. It is advisable to discuss these instructions with the patient after the surgery to prevent confusion. If a patient is sedated, verbal instructions must be given to the patient before the sedation and to the patient's escort.

In either case, the patient should be given a printed copy of the instructions to review after leaving the dental clinic. Patients tend to forget verbal instructions, especially when they are given right after



A. MOUTH MIRROR  
 B. ANESTHETIC SYRINGES  
 C. ANESTHETIC NEEDLES & CARPULES  
 D. SURGICAL SUCTION TIP & HANDLES  
 E. MOUTH PROP  
 F. MINNESOTA RETRACTOR  
 G. SCALPEL WITH #15 BLADE  
 H. PERIOSTEAL ELEVATOR

I. TOOTH ELEVATOR, #301  
 J. TOOTH ELEVATOR, #92  
 K. COGSWELL A & B  
 L. MOLT BONE CURETTE  
 M. RONGUER FORCEPS  
 N. ROLLED 4X4 GAUZE  
 O. METAL CUP

P. IRRIGATION SYRINGE & TIP  
 Q. SURGICAL BURS  
 R. TOWEL CLAMPS  
 S. SURGICAL SCISSORS  
 T. CURVED HEMOSTAT  
 U. NEEDLE HOLDER  
 V. SUTURE MATERIAL

DTBV2119

Figure 5-57.—Tray setup for a complex or impacted surgical extraction.

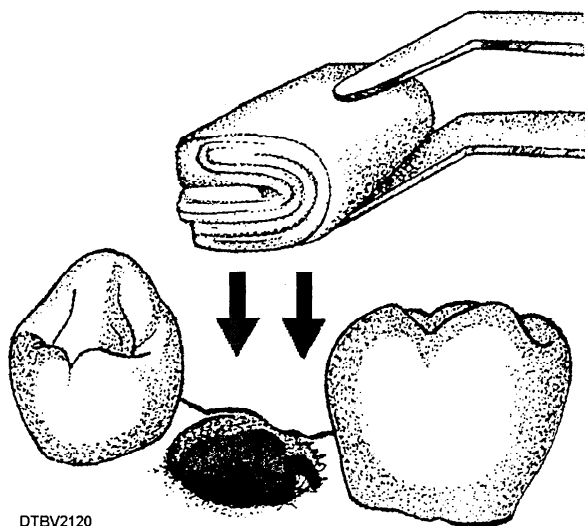
surgery. Verbal instructions are given only to emphasize the important written guidelines.

Stress to the patient that home care following dental surgery is important and recovery could be delayed if this is neglected. Inform the patient that some swelling, stiffness, and discomfort are to be expected. If these reactions are greater than expected, inform the patient to call or return to the dental clinic for care.

The expected effect of anesthesia, both local and conscious sedation agents, if applicable, should be explained to the patient and escort. Inform the patient

to keep the gauze pack in place over the surgical site with **light** pressure until the hemorrhage stops or the gauze becomes saturated. Following surgery, many patients are so relieved the surgery is completed that they will try to talk and ask numerous questions. This should be firmly discouraged by explaining to the patient that healing depends on establishing good clots and steady light pressure. The gauze pack need not be replaced if bleeding has ceased. A slight ooze can be expected at times and could continue for a few hours.

Advise patient to limit activities and avoid strenuous work or exercise for a few days after surgery. Caution the patient to keep the head elevated with



DTBV2120

Figure 5-58.—Placing a pressure pack.

pillows when resting or sleeping during the first 24 hours since lowering the head increases blood pressure and can promote continued bleeding.

Instruct the patient not to smoke or use a straw for at least 24 hours. Frequent spitting, sucking on the wound, and using mouthwashes should be avoided during this time to secure an adequate blood clot.

Inform the patient to take the prescribed medications for pain, and the antibiotics to prevent infection (if prescribed). It is best if the patient takes the first dose of pain medication after the removal of the initial gauze pack. This allows the pain medication to enter the blood stream before the effects of the local anesthesia wears off.

Instruct oral surgery patients to place an ice bag or chemical cold pack- on the external area of the treatment site for the first 24 hours only, to minimize swelling. Apply the ice for at least 30 minutes on and then 30 minutes off after the surgery. Any amount of time less than this will not permit the cold to penetrate the tissues adequately. Cold is effective in decreasing edema by constricting the blood vessels. Heat may be placed on the jaw after the first 24 hours to minimize swelling.

You should recommend a soft diet and sipping of water and fruit juices for a few days following dental surgery. Make sure the patient has an appointment to return for a post-surgical check in 3 to 5 days.

You should always remain with your surgical patients until they recover enough to be dismissed. Dismiss your patients as cordially as you received them. Closely observe the patients as they leave to make sure that they are steady and show no signs of distress. If patients exhibit any signs of dizziness, detain them until the dentist can evaluate their condition.

## SUTURE REMOVAL

Sutures can be removed 3 to 7 days following surgery, depending on the material and procedure. For example, nylon or silk sutures are removed from 3 to 5 days after surgery if adequate healing has taken place. After the extraction site is examined by the dentist, suture removal can be delegated to the assistant.

Irrigate or swab the suture site with an antiseptic solution to remove any debris. Locate and account for all the sutures placed during the surgical treatment. Use a hemostat or cotton forceps to gently lift the suture away from the tissue to expose the attachment of the knot. With the scissors in the other hand, slip one blade of the scissors under the suture and one blade over the suture. Cut the suture material as close to the tissue as possible so that a minimum of material is pulled through the tissue. Grasp the knot and gently slide the suture out of the tissue. Take care not to pull the knot through the tissue, since this causes unnecessary discomfort to the patient. Continue lifting and snipping the suture material until all sutures are removed. Count and compare the number of sutures removed with the number placed as indicated in the patient's record. Irrigate the surgical area with antiseptic solution if there is any bleeding.

## COMMON POST-SURGICAL COMPLICATIONS

Just as with any surgical procedure, there can be complications. In oral surgery, the common post-surgical complications are alveolar osteitis, swelling, and bleeding. These complications have been discussed in *Dental Technician*, Volume 1, chapter 6, "Emergency Treatment of Oral Diseases and Injuries," and under the Post-Surgical Instructions section in this chapter.



## CHAPTER 6

# PERIODONTIC ASSISTANCE

### PERIODONTICS

Periodontics is that branch of dentistry pertaining to the diagnosis and treatment of the supporting and surrounding tissues of the teeth and their substitutes. It also includes the implantation or transplantation of teeth and their substitutes. The goal of modern periodontal therapy is to preserve and maintain periodontal health, aesthetics, and function of natural dentition and implanted tooth replacements.

The supportive structures, collectively termed the *periodontium*, consist of the gingiva, periodontal ligaments, and alveolar bone. Diseases that damage the periodontium are called periodontal diseases.

To prepare for this chapter, review chapters 5, 6, and 8 of *Dental Technician*, Volume 1, NAVEDTRA 12572, and chapter 3 of this manual. In chapter 5, "Oral Pathology," we discuss pathology of the periodontium. In chapter 6, "Emergency Treatment of Oral Diseases and Injuries," we discuss diseases of the periodontal tissues. In chapter 8, "Nutrition and Diet," we discuss preventive dentistry and nutrition. In chapter 3, "Preventive Dentistry," we discuss oral hygiene and supragingival scaling. In this chapter, we will cover the functions and indications of periodontics.

### FUNCTIONS

The treatment of periodontal diseases may encompass both the dental and medical professions. When the cause of a patient's periodontal disturbance is diagnosed as systemic (affecting the body as a whole), the patient should be referred to the medical facility for diagnosis and treatment of the medical condition.

The dental treatment of a periodontal patient may require coordinated treatment from other specialty areas. Often, patients needing periodontal treatment are referred from specialty areas where they were seeking treatment for other related dental problems. For example, the patient may need a prosthetic appliance to replace some missing teeth. However, the patient's periodontal condition may require periodontal treatment before the appliance can be

made. In evaluating and treating the patient's periodontal disease, the periodontist may decide to eliminate periodontal pockets surrounding some teeth and determine other teeth are nonrestorable. The patient is referred to the oral surgeon for removal of these nonrestorable teeth. The periodontist may determine that other periodontal problems can be alleviated by having a general dentist remove and replace faulty restorations. In some situations, the services of the orthodontist may be required to reposition malposed teeth.

Since periodontal disease affects the supportive structures of the teeth, the primary function of periodontal treatment is (a) to eliminate the inflammation and arrest the progress of the disease and (b) perform periodontal treatment. Several reasons to eliminate pockets are as follows:

- Food, bacterial accumulation, and infection can exist in pockets that form around the teeth.
- Conditions, such as loss of gingival covering, can lead to exposure of the root and caries can occur.
- Inflammatory changes in the gingiva may increase the susceptibility to necrotizing ulcerative gingivitis (NUG). **Note:** NUG is caused by bacteria usually in the presence of secondary factors such as stress, smoking, and or lack of rest.
- Inflammation from the pocket walls can cause bone loss.
- Discomfort can occur during mastication.

### INDICATIONS AND CONTRAINDICATIONS

Most periodontal diseases are characterized by inflammation that initially affects the gingiva. Advancement of the inflammatory process, if not stopped, may proceed to cause damage to periodontal ligament tissue and alveolar bone. Inflammatory diseases confined to the gingiva are termed *gingivitis*, whereas those that cause damage in the deeper supporting structures are classified as *periodontitis*.

Early signs and symptoms of periodontal disease found in the interdental papilla and marginal gingiva include the following:

- Redness
- Tendency to bleed easily
- Evidence of exudate
- Sponginess
- Tenderness
- Slight swelling
- Probing depth of pockets

Periodontal treatment is indicated when a periodontal condition cannot be eliminated through preventive care, including prophylaxis, and improved oral hygiene and diet. Resorption of the alveolar bone and the periodontal tissues are also indications for treatment. If the progress of the disease is stopped, the teeth may have adequate support for retention. For successful periodontal treatment, a patient must be willing to accept treatment and follow the requirements necessary to maintain good oral hygiene.

Several situations contraindicate periodontal treatment. A patient in poor general health with a poor prognosis for successful treatment and healing is one example. Another would be a patient with an extensive infection within the periodontium and/or bone loss too extensive to provide support for the tooth following periodontal surgery. Periodontal treatment is definitely contraindicated if the patient has a negative attitude and unwillingness to cooperate in establishing and maintaining good oral hygiene and nutrition.

### **EXAMINATION, CHARTING, AND TREATMENT PLAN**

The initial examination of the periodontal patient includes thoroughly reviewing the patient's medical/dental health history, dental treatment history, and radiographs; charting of periodontal probing depths, occlusion, and tooth mobility; and determining a treatment plan.

The review of the patient's medical-dental health history provides valuable information regarding the dental status of the patient, such as past dental treatment, the patient's oral hygiene habits, and attitude toward dental health. A current full series of periapical radiographs and vertical bite-wings are necessary for a thorough periodontal examination. Radiographs are extremely useful in the diagnosis and treatment of periodontal disease because of conditions

such as bone loss around the teeth, calculus, poor margins and overhangs on restorations, and open tooth contacts that are visible. In addition to radiographs, some dentists may take clinical photographs of their patient's mouth and in some cases, diagnostic study casts are made.

### **CHARTING**

Your primary responsibility during the examination is to record the findings as the dentist dictates them. The results of the examination are recorded on a NAVMED 6600/2, Periodontal Chart. This two-sided form (figs. 6-1 and 6-2) provides a permanent record of the examination, diagnosis, and treatment plan for initiation of each new course of therapy for the treatment of periodontal disease.

The form is an anatomical chart that contains diagrams of the teeth with spaces for comments. It permits documentation of changes in the teeth, occlusal relations, soft tissue alterations, and information gained from radiographs. The findings related to the teeth that are charted include missing, unerupted, malpositioned, or replaced teeth, dental caries, open or poor contacts, defective or poor restorations, food impaction, pain on percussion, and plunger cusps. Findings of the periodontium include the gingival level on the tooth, areas of recession or clefts, gingival enlargement or craters, probing depths, frenum attachments, furcation invasion (disease extension between the roots of multirrooted teeth), bleeding and purulence points, tooth resection, and tooth mobility.

Instructions and symbols for charting are located in the left column on the front page. Charting notations for the front section are made in blue pencil, red pencil, and regular black pencil.

Use black ink on the following front sections: Place of examination, examiner, date, and patient identification section. Also record the reverse side information in black ink.

### **Pocket Depth**

One of the most important findings in the periodontal examination are the probing depths of the gingival sulcus or periodontal pockets. The dentist determines these measurements using a periodontal probe calibrated in millimeters. The dentist inserts the periodontal probe into the gingival sulcus to the depth of the epithelial attachment. The distance between the attachment and the gingival margin is measured and

**PERIODONTAL CHART**

Personal data - Privacy Act of 1974

<b>Bleeding/purulence (+)</b>			
<b>Attachment level CEJ to BP</b>			
<b>Pocket depths FM to BP</b>			
<div style="border: 1px solid black; padding: 5px; font-size: small;">                 Mark full <math>\frac{1}{2}</math> crowns and pontics in blue                  Furcation Involvement                  Grade 1 <math>\nabla</math>                  Grade 2 <math>\triangle</math>                  Grade 3 <math>\blacktriangle</math>                  Recort an Occlusal Outlines                  Mobility (1,2,3)                  Poor contact <math>\downarrow</math>                  Open contact <math>\parallel</math>                  Food impaction <math>\downarrow</math>                  Caries and faulty restorations outlined in red             </div>			
<b>Pocket depths FGM to BP</b>			
<b>Attachment level CEJ to BP</b>			
<b>Bleeding/purulence (+)</b>			
<b>Bleeding/purulence (+)</b>			
<b>Attachment level CEJ to BP</b>			
<b>Pocket depths FGM to BP</b>			
<div style="border: 1px solid black; padding: 5px; font-size: small;">                 KEY                  Horiz. lines = 1mm                  FGM = free gingival margin                  BP = base of pocket                  Draw FGM with continuous blue line relative to CEJ                  Mark pocket area in red on root surface                  Draw intergingival junction as black continuous line                  Block out missing teeth and/or roots             </div>			
<b>Pocket depths FGM to BP</b>			
<b>Attachment level CEJ to BP</b>			
<b>Bleeding/purulence (+)</b>			
<b>PLACE OF EXAMINATION</b>	<b>EXAMINER</b>		<b>DATE</b>
<b>PATIENT IDENTIFICATION</b>			
<b>SEX</b>	<b>GRADE, RATE, OR POSITION</b>	<b>ORGANIZATION/UNIT</b>	<b>PHONE (W) (H)</b>
<b>PATIENT'S LAST NAME-FIRST NAME-MIDDLE NAME</b>		<b>DATE OF BIRTH (Day-Month-Year)</b>	<b>SOCIAL SECURITY NUMBER</b>

Figure 6-1.—NAVME 6600/2 (Front page).

recorded. Six measurements are made of the gingival sulcus or pocket depth on each tooth: three on the facial and three on the lingual. The dentist walks the probe around the tooth for the three measurements on the facial surface of each tooth in the arch which include the distofacial, facial, and mesiofacial (fig. 6-3). The dentist repeats the probing procedure for the three measurements on the lingual surfaces of each tooth in

the arch: distolingual, lingual, and mesiolingual. The dentist repeats the probing process for the opposite arch.

**Mobility**

With the progression of periodontal disease, supporting bone structure that anchors the tooth in place may be destroyed. This will make the teeth

# PERIODONTAL CHART

BACK SIDE - USE AS OPTIONAL WORKSHEET

Patient's Name: _____		SSN: _____				
Chief Complaint _____						
Pertinent Med/Dent Hx:	Age	Sex	Race	HT	WT	BP
Extraoral Findings: _____						
Intraoral Findings: _____						
Plaque Control: _____						
Periodontal Findings: _____						
Occlusion: _____						
Radiographic Assesment: _____						
Etiology/Contributing Factors: _____						
Diagnosis: _____						
Prognosis (1-5 years) (Circle one):    Good    Poor    Hopeless						
Overall: _____						
Individual: _____						
Tentative Treatment Plan: _____						
Permanently retain this form in the dental record. Enter all pertinent findings from above, i.e., on the back side, in the "S.O.A.P." entry on the SF 603/603A.						

U.S. GOVERNMENT PRINTING OFFICE: 1993-704-079/60287

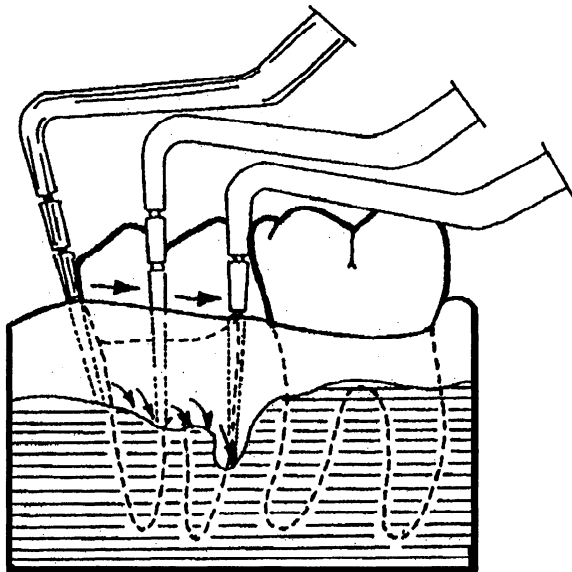
DTV2f602

Figure 6-2.—NAVMED 6600/2 (Back page).

become loose (mobile). The dentist tests each tooth for mobility by using the handles of two mirrors to push it in a facial-lingual direction and pressing on the occlusal or incisal surface. A scale of one to three (I, II, and III) is used to describe and record mobility.

- Class I—Slightly greater than normal
- Class II—Moderate mobility (within 1mm of total movement)
- Class III—Extensive mobility (greater than 1mm in all directions or depressible)





DTV2f603

Figure 6-3.—Walking the periodontal probe around the tooth.

## TREATMENT PLAN

Once the front of the NAVMED 6600/2 is charted, the areas of the back of the form are completed by the dentist. The tentative treatment plan outlines the dentist's recommended treatment for the patient and the sequence in which it is done. The dentist must discuss the diagnosis, prognosis, and tentative treatment plan with the patient. It is up to the patient to accept or decline the recommended treatment. The examining dentist, facility, and dates are on the front page of the NAVMED 6600/2, which becomes a permanent part of the patient's dental record. After the examination is completed, appointments are arranged with the patient for treatment.

## BASIC PERIODONTAL INSTRUMENTS

Several instruments are commonly used in periodontal treatment. Among them are probes, scalars, curettes, hoes, files, chisels, and knives. Although we have discussed some of these instruments in other specialties, the instruments discussed here are designed for periodontal use and are somewhat different. Some of the instruments are used for scaling and root planing, while others are used for periodontal surgery.

## PERIODONTAL PROBES

The periodontal probe is one of the most important instruments used to make a diagnosis and accurately determine the presence, depth, and form of periodontal

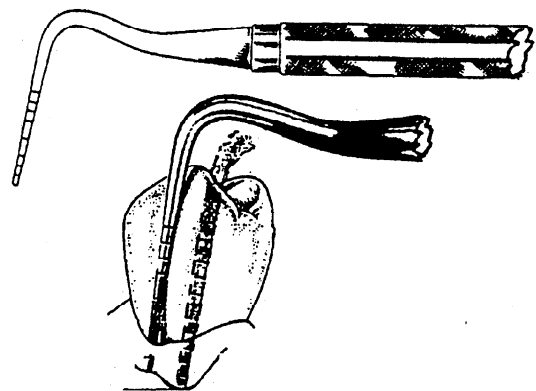
pockets. An angled shank places the working end at about a 45° angle in relation to the handle. The thin narrow working end is inserted gently to the depth of the periodontal pocket. Calculus may interfere with accurate probing. A periodontal probe is an elongated and tapered instrument that is scored at millimeter intervals on the working end. The scored markings make it easy to determine the depth of the pocket. The markings can range in increments from 1 to 10mm, depending on the type of the probe. Many different types of probes are used. Figure 6-4 illustrates a common periodontal probe

## FURCATION PROBES

When periodontal disease causes sufficient loss of attachment around multirooted teeth, the interradicular bone (furcation area) may become involved. The presence of gingiva and neighboring teeth frequently prevent accurate probing of the furcation area with the standard periodontal probe. The furcation probe shown in figure 6-5 is a double-ended instrument designed to help determine the extent of the interradicular bone loss.

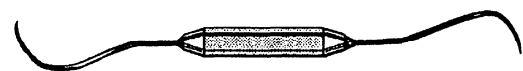## SCALING AND ROOT PLANING INSTRUMENTS

The term *scaling* is used to identify the removal of calculus (mineralized plaque) from the surface of a tooth. Scaling can be supragingival (performed by Dental Technicians) or subgingival (performed by a hygienist or a dentist), depending on the location of the



DTV2f604

Figure 6-4.—Periodontal probe.



DTV2f605

Figure 6-5.—Furcation probe (double-ended).

calculus relative to the gingival margin. The objective of scaling is to remove calculus from the tooth surface. This is easy to accomplish when the calculus is located on the enamel of the tooth. Calculus attached to the root surface, however, is embedded in the surface irregularities and is much more difficult to remove. The dentist or hygienist will smooth out the irregularities and remove the calculus. As this is done, some root structure is removed. This is referred to as root planing. Several instruments have been designed for scaling and root planing. They include sickles, curettes, files, chisels, and hoes (illustrated in figure 6-6). We will discuss dental implant scaling instruments.

### Sickle Scalers

A sickle scaler (fig. 6-7) is primarily designed for removal of supragingival calculus. Sickles with straight shanks are designed to adapt to anterior teeth, and those with contra-angled shanks (called Jacques) adapt to posterior teeth and are illustrated in figure 6-8. The basic characteristics of the sickle scaler are they are triangular in shape, have two cutting edges, and are pointed at the tip. The cutting edge is

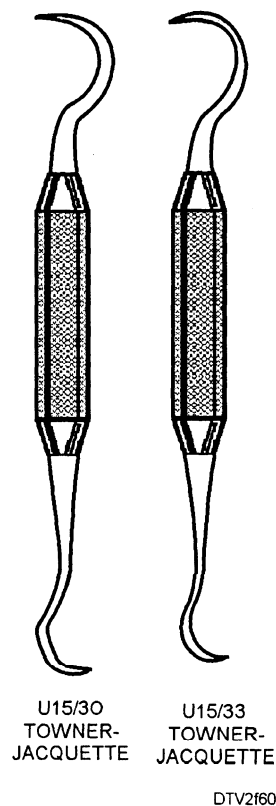


Figure 6-7.—Sickle scaler.

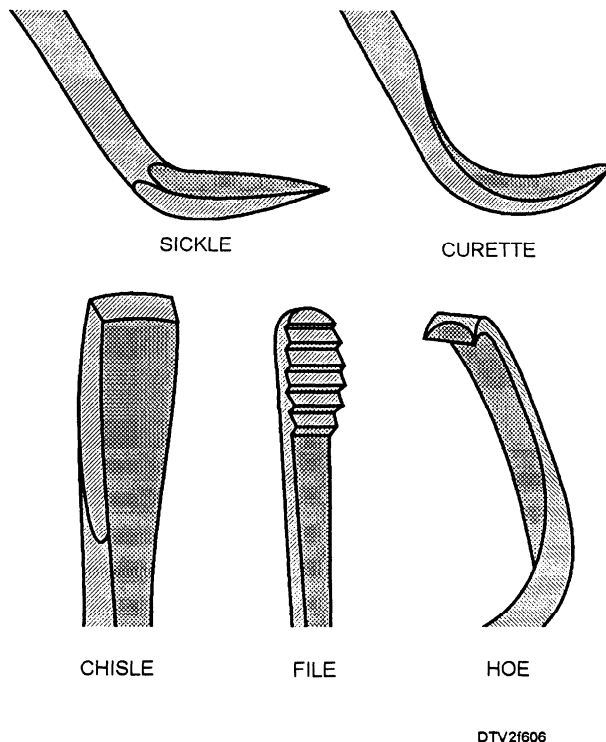


Figure 6-6.—Scaling and root planing instruments.

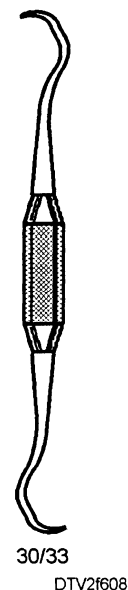


Figure 6-8.—Jacques double-ended scaler.

inserted under the ledge of calculus and used with a pull stroke.

### Curettes

The curette is the instrument of choice for subgingival calculus removal, root planing, and removing soft tissue from the periodontal pocket. The

working ends of curettes form a spoon-shaped face and a rounded back. In a cross-section, the curette blade appears semicircular rather than triangular (shape of the sickle scaler). Two basic types of curettes are the universal and the area specific.

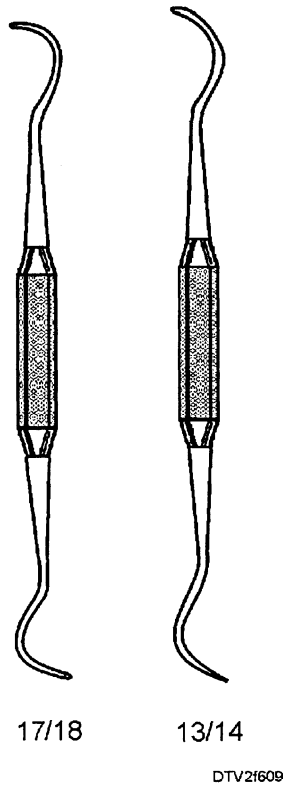


Figure 6-9.—McCalls curettes.

**UNIVERSAL CURETTE.**—The universal curette is a paired instrument designed to adapt to **most** areas of the dentition by altering and adapting the finger rest, fulcrum, and hand position. Two parallel cutting edges are formed, one on either side of the face. Either cutting edge can be used. Universal instruments come in a variety of sizes and shank lengths. Some commonly used instruments are the Columbia #13/14 and the McCalls #13/14 and #17/18. The Columbia #13/14 has a true universal application, whereas the McCalls has two cutting edges on each blade that are better suited to certain areas of the mouth. The McCalls #13/14 are best suited for use on bicuspid and the #17/18 for molars (fig. 6-9).

**AREA SPECIFIC.**—Area specific curettes differ from the universal curettes in several ways. First, they are a set of several instruments designed and angled to adapt to a specific anatomic area of the dentition. Second, these curettes are designed with only one cutting edge. Area specific curettes are the best choice for subgingival scaling and root planing because they provide the best adaptation to the complex root anatomy.

The Gracey curettes are paired, area-specific instruments, that have similar blades with different angulations and contra-angulations of the shank. Figure 6-10 illustrates the complete set of double-ended Graceys. Next we will discuss where each Gracey is used on the tooth surface being scaled or root planed.

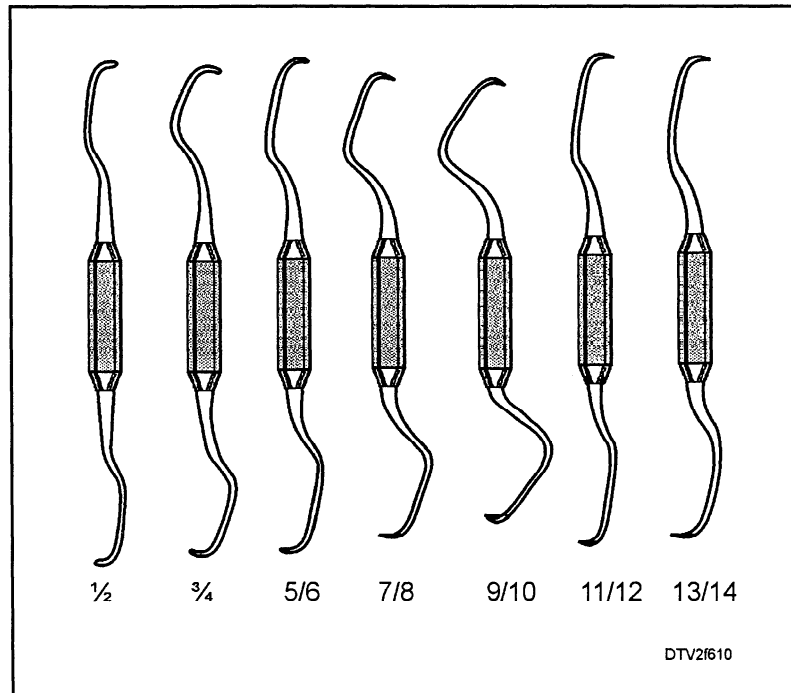


Figure 6-10.—Gracey area specific curette set.

- Gracey #1/2—Facial root surfaces of incisors and cuspids.
- Gracey #3/4—Lingual surfaces of anterior teeth.
- Gracey #5/6—All surfaces of anterior teeth and some bicuspid.
- Gracey #7/8 and #9/10—Facial and lingual surfaces of posterior teeth.
- Gracey #11/12—Mesial surfaces of posterior teeth and for furcations and depressions.
- Gracey #13/14—Distal surfaces of posterior teeth.

## Files

Periodontal files are strong instruments used to crush large calculus deposits and to smooth the tooth surface at the cemento-enamel junction when the dentist is root planing.

## Chisels

Use of the periodontal chisel scaler is extremely limited. It is used solely for the removal of heavy supragingival calculus deposits that bridge open interproximal spaces of anterior teeth.

## Hoes

Periodontal hoe scalers are usually limited to removal of large ledges of calculus located supragingivally and slightly subgingivally. For example, calculus that rings the tooth on the facial, lingual, and distal surfaces of teeth that have no adjacent posterior teeth can be removed with the hoe.

## Dental Implant Scaling Instruments

Special scalers made of plastic or nonmetallic material are designed for cleaning the abutments of dental implants. The special material enables optimum cleaning without damaging the abutment surface. **Never** use metal scalers and curettes, including some and or ultrasonic tips, because they may damage the smooth surface of the implant.

Several versions of implant scales are available to permit access in all situations. We will discuss where on the tooth the implant scalers (fig. 6-11) are used.

- Universal scaler—Can be used in most areas to clean the abutment surfaces and apical portion of the framework.

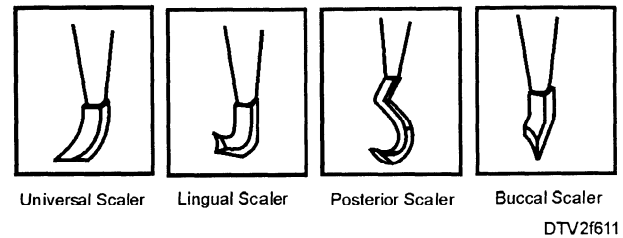


Figure 6-11.—Plastic or nonmetallic scaling instruments.

- Lingual scaler—Designed for cleaning the lingual side of the abutment.
- Posterior scaler—Designed to enable access to the posterior lingual abutment surfaces.
- Buccal scaler—Cleans the buccal surface of the abutment.

## PERIODONTAL SURGERY INSTRUMENTS

To be an effective and efficient dental assistant, you must be familiar with the instruments the dentist may use during surgery. Some of the most commonly used periodontal surgery instruments are periosteal elevators, periodontal knives, periodontal surgery curettes and sickles, and periodontal surgery chisels, hoes, and files.

## PERIOSTEAL ELEVATORS

The periodontal periosteal elevator illustrated in figure 6-12 is very similar in shape to the prosthetic laboratory wax spatulas. It is designed with one end that is rounded and the other pointed for delicate tissue retraction.

## PERIODONTAL KNIVES

Periodontal knives (fig. 6-13) may be double- or single-ended in paired sets. The knives have a slightly angled, crescent-shaped blade. Many different types of knives are designed to make initial incisions for gingivectomy and gingivoplasty procedures. Other knives are used to excise (complete the removal of) the interproximal tissue in gingivectomy and gingivoplasty procedures.

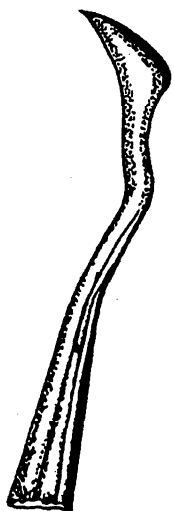
## PERIODONTAL SURGERY CURETTES AND SICKLES

These instruments are larger and heavier curettes and sickles than those used in scalings and are often needed during periodontal surgery. They are designed



DTV2f612

Figure 6-12.—Periodontal periosteal elevator.



DTV2f613

Figure 6-13.—Periodontal knife.

to remove granulation, fibrous tissue, and hard-to-remove subgingival calculus deposits.

### PERIODONTAL SURGERY CHISELS, HOES, AND FILES

Because of bone loss accompanied in some cases of periodontal disease, it may be necessary for the

periodontist to recontour the bone during periodontal surgery. In such cases, the dentist may use periodontal surgery chisels, hoes, and files. They are also larger and heavier than those used in scaling and root planing.

### ELECTROSURGERY APPARATUS

Electrosurgery equipment uses a high-frequency electric current to cut tissue. The electrode attachment used will depend on the extent of the tissue removal required. One advantage of using the electrosurgery is coagulation and the control of bleeding.

### ROUTINE PERIODONTAL PROCEDURES

Treatment of periodontal disease and occlusal trauma may include several nonsurgical procedures, such as equilibration, periodontal scaling, scaling and root planing, and root desensitization. Gingival curettage, which is considered a periodontal surgery procedure, is commonly performed in conjunction with scaling and root planing.

### OCCLUSAL EQUILIBRATION

Occlusal interferences and oral habits, such as bruxism and clenching, can cause the mandible to shift out of its normal position when the maxillary and mandibular teeth occlude. This chronic shifting of the mandible during oral functions is traumatic to the joint, and may cause muscle spasms, and hypersensitivity and hypermobility of teeth. The elimination of occlusal interferences and establishment of favorable occlusal forces on the teeth is called *occlusal equilibration*. The two types (limited or complete) are discussed below.

#### Limited Occlusal Adjustment

Limited occlusal adjustment involves reshaping the occlusal or incisal surfaces of the teeth by grinding to improve inter-arch tooth contact relationships. This type of adjustment is limited to one or more selective teeth being reshaped.

#### Complete Occlusal Adjustment

Complete occlusal adjustment involves reshaping the occlusal and or incisal surfaces by grinding to achieve correct contact during functional movement (grinding side- to-side and sliding the jaw forward). A complete adjustment involves all or nearly all of the teeth.

## Materials and Procedures

You will need to prepare a tray with a mirror, explorer, periodontal probe, cotton forceps, articulating paper forceps, various rotary stones, rubber wheels and points, high-speed handpiece, articulating paper, occlusal waxes, and gauze sponges. An occlusal equilibration may require that a study cast be made to determine where the occlusion must be adjusted. During the procedure, the dentist uses articulating paper or occlusal wax on the patient's teeth for an accurate registration of occlusal contacts. You will use the gauze sponges to wipe off marks and keep the teeth dry to assure the accuracy of marking. The dentist removes the occlusal interferences by selectively grinding the teeth with a diamond stone in the high speed handpiece. The occlusion is rechecked and the adjusted tooth surfaces are polished with abrasive rubber wheels or points.

### PERIODONTAL SCALING, ROOT PLANING, AND GINGIVAL CURETTAGE

These three procedures are often performed by the dentist or hygienist in conjunction with one another to decrease periodontal inflammation. *Scaling* procedures performed independently involve the complete removal of supra- and sub-gingival calculus and bacterial debris with hand instruments or mechanical (ultrasonic) instrumentation. This procedure is usually done by sextants or quadrants of the patient's mouth.

*Scaling and root planing* performed together involve more extensive scaling procedures to remove subgingival calculus located in the periodontal pockets and smoothing of root surfaces. *Scaling and root planing* procedures usually are done by sextants or quadrants of the patient's mouth with local anesthetic.

*Gingival curettage* is the intentional removal of the soft tissue wall of a periodontal pocket done under local anesthesia.

### ROOT DESENSITIZATION

Periodontal patients may experience root sensitivity when elimination of periodontal pockets exposes root surfaces. Root desensitization involves the application of agents or drugs to exposed root surfaces to reduce or eliminate dentinal sensitivity.

## PERIODONTAL SURGERY PROCEDURES OF THE SOFT AND HARD TISSUES

Periodontal surgery procedures involving the soft tissue include gingivectomy, gingivoplasty, periodontal flap, and soft tissue graft procedures. Surgery of the hard tissue includes osseous surgery, metallic implants, root amputations, hemisections, and bicuspidization. Your responsibilities in periodontal surgery are similar to those of oral surgery. To properly carry out your duties, you must know which instruments and instrument packs the periodontist desires. You should have all instruments and supplies needed for the particular periodontal treatment set up before the arrival of the patient. A typical periodontal surgery tray is shown in figure 6-14.

### GINGIVECTOMY

Gingivectomy is the surgical excision of the soft tissue wall of suprabony pockets (above the alveolar bone) to eliminate periodontal pockets. The procedure is limited to gingival pockets where a wide band of attached gingiva exists. This surgery results in gingival recession and may expose tooth roots. If a gingivectomy is indicated, the gingival tissue should first be cleared of acute infection. Gingivectomy may be performed with either a scalpel or periodontal knife.

### GINGIVOPLASTY

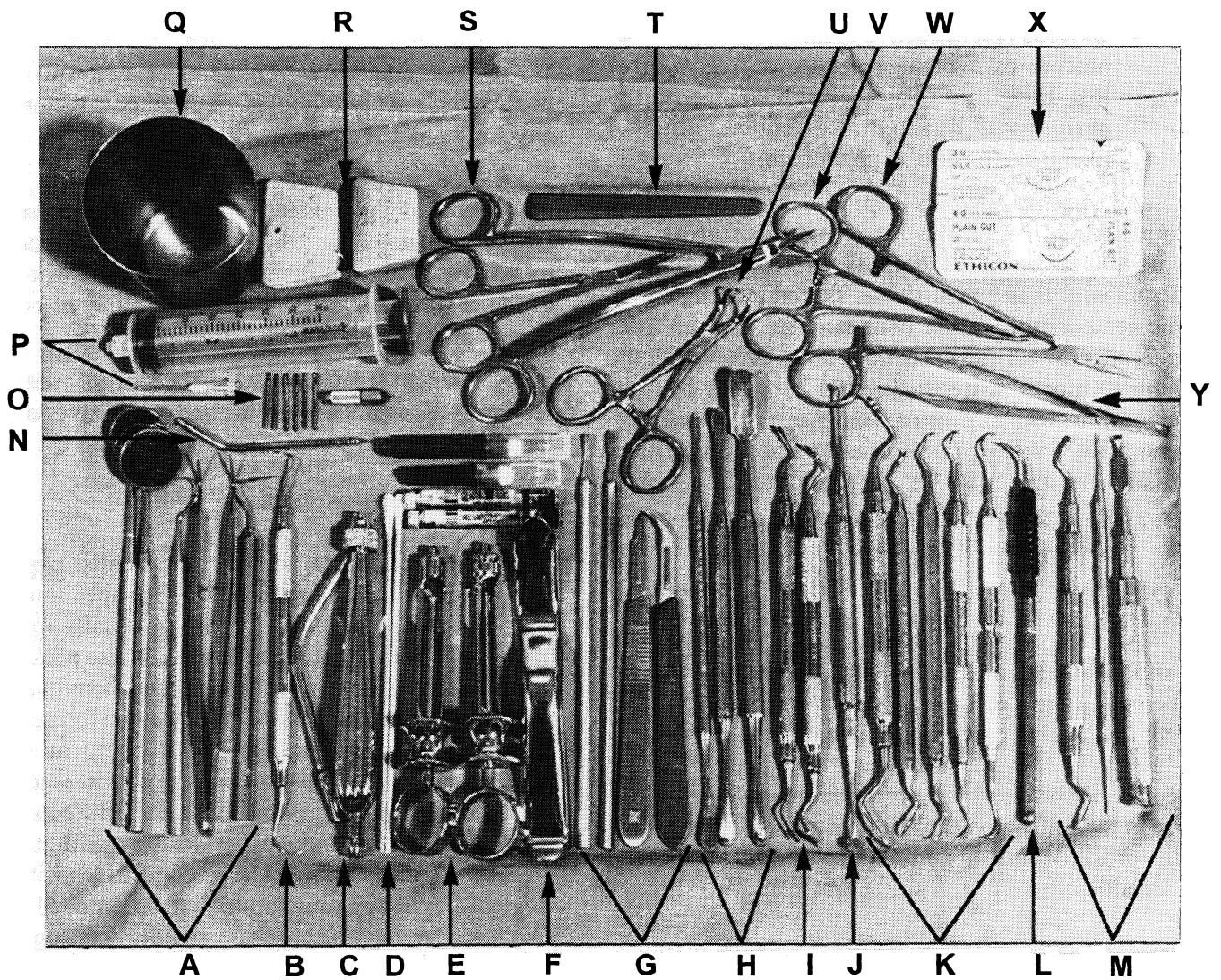
This procedure involves the reshaping of gingival deformities to improve form and function. This technique is useful when gingival overgrowth or gingival craters exist. A gingivoplasty is done to remove excess tissue and recontour the gingiva. Gingivoplasty may be performed with a periodontal knife, a scalpel, or electrosurgery.

### PERIODONTAL FLAPS

A *periodontal flap* is a technique used in an attempt to correct gingival defects. With the flap technique, a section of the gingiva and or mucosa is surgically separated from the underlying tissues. The roots are thoroughly planed and the gingiva is repositioned to correct a gingival defect and sutured into place.

### PERIODONTAL SOFT TISSUE GRAFTS

A *soft tissue graft* involves the complete separation of tissue from the donor site and placement in another location to correct periodontal or mucogingival defects. You must exercise special care to avoid aspiration of the tissue graft with the suction equipment.



- |                                                                                                                                                                                                                                                                                                                                            |                                                                                                                                                                                                                                                                                             |                                                                                                                                                                                                                                                                         |
|--------------------------------------------------------------------------------------------------------------------------------------------------------------------------------------------------------------------------------------------------------------------------------------------------------------------------------------------|---------------------------------------------------------------------------------------------------------------------------------------------------------------------------------------------------------------------------------------------------------------------------------------------|-------------------------------------------------------------------------------------------------------------------------------------------------------------------------------------------------------------------------------------------------------------------------|
| <p><b>A.</b> Basic Dental Set<br/> <b>B.</b> Furcation probe<br/> <b>C.</b> Surgical Suction Tip and Handle<br/> <b>D.</b> Cotton Tip Applicators<br/> <b>E.</b> Anesthetic Syringes, Carpules and needles<br/> <b>F.</b> Minnesota Retractor<br/> <b>G.</b> Scalpels, Beaver &amp; #3 with Blades<br/> <b>H.</b> Periosteal Elevators</p> | <p><b>I.</b> Periodontal Knives<br/> <b>J.</b> Bone Curettes<br/> <b>K.</b> Periodontal Curettes<br/> <b>L.</b> Ultrasonic Tip<br/> <b>M.</b> Bone Chisels<br/> <b>N.</b> 3-Way Syringe Tip<br/> <b>O.</b> Burs<br/> <b>P.</b> Irrigating Syringe &amp; Needle<br/> <b>Q.</b> Metal Cup</p> | <p><b>R.</b> Adult and Pedo Mouth Props<br/> <b>S.</b> Scissors: Iris and Dean<br/> <b>T.</b> Sharpening Stone<br/> <b>U.</b> Towel Clamps<br/> <b>V.</b> Curved Hemostat<br/> <b>W.</b> Needle Holder<br/> <b>X.</b> Suture Material<br/> <b>Y.</b> Tissue Forceps</p> |
|--------------------------------------------------------------------------------------------------------------------------------------------------------------------------------------------------------------------------------------------------------------------------------------------------------------------------------------------|---------------------------------------------------------------------------------------------------------------------------------------------------------------------------------------------------------------------------------------------------------------------------------------------|-------------------------------------------------------------------------------------------------------------------------------------------------------------------------------------------------------------------------------------------------------------------------|

Figure 6-14.—Periodontal surgery tray.

## OSSEOUS SURGERY

As inflammation proceeds into the deeper supporting tissues, the bone resorbs, creating defects or deformities. The most common deformities occur interproximally as saucer-shaped defects, known as

craters. Several surgical procedures are designed to treat these defects.

- Osteoplasty—Refers to reshaping the alveolar bone without removing tooth supporting bone.

- **Ostectomy**—Includes removal of tooth supporting bone in the treatment of periodontal disease.
- **Osseous reconstructive surgery**—This involves procedures involving regeneration (regrowth) of lost bone, and the reestablishment of the periodontal ligament, cementum, gingival fibers, and junctional epithelium.

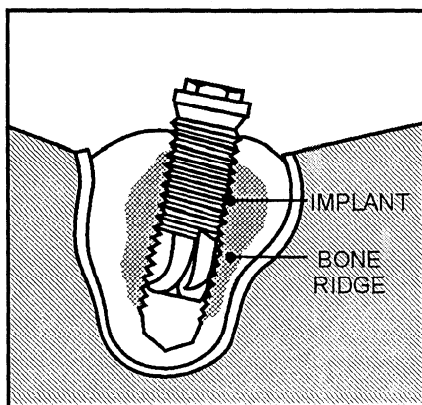
An *osseous graft* is a procedure that involves implanting living tissue or inert material into periodontal osseous defects to regenerate new periodontal attachment (bone, periodontal ligament, and cementum). Donor bone may be obtained from adjacent cortical and cancellous bone, mixed with the patient's blood. Other sources for bone may be from edentulous ridges, extraction sites, or maxillary tuberosity. Bone can also be obtained from tissue banks or various crystalline synthetic substances, such as hydroxyapatite over a 4-6 month period. Grafts may also be placed in osseous defects.

### METALLIC IMPLANTS

A method of tooth replacement involves the surgical implantation of coated metal implants into the bone ridges of edentulous areas (fig. 6-15). The root implant becomes firmly attached to the bone and a new crown is placed upon it to support fixed or removable bridges. The procedures involved in the use of metallic implants require a team approach from the prosthodontics, periodontic, and oral surgery specialties.

### ROOT AMPUTATION, HEMISECTION, AND BICUSPIDIZATION

Sometimes the bone loss is so great around the root of a multirooted tooth that a root or section of the tooth



DTV2f615

Figure 6-15.—Implant placement.

must be removed. The remaining portion of the tooth can be saved if sufficient periodontal support is present. Endodontic treatment is **required** before treatment of the remaining portion of the tooth.

- **Root amputation**—The complete removal of one or more roots of a multirooted tooth, without removal of any portion of the crown.
- **Hemisection**—The surgical sectioning of a multirooted tooth through the furcation area so that the blocked, defective, or periodontally involved root or roots may be removed along with the associated portion of the crown. An artificial crown is required on the remaining half of the crown.
- **Bicuspidization**—A multirooted tooth is sectioned through the furcation and both halves of the tooth are retained.

### SURGICAL DRESSINGS

During periodontal surgery, the dentist exposes soft tissues and sometimes bone, leaving open wounds. Surgical dressing materials (packs) are usually applied to the wounds as a protective barrier. These packs not only protect the area by preventing food from injuring the surgical area, but also soothe and aid in the healing process. Your primary duty will be to mix the ingredients and form the dressing the dentist places in the patient's mouth. Follow the manufacturer's instructions for mixing. Most dressing will stay in place for 5-7 days. During the postoperative visit, the surgical dressing and any sutures will be removed. The dental officer may elect to place another dressing over the surgical area if the healing process is delayed.

### INSTRUMENT SHARPENING

Periodontal cutting instruments must be kept sharp by a correct sharpening technique. To be able to recognize when instruments require sharpening is extremely important. To determine if an instrument is sharp, you must be familiar with each instrument's cutting edge(s). Under good lighting, examine the cutting edge using a magnifying glass, or by looking directly at the edge while slightly turning the instrument. A sharp cutting edge will not reflect light and appears as a line. A dull edge will reflect the light, creating a glare because the edge has been rounded off.

### SHARPENING DEVICES

The correct sharpening device is critical for a good cutting edge. Hard felt wheels are recommended for



periodontal knives. Sharpening stones are recommended for curettes, chisels, and scalers.

Sharpening stones are available in various grits (textures) and designs to meet a particular need. The Ruby and Arkansas stones are the most commonly used. The Ruby stone is fairly coarse, cuts rapidly, and is used primarily for initial sharpening of very dull instruments. The Arkansas stone has a fine grit and is used to attain a sharp edge.

Depending on their design and method of use, sharpening stones are either mounted or unmounted. Some are mounted on mandrels for insertion into the dental handpiece, others are mounted in mechanical devices known as mechanical sharpeners. Unmounted stones may be rectangular, cylindrical, or have a special shape. These stones are often lubricated with water or oil to avoid clogging the stone's pores with metal particles as the instrument is ground.

Regardless of the device used, instruments are sharpened by grinding or polishing the surfaces that form the cutting edge. Instruments should be sharpened after every use. If the cutting edge has been markedly reduced because of sharpening, discard the instrument rather than risking the chance of breaking it during a treatment procedure. Keep in mind that the amount of metal ground away by mounted stones is much greater than that removed by unmounted stones.

## PERIODONTAL KNIFE SHARPENING

The most commonly used periodontal knives are the Kirkland #15 and #16, and the Orban #1 and #2. Both types may be sharpened with a hard felt wheel mounted on a dental lathe or handpiece. It is difficult to maintain the knife's functional shape and blade bevel with either technique.

Kirkland knives have three cutting edges to sharpen, the inner, outer, and back edge (figure 6-16). The Orban knives have only two cutting edges, the inner and outer edges (figure 6-17). Apply an abrasive, such as chrome rouge, to the felt wheel to aid in the sharpening process. Sharpen both sides of each edge. Use the following technique:

- Hold the knife handle between your thumbs and forefingers (both hands). Stabilize your hands or elbows on the work bench.
- Hold the knife so that the felt wheel rotates away from the cutting edge.

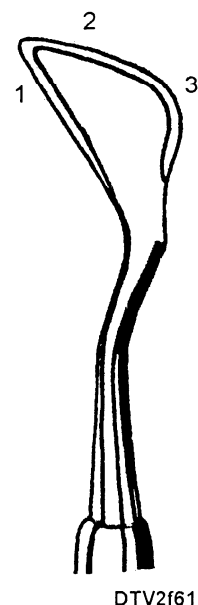

Figure 6-16 .-Kirkland knife cutting edges: inner (1), outer (2), and back (3).



Figure 6-17.—Orban knife cutting edges: inner (1) and outer (2).

- Place the knife against the wheel at an angle consistent with the bevel of the blade. Gently apply the knife to the wheel. Sharpen both sides of each cutting edge. Check each edge for sharpness.
- If using a stone, establish the same alignment as with the felt wheel, then draw the stone across the bevel of the blade.

## PERIODONTAL CURETTE SHARPENING

Curettes are the most commonly used scaling instruments. McCall curettes (universal curettes) have two cutting edges and are sharpened on both sides. Gracey curettes are sharpened only on the outer curve.

Both have a rounded tip that must be maintained during sharpening (except the McCall #13/14).

When using a stationary stone, hold the curette in a modified pen grasp and establish a finger rest at the edge of the stone. Draw the side of the blade toward you. Because the curette is curved, you must repeat this process until the entire arc of the cutting edge is sharpened. Be sure to lubricate the stone during the sharpening procedure.

When sharpening a curette on a mounted stone, be sure the wheel rotates away from the side of the blade.

### PERIODONTAL CHISEL SHARPENING

The No. 1 and No. 2 Ochsenshein chisels are the most commonly used periodontal chisels. They have three cutting edges, a flat edge on the tip and a curved edge on each side of the tip. The edges to be sharpened are up, toward you, on the convex side of the chisel head. The cutting edges on the No. 1 Ochsenshein are reversed. They are on the concave side of the head. Another commonly used chisel, the TGO chisel, is a smaller version of the Ochsenshein chisel. Follow these steps when sharpening a periodontal chisel:

- Use a flat Arkansas stone to sharpen the edge on the tip of the chisel. Position the blade on the stone at an angle conforming to the bevel of the blade. Push the blade across the stone in the direction of the cutting edge.
- Use a cylindrical sharpening stone or one with rounded edges to sharpen the curved edges on the sides of the chisel head. Position the stone on the blade at an angle consistent with the bevel of the blade. Twist or rotate the stone until the edge is sharp.
- DO NOT rotate the sharpening stone over the cutting edge, it will round and dull the edge.

### SCALER SHARPENING

Sickle scalers and hoes are the most commonly used scaling instruments. Sickle scalers have two cutting edges that form a point where the facial and lateral surfaces meet (figure 6-18). Sharpen the sickle scaler by grinding the facial and lateral surfaces on a stationary stone being careful to maintain the sharp point.

To sharpen the facial surface, hold the edge flat against the side of the stone and draw the instrument back and forth.

To sharpen the lateral surface, position the surface against the stone and draw the instrument across the stone in the direction of the cutting edge. Repeat this procedure until both lateral surfaces are sharp.

A hoe scaler has only one edge. Sharpen the hoe by grinding only the outer surface of the cutting edge. The outer surface and inner blade surfaces form a 45° angle, so you must maintain this angle against the stone. Draw the instrument across the stone in the direction of the cutting edge. Repeat this procedure until the edge is sharp.

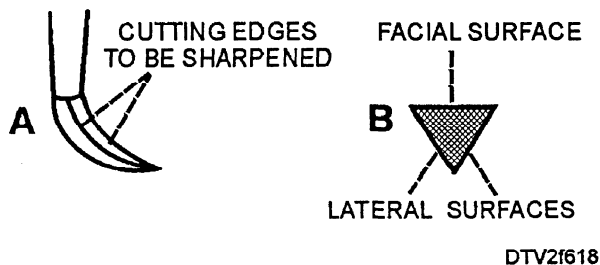


Figure 6-18.—Sickle sealer: A. Tip of sickle sealer; B. Cross section.

## CHAPTER 7

# ENDODONTIC ASSISTANCE

### DENTAL SPECIALTY OF ENDODONTICS

Before major advances in the treatment of diseases of the dental pulp and periapical tissues were made, dentists extracted many teeth needlessly. Endodontics is the dental specialty primarily concerned with these diseases. In some dental clinics, an endodontist is assigned exclusively to this specialty. Often, some of the restorative dentists spend part of their time seeing patients who require endodontic treatment, also known as root canal therapy. As a basic dental assistant, you must be familiar with the following aspects of endodontics:

- Functions, causes, and diagnosis
- Types of procedures
- Steps in pulpectomy and root canal treatment
- Steps in apicoectomy and associated procedures

You must also be able to identify:

- Endodontic instruments
- Endodontic materials
- Endodontic equipment

When involved with endodontic procedures, you must follow BUMEDINST 6600.10, *Dental Infection Control Program*. Strict compliance to sterile technique, sterilization, and disinfection is absolutely essential in endodontic treatment.

### FUNCTION

The primary purpose of endodontics is the treatment of diseases of the pulp and periapical tissues. The goal of this treatment is to retain the natural teeth rather than extract them. Often, the endodontic patient's initial appointment is of an urgent nature because of the associated pain or infection. Understanding the causes of pulp disease and how a diagnosis is reached will increase your ability to be an effective endodontic assistant.

### CAUSES

The dental pulp can be injured in several ways. Some injured teeth can be treated and returned to

normal. Other injured pulpal tissue may undergo necrosis (die) after the slightest injury. Some of the most common causes of injury to the pulp include dental caries (covered in *Dental Technician*, Volume 1, NAVEDTRA 12572, chapter 5, "Oral Pathology"), traumatic blows to the teeth, pulp exposure (covered in *Dental Technician*, Volume 1, NAVEDTRA 12572, chapter 6, "Emergency Treatment of Oral Diseases and Injuries"), chemical irritation, and thermal irritation.

### Traumatic Blows

Traumatic blows to the teeth can result from situations such as common household accidents, auto collisions, or athletic injuries. A sharp blow to one or more teeth can result in fracture of the crown or root, or even the avulsion (forcefully knocked out of the socket) of the complete tooth, cutting off the blood flow to the pulp.

### Chemical Irritation

Chemical irritation after placement of certain chemical substances commonly used in restorative procedures can cause pulp injury or death. Another cause of chemical irritation is a faulty restoration, which allows oral fluids to leak between the restoration and dentin.

### Thermal Irritation

Thermal irritation can cause pulp injury and patients will experience discomfort when they inhale cold air through their mouths. If metallic restorative materials are placed close to the pulp, the patient will experience thermal irritation.

### DIAGNOSIS

The diagnosis of pulp and periapical conditions must precede the treatment. Endodontic diagnosis is a result of the skillful use and interpretation of several methods. Some of the more common methods are discussed in the paragraphs that follow.

## Dental History

The patient's dental history is a valuable aid to the dentist. It provides communication between the dentist and the patient, and allows the dentist to trace the history of the complaint through symptoms described by the patient. Often, patients reveal valuable information regarding previous injuries to the teeth, even though they may have occurred many years earlier.

## Clinical Examination

A clinical examination of the oral cavity allows the dentist to visually inspect the patient's mouth providing clues to the nature of the patient's problems. Such clinical signs as discoloration of the teeth, crown fracture, gross caries, swelling, abnormal soft tissue, and a draining abscess can be identified during a clinical examination.

## Radiographs

Radiographs of the teeth and bone are one of the most valuable diagnostic tools the dentist has to evaluate structures that cannot be seen by clinical examination, such as the pulp and periapical tissues. The presence of bone loss in the periapical area in response to a necrotic pulp can be detected on a radiograph as a dark area surrounding the apex of the root. The presence of this dark area, or radiolucency, on a dental radiograph is an important feature used to diagnose pulp and periapical disease. Periapical pathology appears as radiolucencies on a radiograph.

Radiographs can also reveal possible causes of pulpal injury before bone resorption occurs. Root fractures, deep caries, and previous pulp exposures are some examples of possible causes of pupal injury detected on a radiograph. An accurate radiograph can reveal root length, abnormal root curvature, and abnormal calcification, which is helpful information in determining if the tooth can be treated endodontically. A radiograph, properly exposed and processed, can last indefinitely and provide a permanent record of the condition of the patient and be used for future reference. Comparison of the initial radiographs with postoperative radiographs is a valuable index to determine if the treatment was successful.

## Pulp Testers

Two of the common pulp testers used primarily to determine whether the pulp is vital or necrotic

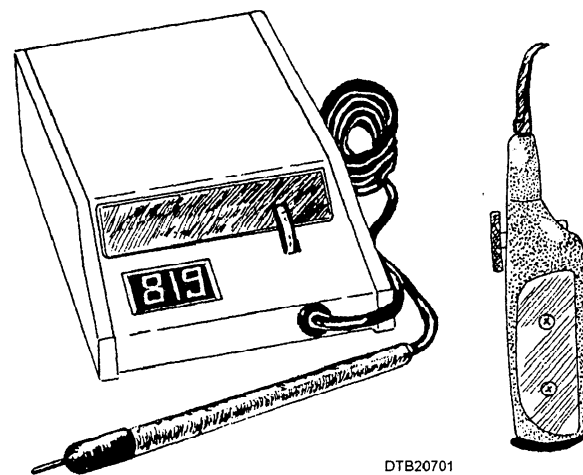
(nonvital) are shown in figure 7-1. Electric current is used to stimulate nerve fibers in the pulp through the dentin layer. General information about the status of the pulp is obtained by comparing the response of a suspected tooth with that of a normal tooth (control tooth) of the same type on the opposite side of the mouth. The amount of current delivered to a tooth is indicated by a numerical scale. The patient holds the ends of the probe to complete the circuit. Higher numbers on the scale indicate that more current is delivered to the tooth. As the current is increased gradually, the patient is instructed to let go of the probe whenever a sensation is first detected within the tooth.

Generally, the sensation is described as a slight tingling or warm feeling. The number at which a response occurs is recorded and compared with the test results of the control tooth. A tooth with a necrotic pulp will not respond to even the most intense electrical stimulation. A dying pulp can produce a variety of responses, depending on the state of the pulp at the time of the test. However, the number readings are relative and cannot be used to diagnose vital pulp.

## Thermal Sensitivity Test

The thermal sensitivity test exposes a tooth to extremes in temperature and provides an accurate method of identifying the problem tooth, as well as determining the status of its pulp. The two most common diagnostic tests are cold and heat.

**COLD TEST.**—The cold test can be done easily by placing a cylinder or stick of ice on the tooth. First, the suspected tooth is isolated and dried, then the ice stick, held in a gauze square, is applied to the cervical area of the tooth. Healthy teeth will respond positively to a cold stimulus, but the sensitivity should resolve quickly. If the pulp is inflamed, the patient will



DTB20701

Figure 7-1.—Two common pulp testers.

experience a lingering sensation to cold. Other cold test materials that can be used are ethyl chloride and skin refrigerants.

**HEAT TEST.**—The heat test consists of isolating the suspected tooth with a rubber dam and applying a warm liquid (hot water or coffee) to the tooth. The warm liquid should not be hotter than 140°F and should not burn your skin. If the tooth reacts with a painful response that lingers a few seconds after the heat is removed, **pulpitis** may be present. If the patient experiences a violent pain reaction to the heat and is relieved by a cold application, the pulp is irreversibly inflamed and will need a root canal. If the patient experiences no response to heat or cold, the pulp is necrotic.

### **Percussion**

Percussion is the gentle tapping of the crown of the tooth with the finger or the end of a mirror handle to determine the presence of periapical inflammation. If a patient has an acute inflammation at the apex of the root, percussion stimulates the already inflamed area and pain results. An abnormal dull sound may signify a root that has attached to the bone. Several normal, opposing, and adjacent teeth should be checked for comparison.

### **Palpation**

Palpation is the application of the finger with light pressure to areas of the mouth to detect normal or abnormal tissue. Swelling, pain, and degree of rigidity of tissues are determined by palpation. When using palpation in the diagnosis of periapical diseases, the fingers are pressed gently against the soft tissue overlying the bone and apexes of the teeth to compare the tissues.

### **Mobility Test**

The mobility test is done by moving the tooth between the handles of 2 instruments. Abnormal mobility of a tooth when compared to healthy teeth signifies temporary or permanent loss of supporting alveolar bone or trauma. Mobility of the tooth tends to increase if an infection or injury is long standing and has affected the supporting periodontium tissues.

### **Selective Anesthesia**

Selective anesthesia can be of assistance if the patient cannot accurately determine which teeth are the

source of discomfort. If other diagnostic tests have narrowed the choice down to two teeth, one tooth can be anesthetized to determine if the pain disappears. If the pain does not disappear until the second tooth is anesthetized, the second tooth is the probable source. Selective anesthesia is most effective when the choice is between a maxillary and a mandibular tooth.

### **Transillumination**

Transillumination uses fiber optic lighting to allow an intense, concentrated light to pass through the tooth from the lingual to the facial aspect. This is done most effectively on anterior teeth because of their structure and location in the arch. The light transmits through the enamel and dentin, permitting the detection of caries or a fractured crown.

## **TYPES OF PROCEDURES**

There are several types of endodontic procedures. The more common procedures include pulp capping, pulpotomy, pulpectomy, and root canal therapy. Occasionally other procedures such as incision and drainage, apicoectomy, periapical curettage, retrograde filling, root amputation, and bleaching of teeth are indicated.

### **PULP CAPPING**

In an attempt to protect the pulp against additional injury and stimulate pulp regeneration, an application of protective dressing, such as calcium hydroxide, is placed over an exposed or nearly exposed vital pulp. This treatment is referred to as **pulp capping**. When the pulp is exposed mechanically during tooth preparation, placing a pulp cap directly over the exposed pulp is referred to as a **direct pulp cap**. If deep caries are present and a danger of exposing the pulp exists, placing a pulp cap over a layer of remaining dentin is termed an **indirect pulp cap**. If pulp capping is not effective, the pulp can be treated with endodontic therapy.

### **PULPOTOMY AND PULPECTOMY**

A *pulpotomy* is the surgical removal of the coronal part (pulp chamber) of an exposed vital pulp. The pulp is retained in root canals with the exposed ends covered with applications of calcium hydroxide, zinc oxide and eugenol, and zinc phosphate cement to preserve its vitality and function. If indicated, root canal treatment is completed at a later date.

The most common endodontic procedure is the *pulpectomy*, which is the removal of the entire pulp (chamber and canal). After removal of the pulp, root canal therapy is performed.

## **ROOT CANAL THERAPY**

This treatment consists of the internal debridement, cleaning, shaping, and permanent filling of the root canal system. During the therapy, the dentist may place medications and temporary filling material. The therapy may vary slightly because of the type of tooth and number of canals in the tooth.

## **INCISION AND DRAINAGE**

An acute periapical abscess may indicate a need for incision and drainage to eliminate the infection along with endodontic treatment. Incision and drainage can be effective when the swelling and infection are localized in the alveolus with a clearly defined point on the surface of the mucosa. Endodontic treatment should be initiated at the same appointment to remove the necrotic infected pulp. Although the periapical abscess usually is accompanied by severe pain, it is not advisable to inject a local anesthetic solution directly into the infected area when draining the abscess because of the danger of spreading the infection. Instead, block anesthesia and infiltration away from the infected area. Local anesthesia may not be as effective because of changes in the pH of the tissues in the presence of the infection. The patient must be informed to expect momentary discomfort when the area is lanced, but the pain is immediately and significantly reduced after the incision is made and the exudate (pus) is expressed. If indicated, a drain is placed to provide short term drainage and to prevent the opening from closing prematurely until the infected area drains. The dentist may prescribe antibiotics. Once the infection is controlled and the swelling and tenderness subside, the dentist will treat the tooth endodontically.

## **APICOECTOMY AND PERIAPICAL CURETTAGE**

An *apicoectomy* (root end resection) is the surgical removal of the apical portion of the tooth through a surgical opening made in the overlying bone and gingival tissues. An apicoectomy usually is performed in conjunction with periapical curettage after the body fails to heal after endodontic treatment. *Periapical curettage* is the surgical removal of apically inflamed

tissue associated with the tooth through an opening made in the overlying bone and gingival tissues. Treatment is limited to curettage of the area to remove all diseased material. Conditions that may indicate the need for an apicoectomy include:

- Persistent, local infection following endodontic treatment.
- Canal filling materials or medications extruded into the periapical tissue.
- A broken instrument lodged in the canal preventing complete filling.
- Obstruction caused by a calcified root canal.
- Extreme curvature of the canal preventing access to the apex of the root.
- Root canals that are unfilled or debrided.

## **RETROGRADE FILLING**

This is a method of sealing the apical end of the root canal by placing a restoration in the root apex. This is usually done in conjunction with the apicoectomy. Superortho-ethoxybenzoic acid (EBA) cement or an intermediate restorative material such as Zinc Oxide and Eugenol (ZOE) is used as the filling material because they will not react with any moisture that may be present in the root canal. Some dentists prefer to use composite filling material.

## **ROOT AMPUTATIONS**

Occasionally, a multirouted tooth requiring endodontic treatment may have a root that is impossible to obtain an adequate apical seal or is affected by periodontal disease. When the other roots of the teeth are treatable, rather than extracting the entire tooth, the untreatable root is amputated and removed. The opening to which the amputated root was attached is sealed with amalgam similar to that of an apicoectomy procedure. The retained section of the tooth is treated endodontically before amputation.

## **BLEACHING OF DISCOLORED TEETH**

The use of chemical agents may be used to remove discoloration from the crowns of vital or nonvital teeth. Nonvital teeth may discolor because of pupal hemorrhage into the dentinal tubules after traumatic injury of the tooth, or from the use of medications that cause staining when used in endodontic therapy. In such cases, the appearance of the discolored teeth may be improved dramatically by bleaching the tooth.

## STEPS IN PULPECTOMY AND ROOT CANAL TREATMENT

As in all efficient assisting, you will need to anticipate the dentist's needs. In endodontics, your duties consist of such tasks as performing infection control procedures, preparing for the treatment, aiding in the placement of the rubber clam, irrigating and aspirating to flush the area, mixing materials, and passing instruments. You will need to have knowledge of the treatment procedure and sequence to effectively anticipate the dentist's needs and to schedule appointments.

### APPOINTMENT SCHEDULING

Root canal therapy may take one or more appointments based on the number of canals and severity of infection. Before a canal can be filled, the canals must be completely cleaned. Filling the canal while infective organisms are still present may result in non-healing. A patient suffering from an acute periapical abscess may experience severe pain. The pain is due to inflammation in the pulp canal, and/or periapical tissues. The pressure, and therefore the pain, is relieved during the first step of endodontics when the pulp canal is opened. Once the pulp canal is opened, broaches can be used to remove intact pulp tissue from the canal. The canal is then irrigated, and debrided with files and reamers. Dry the canal and place small medicated cotton pellets into the pulp chamber to help clear up the infection. Then, the dentist may place a temporary restoration.

During a second appointment, if necessary, the temporary restoration is removed, the canals irrigated, and root canal reamers and files are used to enlarge, shape, and smooth the pulp canal. If infection continues to be a problem, placement of medication into the canal, and placing a temporary restoration will be required. Schedule the patient for another appointment. When all instrumentation is complete and infection is eliminated, gutta-percha is placed into the canals with a sealer that acts as a cement. Then a temporary restoration can be placed.

After root canal treatment is completed, a permanent restoration is placed, usually at a later appointment. At this time, the tooth may be evaluated for possible prosthodontics treatment to replace the restoration with an artificial crown.

During all appointments, use a rubber dam to isolate the tooth, prevent contamination of the root canal, and prevent the small endodontic instruments from going down the patient's throat.

## ENDODONTIC MATERIALS

The main materials used in root canal therapy are various liquid antiseptics, paste, paper points, gutta-percha points, and sealers. The dentist uses these to treat and fill a properly prepared root canal from which the pulp has been removed.

### Paper Points

Paper points are primarily used during the treatment phase of endodontics to dry out root canals. They are highly absorbent, rolled sterile paper that are long and narrow with a tapered point to fit into the root canal. Paper points are available in assorted sizes, from coarse to X-fine, depending on the size of the canal into which they are being inserted.

### Root Canal Restorative Materials

Root canal restorative materials are used to fill the previously prepared root canals and complete the root canal or endodontic therapy. Root canal restorative materials consist of tapered gutta-percha points in a variety of sizes and root canal sealers or cements. A good root canal restorative material should be insoluble in tissue fluids, opaque to the passage of X-rays, easy to remove, nonirritating to periapical tissues, nonabsorbent, and dimensionally stable after its insertion into a root canal.

**GUTTA-PERCHA.**—Gutta-percha is used as a temporary restoration and as a root canal restorative material. Gutta-percha is the refined, coagulated, milky exudate of certain trees. It is pink or gray in color, softens when heated, and is easily molded. When it is cool, it maintains its shape well. Gutta-percha points have been a choice for root canal restorative materials for many years. The many advantages of the material are as follows:

- High thermal expansion
- Will not shrink unless used with a solvent
- Radiopaque
- Can be kept sterile in an antiseptic solution
- Resistant to moisture and bacteriostatic
- A poor heat conductor

The disadvantages of gutta-percha are as follows:

- Shrinks when used with a solvent
- Is not always easily inserted into the root canal

Gutta-percha points are prepared for insertion by disinfecting them in sodium hypochlorite. They are then air dried, condensed, compacted and inserted into the root canal after the canal walls are coated with sealer.

**TEMPORARY FILLINGS.**—Temporary filling is a temporary restorative material used to seal the access cavity in the tooth between appointments. It may be a commercially available material packaged in a tube, or an intermediate restorative material such as ZOE.

**ROOT CANAL SEALERS.**—The root canal sealers most commonly used in dentistry are packaged in cement and paste form. The zinc oxide and eugenol type is the cement most often used. The liquid eugenol, and a typical zinc oxide powder formula may contain several ingredients as follows:

- Zinc oxide-main ingredient
- Resins-vegetable or mineral oil types
- Anhydrous sodium borate
- Bismuth subcarbonate or subnitrate

Besides the main ingredients, some formulas contain silver particles or barium sulfate, which add radiopaque (ability to stop radiant energy such as X-rays) qualities. These ingredients are mixed in much the same way as in zinc phosphate cement. Using a sterile glass slab and noncorroding spatula, incorporate the powder into the liquid until a thick, creamy consistency is reached.

## **INSTRUMENTS AND ACCESSORIES**

Endodontic instruments and accessories often are prepared in sterile packs or kits. A basic instrument setup can be established for endodontic procedures. The standardized setup can be used during each phase of treatment and supplemented with items needed for a specific phase of treatment. Items that make up a rubber dam setup must be included since the rubber dam is essential to provide isolation and maintain a sterile field. Figure 7-2 illustrates a typical instrument endodontic tray setup. Small endodontic instruments and supplies are generally placed in a metal compartmentalized box that can be sterilized and maintained in an orderly fashion. Figure 7-3 identifies such an example and figure 7-4 list the contents. A variety of accessory items, such as instruments, filling materials, irrigation solutions, cements, and medications used in the endodontic treatment must be readily available during the procedure.

## **Endodontic Explorers**

Endodontic explorers (fig. 7-5) have long, narrow working ends. These explorers are angled from their shank in such a way that they provide easy access to the pulp canal. They are used to locate canal openings and explore the pulp chambers and canals.

## **Endodontic Cotton Forceps**

These instruments resemble the cotton forceps. The major difference is that the endodontic cotton forceps are grooved to allow easy grasping and manipulation of paper points and gutta-percha. They are also available in locking or nonlocking design.

## **Endodontic Excavators**

These instruments are long, double-ended spoon excavators designed for endodontic treatments. They allow the removal of coronal pulp tissue, caries, or cotton pellets that may be deep in the tooth's crown

## **Broaches**

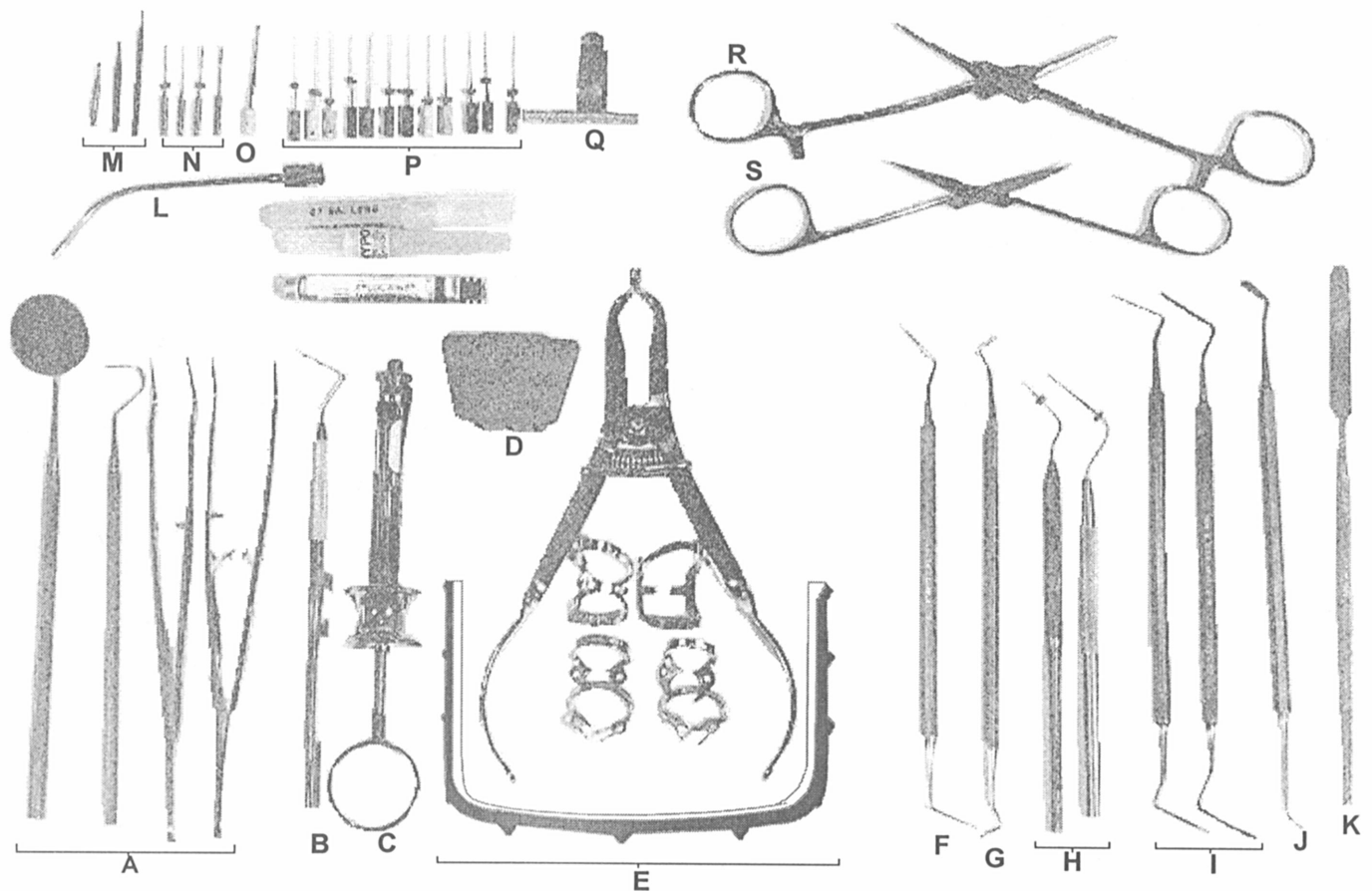
A root canal broach (fig. 7-6) is usually one of the first instruments used in the pulp canal during endodontic treatment. Broaches are thin, flexible, usually tapered and pointed, smooth or with a series of sharply pointed barbed projections curving backward and obliquely. The identification symbol of barbed broaches is an eight-pointed star formed by the barbs.

Smooth broaches can be used as explorers to get the feel of the canal. A barbed broach is used primarily for the removal of intact pulp tissue from large canals. The broach is introduced slowly into the root canal until gentle contact with the canal walls is made. It is rotated 360 degrees in either a clockwise or counterclockwise manner to entangle the pulpal tissue in the protruding barbs. It is then withdrawn directly from the root canal. If successful, the entire pulp comes with it. Because these instruments are fragile and prone to breakage, exercise great care in their use. There are several sizes: coarse, medium, fine, X-fine, XX-fine and XXX-fine. Discard each broach after each use.

## **Reamers**

Root canal reamers (fig. 7-7) are used to enlarge the pulp canal after broaches have been used. Reamers may be used with a reaming action (rotary cutting) or a filing action (scraping or pulling stroke). Reamers are





- A.** MOUTH MIRROR, EXPLORER, COTTON FORCEPS, LOCKING COTTON FORCEPS
- B.** PERIODONTAL PROBE
- C.** ANESTHETIC SYRINGE, CARPULE AND NEEDLES
- D.** MOUTH PROP
- E.** PLASTIC TYPE RUBBER DAM FRAME, FORCEPS AND CLAMPS

- F.** ENDODONTIC EXPLORER
- G.** SPOON EXCAVATOR
- H.** CANAL SPREADERS
- I.** CANAL CONDENSERS (PLUGGERS)
- J.** WOODSON, #2
- K.** SPATULA
- L.** SUCTION TIP

- M.** BURS
- N.** GATES-GLIDDEN DRILLS
- O.** BROACH
- P.** K-FILES
- Q.** ENDO RULER
- R.** HEMOSTAT
- S.** IRIS SCISSORS

Figure 7-2.—Typical endodontic instrument tray setup.


usually tapered and pointed, with spiral cutting edges. Since the cutting edges of reamers are farther apart than those found on files, reamers are more flexible than files. This same distance between the cutting edges causes reamers to cut slower than files. Reamers can also be used to remove old, softened gutta-percha filling, or as a paste carrier to place cement near the apex.

Reamers are available in many sizes beginning with size 10 and continuing in intervals of 5 to size 60. Beginning with size 60, they are also available in intervals of 10 through size 140. The dentist may use several reamers in one operation, usually beginning

with a relatively small size, then the next larger size each time the canal has been reamed to the desired diameter.

### Files

Root canal files normally are used after the broaches and reamers. The root canal files look much like those of the reamers. However, the file threads or cutting edges are much finer and closer together. Files come in two different types (H and K types) and are different in terms of physical properties, such as flexibility, resistance to fracture in rotation, and method of manufacture. The designation of "K-type"



**Figure 7-3.—Typical endodontic box kit with supplies.**

or "H-type" is a generic classification based on a manufacturing process and does not apply to any single design or line of instruments.

Numerical size designations and color coding are the same for both file types. Sizes begin with size 8 and continue through size 140. Files come in different lengths, including 19 mm, 21 mm, 25 mm, and 31 mm.

**K-Type.**—The K-type is tapered and pointed, with tight spiral cutting edges arranged so that the cutting occurs on either a pushing or pulling stroke. They are used to enlarge the root canal by a rotary cutting or abrasive action. When pulling the instrument out of the tooth, the cutting edges scrape against the wall, gouging and removing dentin in a filing action. When the instrument is turned in a

MEDIUM BROACHES	SILICONE STOPS
COARSE BROACHES	LENTULO SPIRALS
#8 FILES	#35 GUTTA PERCHA
#10 FILES	#40 GUTTA PERCHA
#15 FILES	#45 GUTTA PERCHA
#20 FILES	#50 GUTTA PERCHA
#25 FILES	#55 GUTTA PERCHA
#30 FILES	#60 GUTTA PERCHA
#35 FILES	#70 GUTTA PERCHA
#40 FILES	#2 ROUND BURS
#45 FILES	#2 GATES DRILLS
#50 FILES	#3 GATES DRILLS
#55 FILES	#4 GATES DRILLS
#60 FILES	#5 GATES DRILLS
#70 FILES	X-FINE BROACH

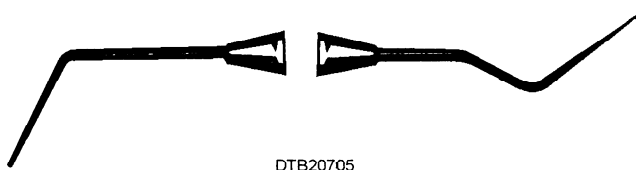
#25 GUTTA PERCHA	#30 GUTTA PERCHA
#30 GUTTA PERCHA	COTTON PLIERS

#### INVENTORY LEVELS

SILICONE STOPS	50	#2 LONG SHANK ROUND BURS	10
#25 GUTTA-PERCHA POINTS	50	#2,3,4&5 GATES-GLIDDEN DRILLS	10
#30 GUTTA-PERCHA POINTS	100	BROACHES (X-FINE,MEDIUM&COARSE)	10 EACH
#35 GUTTA-PERCHA POINTS	50 EACH	FILES: #S 8-70	10 EACH

DTB20704

Figure 7-4.—Items and inventory levels of endodontic box kits.

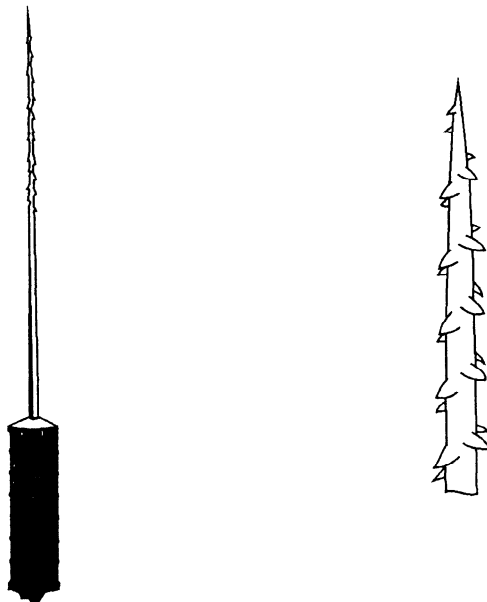


DTB20705

Figure 7-5.—Endodontic explorers.


clockwise, rotary action, the cutting edges scrape the wall and widen the preparation in a reaming action. K-type root canal files (fig. 7-8) are, size for size, stiffer and stronger than comparable types of files. The identification symbol for K-type files is a square.

**H-Type.**—The H-type are tapered and pointed, with spiral cutting edges arranged so that cutting occurs principally on the pulling stroke. These files also know as "Hedstrom" (fig. 7-9) are used to enlarge the root canal by either a cutting or an abrasive action. The series of intersecting cones forming the file become successively larger from the tip toward the handle. The sharp blades of the H-type files cut more quickly than reamers or K-files. The H-type files are frequently used for flaring of the canal from the apical region to the occlusal or incisal opening. The identification symbol for H-type files is a circle.



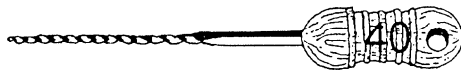DTB20706

Figure 7-6.—Root canal broach with enlarged view.




DTB20707

Figure 7-7.—Reamer with enlarged view.



DTB20708

Figure 7-8.—K-type file with enlarged view.

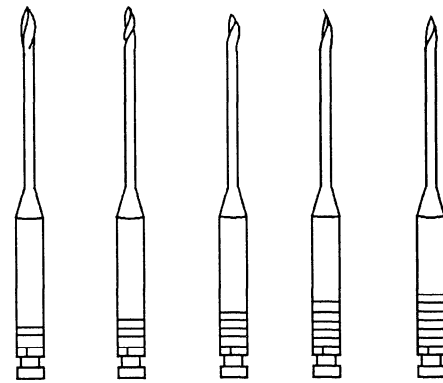


DTB20709

Figure 7-9.—H-type file with enlarged view.

### Gates-Glidden Drills

Gates-Glidden drills (fig. 7-10) are designed to enlarge the root canal. They are designed with long



DTB20710

Figure 7-10.—Gates-Glidden drills.

flame-shaped shanks. As a rotary cutting instrument, they can be used with a slow-speed contra-angle and with friction-grip straight handpieces. The number of bands at the base of the drill indicates the size of the drill. Their sizes are numbered 1-6. Size #1 is fragile and therefore rarely used to avoid the possibility of breaking off inside the canal.

### Lentulo Spiral

The lentulo spiral (fig. 7-11) is designed to transport cement or paste to the finished root canal before the placement of the gutta-percha master cone. It is used with a latch-type handpiece and is small and flexible in design.

### Endodontic Condensers

There are two types of endodontic condensers. The first type is referred to as a **plugger** or **vertical condenser**. The working end is contra-angled, and cylinder-shaped with a flat tip designed to condense root canal filling materials vertically into prepared root canals. The plugger shown in figure 7-12, has serrations at 5-mm intervals to evaluate penetration depth.



DTB20711

Figure 7-11.—Lentulo spiral.



DTB20712

Figure 7-12.—Root canal plugger or vertical condenser.

The second type of endodontic condenser is called a **spreader**. The root canal spreader (fig. 7-13) has a contra-angled working end that tapers to a point (compared to the flat tip of a plugger). This instrument is single ended. Spreaders are designed to condense root canal filling materials horizontally against the wall of the prepared root canal.

Finger spreaders and finger pluggers have a handle like a file and a smooth working end like a spreader or plugger. The finger spreader has a pointed end, the finger plugger has a flat end.

### Endodontic Measuring Gauges

Precise measurements of the length of a root canal are vital to the success of root canal therapy. The dentist uses a measuring gauge to measure the working length of files, reamers, and broaches. Two styles of measuring gauges are commonly used. The first type is shown in figure 7-14. The finger or thumb ruler is the other type used. The exact working distance can be set on the bar and is confirmed when the end of the instrument reaches the metal plate. The example in fig. 7-14 shows the working distance of a file set at 21 mm.

### Stops

Stops (fig. 7-15) are small, round or square pieces of rubber, plastic, or silicone placed on the files, reamers, or broaches to mark the length of the canal. This prevents injury to the apex of the root and periapical tissues.

### ANESTHESIA AND PAIN CONTROL

A local anesthetic must be administered by the dentist before endodontic therapy if the tooth is vital. If

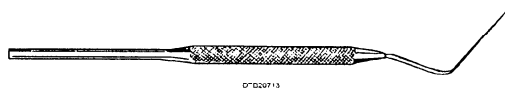


Figure 7-13.—Root canal spreader.

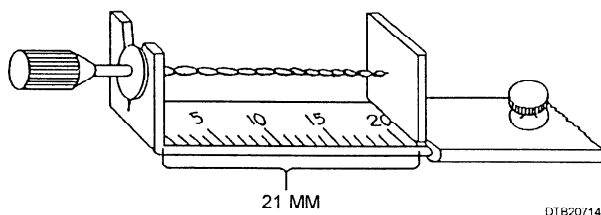
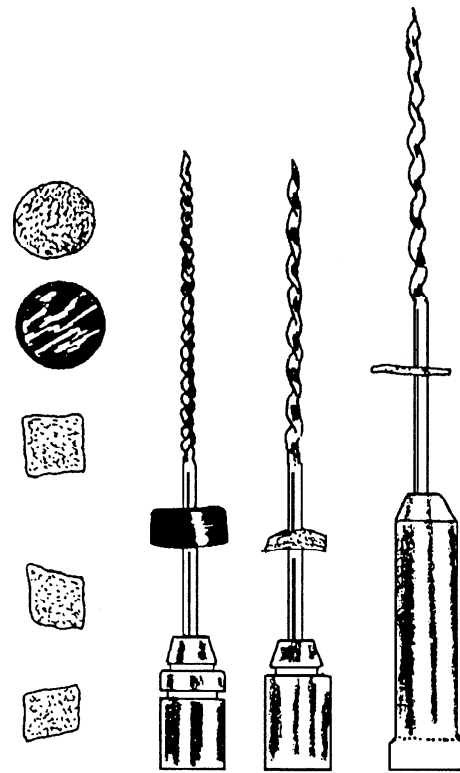


Figure 7-14.—Measuring gauge.



DTB20715

Figure 7-15.—Stop attachments.

the tooth is hypersensitive, it may require injection of additional solution directly into the pulp. When a tooth is nonvital, the use of local anesthetic solution is not mandatory. At subsequent visits, after the pulp has been removed, local anesthesia may not be necessary. The dentist may give the patient a prescription for medication to control any anticipated postoperative discomfort or infection.

### ISOLATION

Endodontic therapy involving the removal of the pulp and sealing the empty canal requires debridement, irrigation, and sterilization of the pulp chamber and canals as part of the procedure. These steps of the procedure are necessary to ensure against future infection by eliminating bacteria before the canal is sealed. An absolutely dry field, free from bacteria-laden saliva is required to achieve such sanitation of a root canal. Additionally, the rubber dam prevents patients from swallowing or aspirating the very small instruments used in endodontic treatment. This dry field is maintained best with a rubber dam isolation. The rubber darn usually is prepared to expose only the tooth to be treated endodontically, thereby providing isolation of the tooth with the rubber dam. A radiolucent rubber dam frame made of plastic is

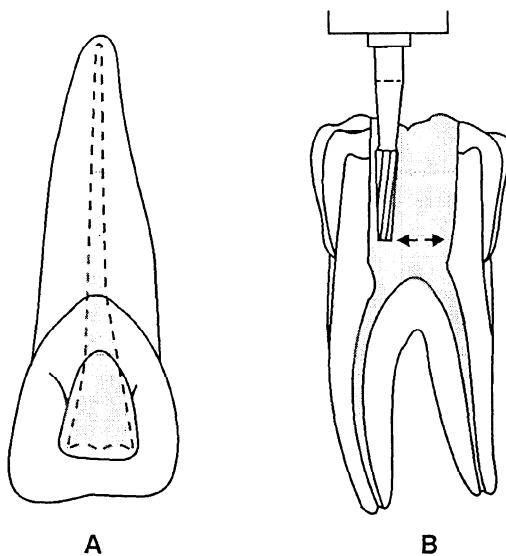
commonly used and saves valuable time when exposing radiographs. Metal rubber dam frames must be taken off while exposing radiographs. Remember a risk of contamination can occur while the frame is off.

## OPENING THE PULP CHAMBER AND CANALS

After the tooth is isolated, the dentist makes an opening through the crown of the tooth to gain access to the pulp chamber and canal. The opening is made through the lingual surface on anterior teeth (fig. 7-16, A) and through the occlusal surface on posterior teeth (fig. 7-16, B). Friction-grip and latch-type burs or diamond stones are used to create the endodontic opening. Sizes vary according to the preference of the dentist and the size of the chamber and canals of the tooth.

## REMOVING THE PULP

After the endodontic opening is made, the dentist will locate the root canals and remove the pulp. Anterior teeth usually have one root canal, but often lower incisors will have two canals. Posterior teeth may have up to four canals of different sizes. Anatomical variations exist among patients; therefore, additional canals may be found. A thin, straight explorer can be used as a probe to locate canal openings within the pulp chamber. The larger pulp canals are easier to locate; whereas, smaller canals are sometimes difficult to locate.



DTB20716

Figure 7-16.—Access to pulp chamber and canal: A. Anterior teeth; B. Posterior teeth.

Once the canals are located, the pulp tissue must be removed. If the pulp tissue is still intact, the thin, flexible, barbed broach is used to remove it. Broaches are considered disposable and should be discarded after one use, since they are subject to fracture after repeated sterilization. If the pulp tissue has disintegrated, it is simply removed when the canal is cleaned and filled.

## IRRIGATION

After the root canals are accessed and the pulp tissue is removed, the root canals are cleaned with an irrigating solution. Irrigation and evacuation are essential parts of endodontic treatment because they assist in the removal of pupal remnants and tissue fluids. The irrigation solution also serves as a lubricant in the instrumentation and enlargement of the canal walls.

The most frequently used solution for irrigation of the root canal is **sodium hypochlorite** or common household bleach. This solution is a solvent for necrotic tissue, in effective disinfectant to destroy bacteria in the canal, and acts as a bleaching agent. Sodium hypochlorite may be used full strength or diluted with 1 to 2 parts water to reduce the chlorine odor.

A sterile, disposable, plastic Luer lock-type syringe (5 cc to 10 cc sizes) with a disposable, blunt 20 to 27 gauge needle is the common instrument used to inject the irrigating solution into the canals. The needle may be bent at an angle to provide access to the canal.

The irrigating solution is injected slowly and gently into the canal to prevent the solution from being forced into the periapical tissue. A small root canal file or reamer can then be placed into the canal and rubbed against the pulp canal walls to produce a scrubbing effect that loosens debris and bacteria. The solution is removed with a suction tip on the oral evacuator. Any remaining solution may be absorbed by placing sterile cotton pellets and paper point into the canal. There are numerous times during endodontic treatment in which you will be required to provide thorough irrigation of the pulp chamber and canals. The following are the most common:

- Before the use of intracanal instruments once the root canal is accessed and the pulp tissue is removed.

- Before the instrumentation of a previously opened pulp cavity to remove food particles and saliva.
- At intervals during instrumentation, often after each size file is used.
- At the completion of canal instrumentation, before placement of medication.
- When using root canal preparation type.

## CANAL CLEANSING AND SHAPING

Canal cleansing and shaping is the progressive elimination of organic and inorganic debris within the root canal by mechanical instruments. As part of the cleansing process, the canals are enlarged and shaped with **endodontic files and reamers**. Filing shapes the walls of the root canal so that they are smooth with specific size and shape.

The filing procedure begins by first establishing the approximate or estimated **length** of the root canal. Accurately determining the length of the tooth is vital to successful endodontic treatment. Failure to determine an accurate length may lead to apical perforation and overextension, with increased postoperative pain or incomplete instrumentation and underfilling.

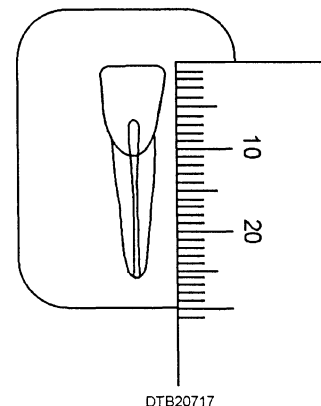
The estimated length is determined from an accurate, preoperative periapical radiograph of the tooth being treated. Multirooted teeth may require radiographs from various horizontal angulations to determine the exact number and alignment of each root. The length of the tooth is measured using either an endodontic millimeter ruler (fig. 7-17) or a file held near the radiograph from a reference point on the crown portion of the tooth to the apex. Good reference points are the incisal edges of anterior teeth and cusps on posterior teeth. Files are measured on a millimeter ruler and marked accordingly with the placement of rubber stops. The estimated working length is recorded in the patient record for future reference and modification. If necessary, a more accurate length is established as the filing process continues. The working length is verified by exposing and measuring a periapical radiograph with a reamer or file in the canal. Once the tooth length is established, you will use an endodontic gauge to adjust the position of the rubber stops on the appropriate sizes of reamers and the files the dentist selects. It is important that the rubber stops be placed at a right angle to the long axis of the instrument and not an oblique angle. When the file is inserted into the root canal, the rubber stop

touches the reference point on the crown when the tip of the file is at the apex of the root. With the stops in place, arrange the reamers and files in order of their use. As the filing progresses, the file sizes are increased to enlarge the size of the canal. When teeth with more than one canal are filed, it is essential that each canal be filed to a predetermined length. Occasionally, an electronic apex locator may be used to help verify the working length. Each canal can be filed to different diameters, as well as, different lengths.

During the filing, the root canal is irrigated with solution to keep the dentin shavings from the canal walls from clogging the cutting edges of the file. After the filing is complete, the canal is thoroughly flushed simultaneously with irrigating solution and suction. The canal is dried with paper points held in locking forceps and inserted into the canal to absorb the solution. This is repeated with several paper points until the paper points are completely dry when withdrawn.

## MEDICATIONS

After the root canal is dried with paper points, medications are occasionally placed in the canal between appointments to aid in the control of microbial activity within the tooth. A small cotton pellet is moistened with medication and blotted dry with a cotton roll or gauze. The small dry medicated cotton pellet is placed on the floor of the pulp chamber (fig. 7-18) over the opening on the canal and covered with a larger, dry cotton pellet. More often, only a dry cotton pellet with no medication is placed, or a paste of calcium hydroxide is placed into the canals before the dry cotton pellet is placed. A temporary filling must be placed over the larger cotton pellet to prevent contaminating the root canal with saliva and food



DTB20717

**Figure 7-17.—Estimated working distance using an endodontic millimeter ruler.**

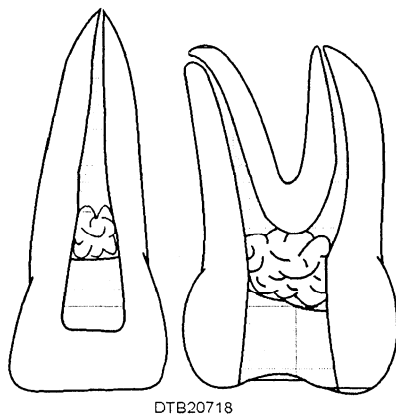


Figure 7-18.—Placement of dry medicated cotton pellet.

debris between appointments. Amalgam, zinc oxide and eugenol (ZOE), or a commercially ready-made cement may be used for this purpose.

### ROOT CANAL FILLING

If a medicated cotton pellet or temporary filling materials have been placed, these items must be removed and the canals irrigated and dried with paper points before proceeding to fill the root canal. Gutta-percha points or cones, available in various sizes are the most common filling material for a prepared root canal.

An appropriate sized gutta-percha point is selected and may be shortened slightly to blunt the tip. The point is placed into the canal to a depth where the point seems snug when gently tugged. This point is referred to as the **master cone**. A radiograph with either the apical tile, or master cone point in place is exposed to verify the proper length. The tip of the master cone should provide an adequate seal of the apical foramen. This radiograph often is referred to as a master cone radiograph. If adjustments are needed to achieve the proper length of the master cone, additional radiographs may be exposed to verify the proper length. A properly fitted master cone also allows space between the point and the walls of the prepared canal. Before the master cone is removed, a slight mark is placed on the point at the line where it is even with the opening of the tooth by squeezing the cotton forceps on the gutta-percha. The master cone is now ready for cementing.

Mix the cement according to the manufacturer's instructions. The master cone is removed and a paper point is placed in the canal to absorb moisture that may accumulate. The consistency of the cement should be creamy but quite heavy. The dentist may choose to dip

a lentulo spiral or reamer into the cement mix, insert it approximately halfway into the canal, and rotate it to distribute the cement onto the dry walls of the canal. With the master cone placed into the cotton pliers, the apical third of the cone is coated with cement. The cone is then inserted into the canal and seated to the mark made on the cone.

The space between the cemented master cone and the walls of either the root canal or pulp chamber is filled with additional gutta-percha points (accessory cones) of smaller diameter alongside the master cone. Filling the canal with additional gutta-percha points is done by inserting an endodontic spreader beside the master cone and applying lateral pressure to condense the cone against the walls of the canal. As the spreader is removed from the canal, a smaller additional gutta-percha point is inserted in the space. The process of lateral condensation and addition of gutta-percha points continues until the canal is filled completely. Figure 7-19 illustrates the steps in filling a root canal with the master and accessory cones.

The excess length of gutta-percha is removed with a heated instrument. An endodontic plugger, also known as a vertical condenser, is used to condense the still warm gutta-percha vertically toward the apex of the tooth. More gutta-percha can be added if needed, and the process of vertical condensation continued until the canal is filled completely.

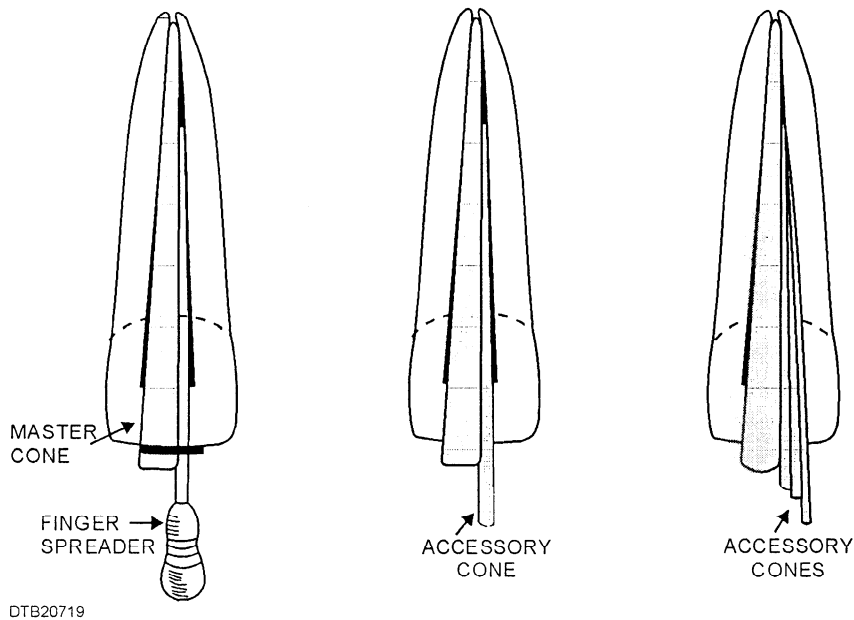
When a tooth has more than one root canal, each canal is filled individually and each requires a properly fitted gutta-percha point sealing in it. A perfect sealing of the apical foramen in the roots of the teeth is essential to eliminate irritation of periapical tissue. Any excess gutta-percha and cement are removed from the pulp chamber and the chamber then sealed with a temporary restoration.

Amalgam or composite materials may be placed to fill the canal opening and restore the tooth permanently (fig. 7-20). Teeth successfully treated endodontically may also be restored with prosthodontics treatment, such as onlays and artificial crowns. As a rule, follow-up appointments are scheduled periodically for radiographs of the restored tooth. The dentist uses the post-treatment radiograph as an aid to determine the elimination of infection and progress of bone regeneration.

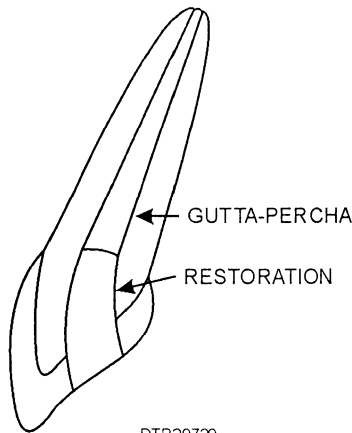
### STEPS IN APICOECTOMY (ROOT END RESECTION)

The apicoectomy (root end resection) requires teamwork between the dentist and his/her assistants.



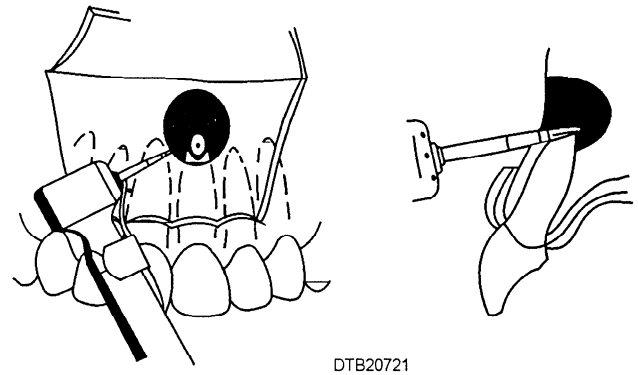


DTB20719  
**Figure 7-19.—Steps in filling a root canal with master and accessory cones.**



DTB20720  
**Figure 7-20.—Permanent restoration in place on completed root canal.**

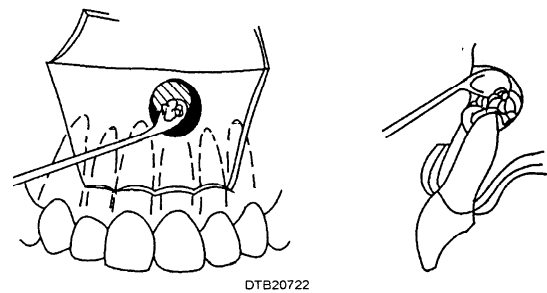
Along with the apicoectomy, the dentist usually performs a periapical curettage and may place a retrograde filling. After the patient has been draped and anesthetized, the dentist makes a surgical incision on the facial aspect of the alveolar ridge and a mucoperiosteal flap is elevated to expose the apex of the tooth to be treated. The assistant aids in retraction of the mucoperiosteal flap with the periosteal elevator and provides suction. This reveals the cortical bone of the alveolus covering the apex of the tooth. The dentist then uses a handpiece and surgical bur to remove the cortical plate covering the apex of the tooth. Once the root is exposed, the dentist uses the bur to remove the apex as shown in figure 7-21. The assistant irrigates with a saline solution and aspirates as needed. The dentist uses a curette to curettage the surrounding



DTB20721  
**Figure 7-21.—Removing apex of tooth.**

periapical tissue, thus removing infectious material from around the root tip. Figure 7-22 illustrates the curettage procedure. If access to the canal is obstructed from the occlusal or lingual aspect, debridement and filling can now be done from the apex.

If indicated, a retrograde filling may be performed to seal the apical end of the root canal by placing a



DTB20722  
**Figure 7-22.—Apical curettage procedure.**

restoration in the root apex. The dentist may use an ultrasonic or a high-speed handpiece with a bur to prepare the blunted apex for the filling. When the preparation is complete, the surgical site is irrigated carefully with saline solution and aspirated until it is dried thoroughly. Hemostatic agents such as bovine collagen or ferric sulfate may be placed to control bleeding and to catch scraps during the placement and condensation of the root end filling material. Intermediate restorative material such as ZOE, or super EBA cement (ethoxybenzoic acid) is mixed and placed into the recessed preparation of the root apex. The retrograde filling is condensed and smoothed even with the tip of the amputated root surface. The

hemostatic agents are carefully removed to avoid dropping scraps or cement into the incision. The site may be irrigated and aspirated again.

A radiograph is exposed to determine the absence of any filling particles in the tissue at the surgical site. When it is determined that the filling is satisfactory and that all particles of the filling material are removed, sutures are placed to close the incision. The surgical portion of the apicoectomy is done quickly. The longer the patient is subjected to a surgical procedure, the more likely it is that there will be swelling and discomfort. Follow-up appointments usually are scheduled periodically for radiographs of the restored tooth.

## CHAPTER 8

# PROSTHODONTIC ASSISTANCE

To be an effective prosthodontic assistant, you need to be familiar with the following general information and basic skills. Your duties will include some of the following:

- Assisting the dentist in prosthodontic procedures
- Setting up prosthodontic instrument trays
- Preparing material for prosthodontic procedures
- Making diagnostic impressions and casts
- Trimming dental casts
- Fabricating mouth and bite guards and custom trays
- Performing simple acrylic repairs

A prosthodontist is a dentist with specialized training in replacing missing teeth; however, many general dentists in your clinic will be able to provide prosthodontic care. Your prosthodontic assisting duties are very similar to those in other specialties. The primary differences are the types of treatment the dentist performs, the material you mix or manipulate, the instruments the dentist uses, and the coordination required with the dental laboratory personnel.

Prosthodontic dentistry deals with the substitution or replacement of oral structures. Prosthodontic dentistry can include anything from replacing one missing tooth to constructing a complex—designed device to replace structures of the face such as eyes, ears, or a cleft palate. Prosthodontic treatment is concerned primarily with replacing missing teeth with some type of artificial substitute. Substitutes for natural teeth are called prosthodontic prostheses. Prosthodontic prostheses are either fixed permanently into the patient's mouth or removable.

### TYPES OF FIXED PROSTHETICS

A fixed prosthesis is any variety of replacements for a missing tooth or part of a tooth that a dentist cements in place and the patient cannot remove. Restorations, such as inlays, onlays, crowns, and fixed partial dentures fall into this category. A fixed prosthesis may be constructed entirely from a cast metal alloy, acrylic resin, or porcelain. Frequently, a fixed prosthesis is made of a combination of these

materials. For example, a complete crown may have a metal substructure and a porcelain veneer (facing).

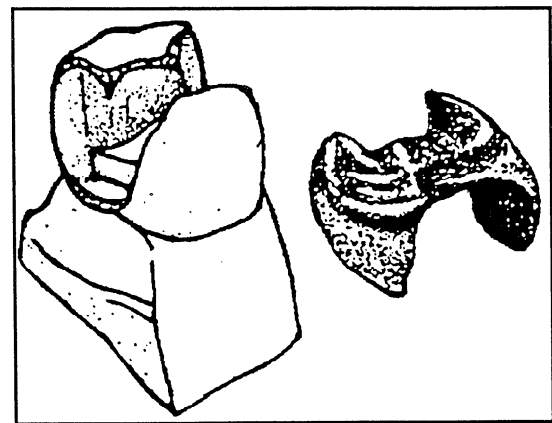
### INLAY

An inlay is a dental restoration that fits into a prepared cavity, and is held there by its precision fit and a cementing medium. Inlays are, for the most part, surrounded by intact tooth structures. For this reason, they are often called *intracoronal* restorations. The various forms of inlays are used primarily to restore individual tooth contours and function. In the majority of cases, an inlay is not a suitable anchor casting (retainer) for a fixed partial denture. Inlays are usually cast in medium hard gold, but can be made of other materials (porcelain, resin).

There are five classes of inlays (class I, II, III, IV, and V) based on the location of the surfaces being restored. A more specific way of naming an inlay is to cite the tooth surfaces it restores; for example, MO (mesio-occlusal) inlay, or a MOD (mesio-occlusal-distal) inlay as shown in figure 8-1.

### ONLAYS

Onlays are cast gold, resin, or porcelain restorations that ordinarily cover the mesial, occlusal, and distal surfaces (MOD) of posterior teeth. Onlays differ from inlays in that an onlay covers the entire occlusal surface of a tooth to include the cusps. An onlay is the smallest of the fixed prosthetic restorations



DTB20801

Figure 8-1.—MOD inlay.

classified as an *extracoronal*. An intracoronal replacement like an inlay fits into a tooth. An extracoronal restoration fits around what remains of a tooth.

## ARTIFICIAL CROWNS

An artificial crown is a fixed prosthetic restoration that covers more than half of the coronal portions of the tooth. There are several types of crowns. They may be made of gold, porcelain, acrylic, or a combination of these materials. Along with onlays, which are classified as extracoronal restorations, are the various kinds of crowns that make up the balance of the extracoronal category.

### Partial Crown

A partial crown is a cast restoration made entirely from metal and covers more than half but not all of the tooth's clinical crown. A partial crown is named according to the fractional amount of the clinical crown it covers. Examples are the half, three-quarters (see fig. 8-2(A)), four-fifths, and seven-eighths crowns (see fig. 8-2 (B)). In most instances, the facial surface of the tooth is not disturbed for esthetic reasons.

### Complete Crown

A complete crown covers the entire anatomy of a tooth's clinical crown. There are several types of complete crowns. A complete metal crown is constructed entirely of a noncorrosive metal, such as gold (see fig. 8-2(C)). A complete veneered crown consists of complete coronal coverage of the tooth with a metal substructure overlaid with porcelain or resin for esthetic effect (see fig. 8-2(D)). A complete crown constructed of cast metal with a fused porcelain (ceramic) veneer is commonly called a PFM (porcelain-fused-to-metal) crown.

A post crown is a complete crown of any kind (complete metal, veneer), supported by a metal extension (post) into a tooth's root canal. Because the pulp is removed from teeth that are endodontically treated, the teeth eventually become brittle and are prone to fracture. In many instances, the teeth are also destroyed by caries or previous restorations and very little clinical crown is left. Often, only the root portion is left to retain the crown. To maintain an endodontically treated tooth as an abutment (anchor) capable of supporting and retaining a crown, it is common practice to cement a post about two-thirds of the way into a root canal. To do this, a gold casting

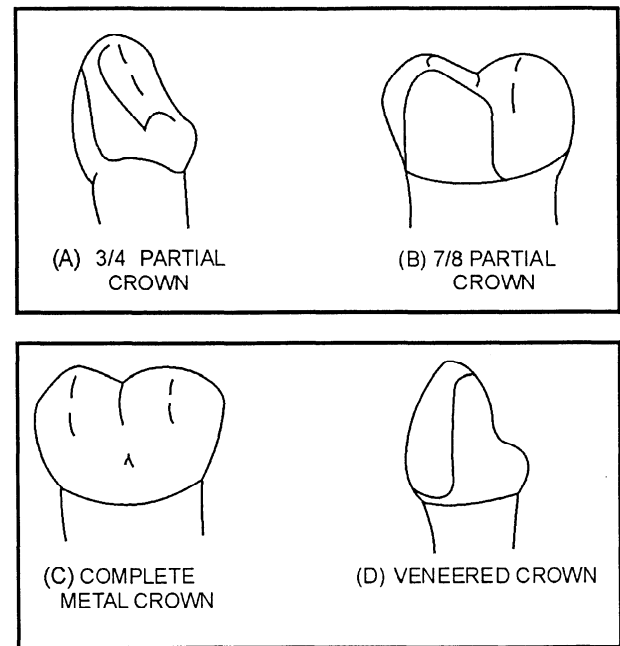


Figure 8-2.—Types of artificial crowns.

called a post and core, must be constructed. The part of the post that protrudes from the root canal is called the core. The core, combined with the remains of the coronal part of the tooth, is built to resemble a complete crown preparation. After the post and core are cemented into the root, a complete crown is fabricated on top of this foundation (fig. 8-3). Post and core castings are most often associated with endodontically treated anterior teeth, but they may also be used on posterior teeth as well (fig. 8-4).

## FIXED PARTIAL DENTURE

A fixed partial denture (FPD) (fig. 8-5) is a restoration designed to replace more than one missing natural tooth. In contrast to a removable partial denture, the dentist attaches an FPD to natural teeth (abutments) or roots by cementation. An FPD consists of two types of units: retainers and pontics. The unit castings are joined together by connectors. The overall size of the FPD is measured in units. Each pontic or retainer counts as one unit. For example, an FPD with three retainers and two pontics has a total of five units. The units of an FPD may be made entirely from metal, combination of metal or resin, or from a combination of metal and porcelain. Next, we will discuss the retainers, pontics, connectors, and abutments that make up the FPD (fig. 8-5).

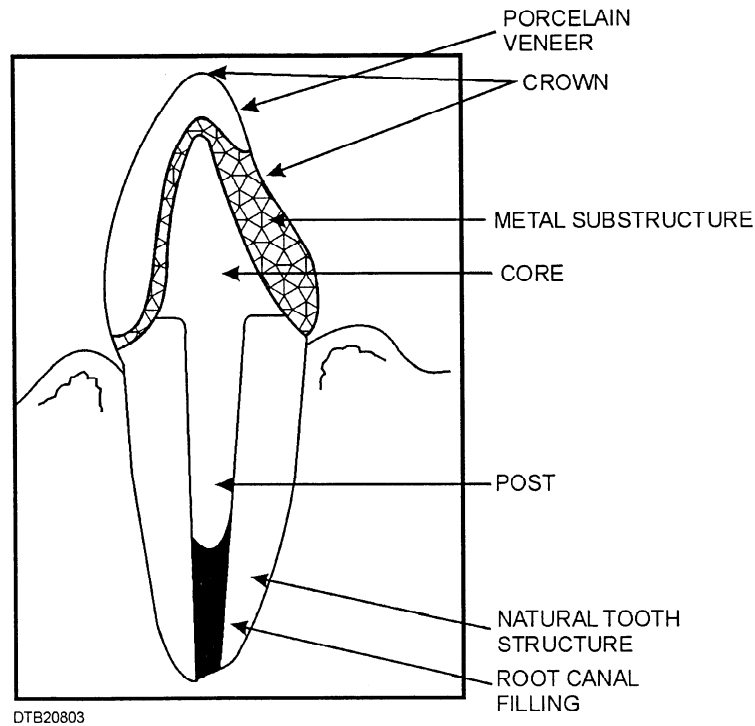


Figure 8-3.—Post and crown.

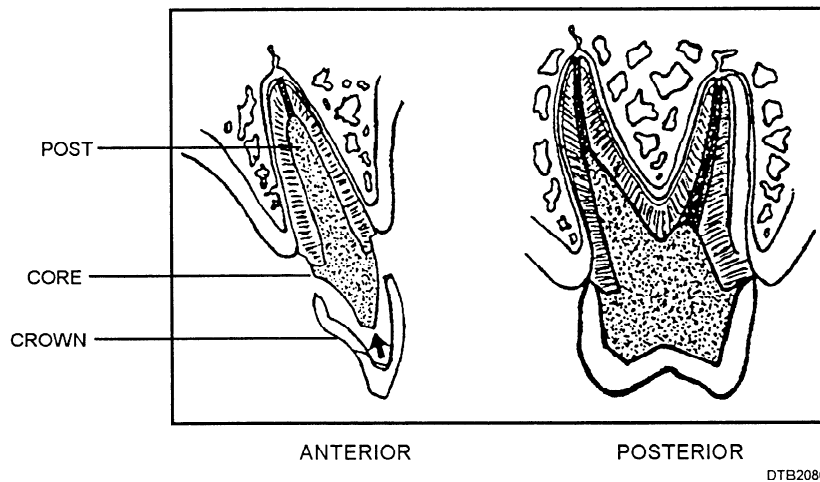


Figure 8-4.—Post and core for anterior and posterior teeth.

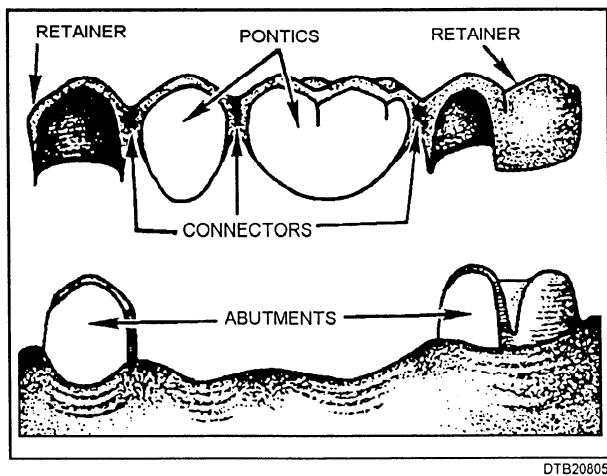


Figure 8-5.—Components of a typical FPD.

### Retainers

Part of the FPD will have metal castings, called *retainers*. They are made to fit onto what the dentist has cut away on the abutment teeth. Retainers also secure and support the FPD's artificial tooth or teeth. The most commonly used retainers are PFMs, complete metal crowns, partial crowns, and onlays.

### Pontics

A pontic is an artificial tooth that is suspended from the retainer casting. A pontic occupies the space formerly filled by the crown of a natural tooth.

## Connectors

A pontic is attached to a retainer by a connector. Connectors can be rigid or nonrigid. Nonrigid connectors take the form of male- and female-locking arrangements. Rigid connectors are classified as either cast or soldered.

## Abutments

The teeth that support and hold the retainer are called abutments. It is almost mandatory that an FPD be supported by an abutment at both ends. This requirement is waived in special situations. When a pontic is suspended from only one retainer, it is *cantilevered*.

## FIXED SPLINTS

A number of teeth can share a load being placed on one of them. This helps prolong the life of loose teeth or those that have lost supporting bone. Stabilizing a mobile tooth or teeth is called *splinting*. When stabilizing adjacent teeth with connected castings that are cemented in the mouth, the prosthesis becomes a form of *fixed splinting*. Such splints are made in the same fashion as an FPD.

## RESIN-BONDED FIXED PARTIAL DENTURES (MARYLAND BRIDGE)

This type of fixed prosthesis is made of a single pontic and thin metal retainers located both proximally and lingually on the abutment teeth. The retainers are specially designed metal-extensions (wings). The FPD is retained by a resin bond between the acid etched abutment teeth and the metal surface of the retainer. A missing left central incisor is illustrated in A of figure 8-6. A fabricated Maryland bridge is illustrated in B of figure 8-6. The bridge in place from the lingual aspect is illustrated in C of figure 8-6. A posterior resin-bonded FPD is shown in figure 8-7.

## INTERIM FIXED PARTIAL DENTURE

This is a rigid, **temporary** restoration that replaces missing teeth and is generally made from a self-cutting resin. Its purpose is to protect cut tooth surfaces and hold the abutment teeth in position while the definitive FPD is being fabricated in the dental laboratory.

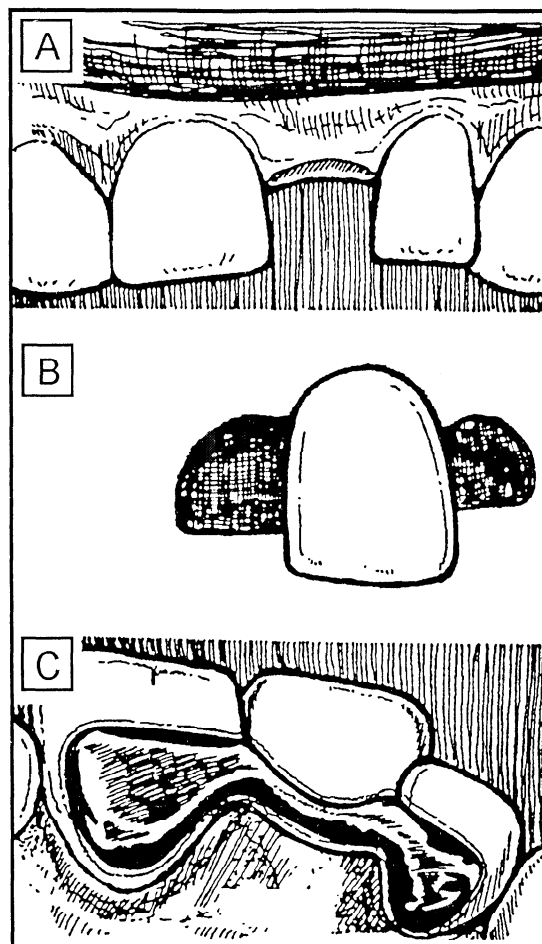


Figure 8-6.—Anterior resin-bonded FPD (Maryland bridge).

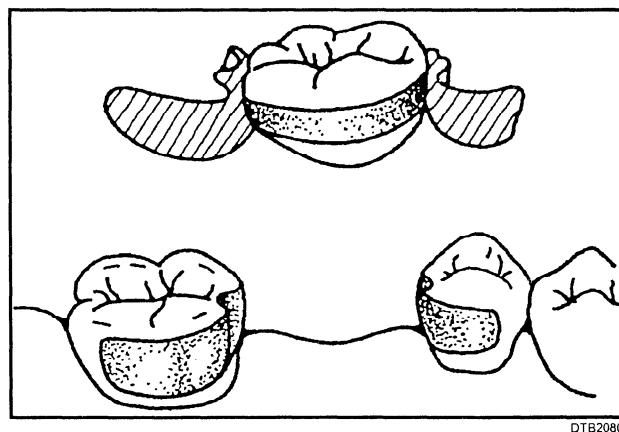


Figure 8-7.—Posterior resin-bonded FPD (Maryland bridge).

## TYPES OF REMOVABLE PROSTHETIC PROSTHESES

The three basic types of removable prosthetic prostheses are complete dentures, removable partial dentures, and overdentures. There are variations of each of these types.

## COMPLETE DENTURES

A *complete denture* (CD) is a type of removable prosthesis designed to replace all of the natural teeth in an arch and associated structures of the maxilla or mandible (fig. 8-8). However, a CD denture does not usually replace third molars.

The CD consists of an acrylic base and porcelain or acrylic artificial teeth. The base is designed to fit over the alveolar ridge, and is composed of the saddle and gingival area. Sometimes, patients need a set of CDs; one for each arch. If a CD is constructed for insertion immediately following the surgical removal of all remaining teeth, it is considered an *immediate complete denture*. Before a conventional prosthesis is fabricated, the extraction sites must be completely healed. Therefore, immediate dentures are often considered temporary or interim prostheses. The immediate denture also functions as a psychological aid to the patient, who will never have to be completely without teeth. Immediate dentures usually require relines 3 to 12 months after initial insertion. This is because of the dramatic reduction in the ridge size during the healing process.

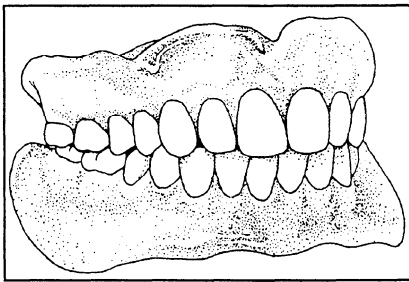


Figure 8-8.—Maxillary and mandibular complete dentures (CDs).

## REMOVABLE PARTIAL DENTURES

A *removable partial denture* (RPD) is a type of removable prosthesis designed to replace one or more missing natural teeth (but not all), gingival tissue, and associated parts of the maxilla or mandible. Figure 8-9 illustrates maxillary and mandibular RPDs.

There are several RPD types, based on the materials used to construct the prosthesis. One type is a **cast metal** RPD. This prosthesis may have a cast metal framework with denture plastic and artificial teeth made of resin, ceramic, or metal attached. A cast metal RPD may also be constructed of all metal in which the entire RPD (frame, denture base, and teeth) are all made from cast metal. The dental laboratory will use a nickel chrome-alloy (ticonium metal) for RPD framework castings.

Another type of RPD is the **resin** RPD made completely of acrylic resin. Sometimes, wrought wire clasps are added to the plastic body of a resin RPD to help retain it in the mouth. The resin RPD is often considered an interim RPD and is intended to be temporary in nature. Resin RPDs are used to replace a metal RPD that is broken, no longer fits, or may be prescribed to patients who lose any anterior teeth from an accident. Resin RPDs are a less expensive, and a temporary substitute for replacing missing natural teeth.

If a partial denture is constructed for insertion immediately following the surgical removal of natural teeth, it is called an *immediate partial denture*. These prostheses are often considered temporary or interim prostheses because they are used for a period of time in between events. Once the extraction sites are

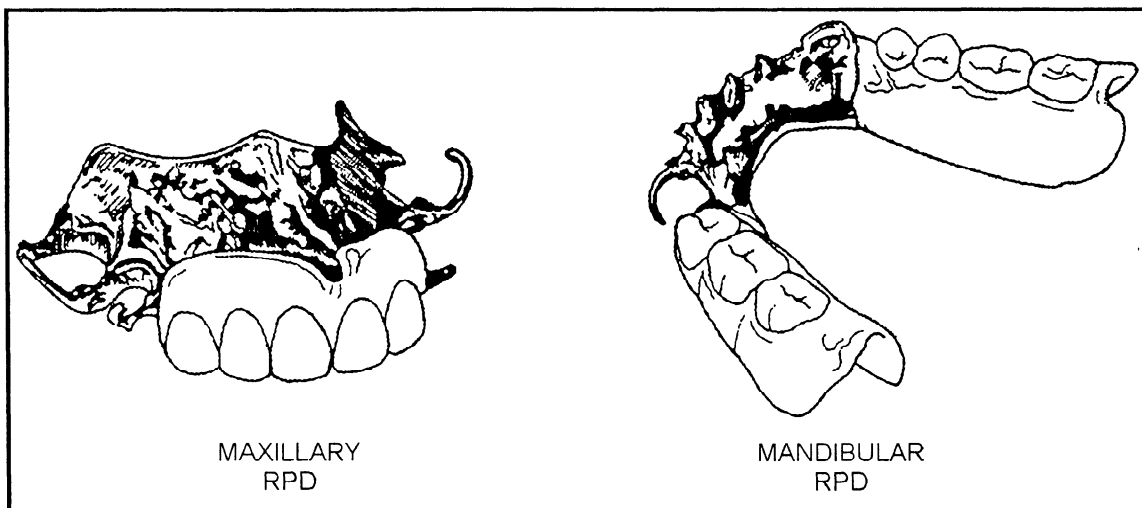


Figure 8-9.—Maxillary and mandibular RPDs.

DTB20809

well-healed, a conventional RPD is constructed. In-mediate partial dentures are usually fabricated completely of a resin base and denture teeth.

## OVERDENTURES

These prostheses include complete, partial, and immediate overdentures. A **complete** overdenture replaces the **entire** dentition and is constructed for insertion over one or more remaining prepared teeth, roots, or dental implants. A **partial** overdenture replaces the **partially missing** dentition and is constructed for insertion over one or more remaining prepared teeth or roots. If the overdenture is constructed for insertion immediately following the surgical removal of natural teeth, leaving no strategic teeth to support the denture, the prosthesis is considered an **immediate** prosthesis.

## PROSTHODONTIC MATERIALS

Many dental materials are unique to prosthodontic procedures. The improper use of any of these materials could cause a delay in the treatment and an inconvenience to the patient. You should be familiar with the use, handling, reaction time, and storing procedures for these materials. This knowledge is necessary for your successful performance as a prosthodontic assistant.

## DENTAL ALLOYS

Although you do not make dental prostheses as a basic dental assistant, you must know enough about the materials used in their construction to document properly the treatment patients receive. When a patient's prosthesis is given to a dental lab for repair or change, they need to know its history to do the work properly, or a tragic result may follow. You should document all laboratory requests and patient dental records with information, such as alloy type used, solder type, and tooth shade if applicable.

Dental alloys can be classified as precious, semiprecious, and nonprecious. For the purpose of training and clarification, we will classify them as **noble metal** or **base metal** alloys.

### Noble Metal Alloys

Noble metals resist oxidation and corrosion. The four noble metals used primarily in dentistry are silver, platinum, palladium, and gold. Gold is very useful for dental put-poses. Although too soft for use alone, it can

be combined with other metals in varying proportions to produce alloys of almost any desired properties. Other noble metals are used in most dental labs to fabricate crowns and FPDs because of the high cost of gold.

### Base Metal Alloys

Since base metal alloys do not contain noble metals, they are much stiffer and harder. Thus, they are useful for constructing RPDs and certain types of FPDs.

## IMPRESSION MATERIALS

Many types of impression materials are used in the dental clinic. However, no one material fulfills all requirements for making a perfect negative reproduction of the oral structures. The dentist will determine which material will best meet the requirements for each case. The two commonly used impression materials are alginate hydrocolloids and synthetic rubbers.

### Alginate Hydrocolloids

Hydrocolloids that change state because of thermal changes are known as *reversible* hydrocolloids because the process can be changed back and forth by altering the temperature. Those that are altered through a chemical change are known as *irreversible* hydrocolloids. Once the chemical change has taken place, it cannot be reversed or turned back to the previous state.

Irreversible hydrocolloids, more commonly known as **alginate**s, were developed from seaweed during World War II. Alginate impression material has largely replaced the reversible type for impressions. The advantages of alginate material are that it is easy to prepare and handle, it does not require excess equipment and advanced preparation, it is comfortable for the patient, and it is inexpensive. Alginate is used in making preliminary impressions for all study casts and most final impressions for RPD working casts.

According to the American Dental Association (ADA) specifications, alginate materials are divided into two types based on gelling time:

- Type I—Fast set material, must gel in 1 to 2 minutes.
- Type II—Regular set material, must gel in 2 to 4.5 minutes after the beginning of the mix.



Also, under ADA specification, the manufacturer is required to include detailed instructions for use. The dental assistant should read and follow these directions carefully.

### **Synthetic Rubber Materials**

Rubber impression materials are supplied as pastes in collapsible metal tubes that require mixing. One tube contains the **base**, while the other contains an **accelerator** or a **catalyst**. When mixed in appropriate amounts, the mixture hardens to a synthetic rubber. Other types of materials come in the form of double-barreled injector cartridges that do not require mixing.

**CONSISTENCY TYPES.**—Rubber impression materials can be used for almost any impression. They come in three consistencies and are discussed in the paragraphs that follow.

**Light Bodied.**—Light bodied impression materials are injected with a syringe onto preparations for inlays, crowns, and FPDs. It is also used as a "wash" impression for full dentures, relinings, and RPDs. Its high degree of flow registers the fine detail.

**Regular Bodied.**—Regular bodied impression materials are used in an impression tray for inlays, crowns, and FPDs.

**Heavy Bodied.**—Heavy bodied impression materials are used in a tray to force light bodied impression material onto the cavity preparation or with a copper band for impressions of single teeth.

**MATERIAL TYPES.**—Rubber impression materials can be grouped into three types depending on their composition: polysulfides, silicones, and polyethers.

**Polysulfides.**—The polysulfides (rubber base) can be identified by the usually dark color of one of the two pastes and their resulting opaque mix and sulfur smell. If the materials are improperly mixed, the impression will have streaks in it, thereby affecting dimensional stability. Mixing time is between 45 and 60 seconds with a 5-minute working time. The impression must not begin setting before placement in the mouth. If the 5-minute working time is exceeded, the resulting impression will have inadequate expansion, producing a smaller cast. The impression must set completely before removal from the mouth and poured no later than 1 hour after removal.

**Silicones.**—Silicone (vinyl polysiloxanes) materials are generally lighter in color, translucent

when set, and have a slight odor. Silicone types come in the form of a heavy putty, light, regular, and heavy bodied viscosities. The silicone material is used with a stock tray to make up the bulk of the impression and minimize distortion. Manufacturers have been able to control shrinkage resulting in impressions with greater accuracy when compared to all other rubber products. Impressions made from silicone do not have to be poured immediately. The material will remain accurate for several days so they can be repoured as necessary.

**Polyethers.**—Polyethers have lighter colors than polysulfides, but are darker than silicones. The working and setting times are much shorter than the other two rubber impression materials. Polyether is just as good to use as polysulfides to control shrinkage. Unlike polysulfide, polyether will absorb water. This type of impression material is very stiff, making it difficult to remove from the mouth and a cast. The dentist must take care when removing the tray with the material from the mouth, because the polyether tears easily in thin areas like the subgingival sulcus. For best results, use this material with a custom tray.

### **GYPSUM PRODUCTS**

Gypsum products are supplied in powder form. When mixed with water in the correct proportions, a paste forms that will eventually harden. This setting process takes place over several minutes, during which time the mixture is soft and pliable, and can be formed into the desired shape. During the setting process, gypsum gives off heat, which is characteristic of all its products. Each material in the gypsum group is carefully compounded to give it the particular combination of physical properties needed for a particular work order. Dental plaster, stone, and die stone are the most frequently used gypsum products.

#### **Dental Plaster**

Plasters made for dental use are specially processed to provide high purity and suitable working properties. One of the most important requirements is that the plaster must set within a definite time limit.

Plaster has many uses. It can be used to form casts, construct matrices, and attach mount casts to an articulator. The initial setting time for most dental plaster is from 7 to 13 minutes. The final set is completed within approximately 45 minutes.

## **Dental Stone**

Compared to plaster, dental stone requires less water in mixing and sets more slowly. When it is set, it is harder, denser, and has a higher crushing strength. These differences make stone the choice to use over dental plaster when using it as a master cast for complete dentures and partial denture construction. Stone is more resistant to scratching and damage and can withstand more pressure in acrylic processing. Stone has many uses, including pouring, mounting casts, and flasking dentures for processing. The initial setting time of a typical stone mixture varies from 8 to 15 minutes. The final set occurs within approximately 45 minutes.

## **Die Stone**

Historically, die stone was only used for making the first pour of a working cast for fixed prosthodontics. Improved die stone now is being used for working casts in removable prosthodontics.

## **DENTAL WAXES**

Dental waxes are important in the construction of dental prosthetic appliances. The waxes are supplied in different types, with each designed for specific purposes. Next we describe the waxes with which a chairside prosthetic technician needs to be familiar and be able to use.

### **Baseplate Wax**

Baseplate wax is used to create a spacer over the cast before custom trays can be made. Another use is as a block-out wax for undercuts on casts. It is available in sheet and ribbon form and is pink in color.

### **Bite Registration Wax**

Bite registration wax is a metal-impregnated wax in sheet form. It is used to record the occlusal relationships between a patient's opposing arches and to later transfer this relationship to the cast for articulation. Often without this record, it is impossible for the dentist or the laboratory technician to properly occlude the patient's cast.

### **Indicator Wax**

Indicator wax is usually green in color and is coated with a water soluble adhesive on one side. It is

used for registering occlusal contacts on natural teeth, individual restorations, FPDs, RPDs, and CDs. It is sometimes used by the dentist to evaluate high spots on restorations.

### **Sticky Wax**

Sticky wax is made of beeswax, paraffin, and resin. Its colors are orange and the darker shades of blue, red, and violet. The resin gives the wax its adhesiveness and hardness. An important requirement of sticky wax is that it must break under pressure rather than bend or distort. This property makes it useful for holding the parts of a broken denture together so that it can be repaired.

### **Utility Wax**

Utility wax is a red or colorless wax that comes in rope form. It is extremely pliable and tacky at room temperature, making it usable without heating. Its main use is in beading (curbing) impressions before boxing and pouring. It can also be used on the impressions trays to avoid the flow of impression material to the back of the throat and to avoid injury to the soft tissue.

## **ACRYLIC RESINS**

There are a number of acrylic resins that you will use and need to be familiar with in prosthetic assisting. *Polymerization* is the term used to describe the processing or curing of acrylic resins. Acrylic resins can be classified by its method of curing. Some of the more common acrylic resins include the heat-cured, self-cured, and light-activated types. When handling acrylic resins, you should be sure to read the manufacturer's instructions and safety precautions before using.

### **Methyl Methacrylate**

Methyl methacrylate is the most widely used synthetic resin used in dentistry. The resin is usually supplied in a fine powder (polymer) and liquid (monomer). They are mixed to form a gel or dough and processed into a rigid solid.

### **Clear Acrylic**

Clear heat-cured acrylic resin is used to construct night guards and surgical templates. As a surgical template (band-aid) it is used after extraction of remaining teeth to show the possible interferences between the alveolar bone and the immediate denture.

## **Crown and Bridge Resin**

These tooth-shaded acrylic resins are used in fixed prosthodontics to make temporary and permanent restorations. The self-curing type is used as an interim restoration while the permanent one is being fabricated. This resin is normally used with a vacuum or pressure-formed matrix to sculpt the contours of the interim crown or bridge.

## **Orthodontic Resin**

Self-curing orthodontic resin is used to fabricate nightguards and orthodontic retainers. It is normally supplied in the clear and pink types and can be used with several tinted liquids to produce different shades.

## **Repair Resins**

These resins are used to fabricate interim RPDs and to repair any acrylic prosthesis. They are normally only stocked by the dental clinic in self-curing pink and light-pink fibered shades.

## **Tray Acrylic**

Self-curing tray acrylic is used to make customized impression trays. Tray acrylic is usually light blue or white in color. You can lengthen the working time of this material by submersing the dough in cold water before it is ready to use.

## **OTHER PROSTHODONTIC MATERIALS**

Along with the prosthodontic materials previously explained in the above categories, you need to become familiar with other miscellaneous materials such as alcohols, mouthguard materials, separating media, tray adhesive, and treatment liners.

### **Alcohols**

Isopropyl, methanol, and denatured ethanol are examples of fuels used in an alcohol torch for softening plastic or melting wax. Of the three, denatured ethanol is preferred since it is safer to use and burns cleaner.

### **Mouthguard Materials**

Mouthguards are made from polyvinyl materials. This thermoplastic resin is molded over a cast by means of a vacuum-forming machine. The use of mouth protectors in sports is to reduce injuries to the

oral tissues, head, and neck. Custom fluoride trays also are made out of this material for prescribed home treatment with fluoride gels.

## **Separating Media**

Separating media prevents one material from bonding to another material. The medium coats the cast and seals off the pores so acrylic resins can now be fabricated on a dental cast and removed.

One type of separating media is tinfoil substitute that when used, forms a film on the cast. To use, paint it on the cast with a soft bristle brush. The film is fragile and can easily be scuffed off. If this occurs, remove the entire film and repaint. Place the acrylic resin to the cast within 1 hour of painting the film on the cast to avoid deterioration. Do not allow gypsum particles to contaminate the bottle of tinfoil substitute when applying to a cast. Many other commercially prepared separators are available to prevent bonding.

## **Tray Adhesive**

Custom impression trays are coated with this adhesive before they are filled with rubber impression material. This ensures that the impression material stays in the tray when it is removed from the mouth. Tray adhesive in spray form is also available for use with alginate impression materials and stock impression trays.

## **Treatment Liners**

Treatment liners, also know as tissue conditioners, allow oral tissues to recover, improving tone and health, before making a new denture or relining an existing one. The dentist changes the tissue conditioner at 3- to 4-day intervals since liners stiffen rapidly.

## **BASIC PROSTHODONTIC EQUIPMENT**

The prosthodontic equipment that you will use will be located in the dental laboratory and the prosthodontic DTR. Only the basic equipment is mentioned. Never operate or use any type of equipment without first reading the manufacturer's instructions on use, safety precautions, and maintenance.

## ALCOHOL TORCH

The alcohol torch (fig. 8-10) is used for smoothing wax surfaces, setting teeth, and waxing. It is also used with a variety of tasks that require an accurate, controlled pointed flame. It draws fuel through a wick from a reservoir near the top of the torch. Periodically trim all irregular or burned areas of the wick and check the nozzle tip to ensure that it is free from obstructions.

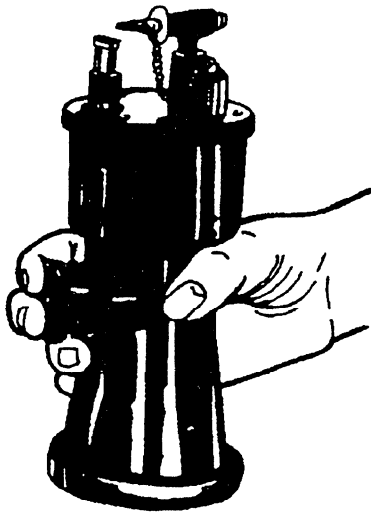### CAUTION

**Never overfill the fuel reservoir or attempt to fill it with the flame lit.**

Before using an alcohol torch, you should check the fuel level. Many different types of fuels can be used with an alcohol torch. Isopropyl alcohol in a solution containing about 70-percent alcohol and 30-percent distilled water by volume produces a flame of very poor quality. Further, 100 percent isopropyl alcohol tends to smoke badly while burning, which makes it somewhat undesirable as torch fuel. The best choice fuel for the alcohol torch is denatured alcohol (ethanol), which produces a clear blue flame. However, care with the accountability of denatured alcohol must be taken when used and distributed. Rubbing alcohol is unsuitable as a fuel.

**Note:** Methyl alcohol is highly poisonous if taken internally.

Do not leave the torch unattended when lit. Extinguish the torch when not in use by covering the wick with the nozzle holder assembly.



DTB20810

Figure 8-10.—Alcohol torch.

## ARTICULATOR

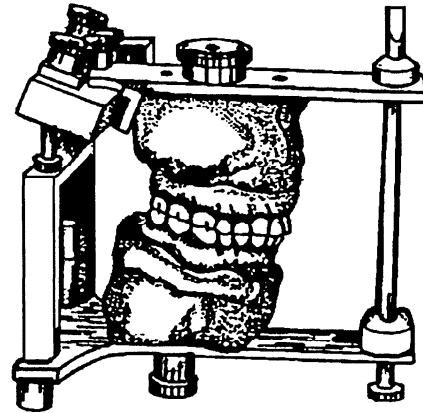
The articulator (fig. 8-11) is used to reproduce the patient's jaw movements. The dental cast made from impressions are mounted onto the articulator. This allows the dentist and the laboratory technician to recreate the normal movement of the patient's jaw during the fabrication of the prosthesis. There are several types of articulators. The type of articulator used depends upon the type of prosthesis being fabricated.

## BENCH LATHE

The bench lathe (fig. 8-12) is used during grinding, finishing, and polishing procedures. Always wear protective glasses or goggles when working with the bench lathe. Ensure that all chucks and attachments are securely mounted before starting the lathe.

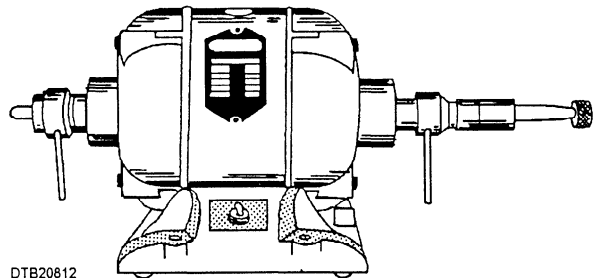
### WARNING

**Never leave an unattended lathe running, or attempt to stop the lathe by grasping the attachment with your hands.**



DTB20811

Figure 8-11.—Articulator.



DTB20812

Figure 8-12.—Bench lathe.

The lathe is used with rotary instruments (burs, stones, arbor bands, and ragwheels, etc.). An adapter and/or chuck is required to attach these instruments to the lathe.

### BUNSEN BURNER

The Bunsen burner (fig. 8-13) heats wax-carving instruments, waxes, and modeling compound. It requires a balanced air and gas mixture to produce a clean blue flame. It is attached to a gas valve with a non-collapsible hose.

Inspect the unit and hose daily for loose connections and defects. Have the hose replaced when it shows signs of wear. When wax or similar material drops into the burner, the burner assembly detaches easily for boiling out and cleaning.

**WARNING**

**Never leave an unattended burner lit or reach over an open flame, because the flame is almost invisible and can cause serious harm.**

### CAST TRIMMER

The cast trimmer (fig. 8-14) is used to trim and contour casts. A cast should present a neat, attractive appearance. This electrically operated machine has a 10-inch abrasive wheel, a small work table, and a water-dispensing mechanism to keep the abrasive wheel rinsed clean and clog free.

Before using the trimmer, ensure the water supply is on. Allow the water to run for at least 1 minute after

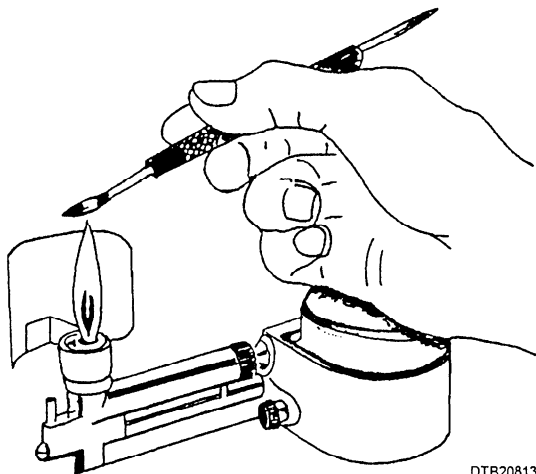


Figure 8-13.—Bunsen burner.

DTB20813

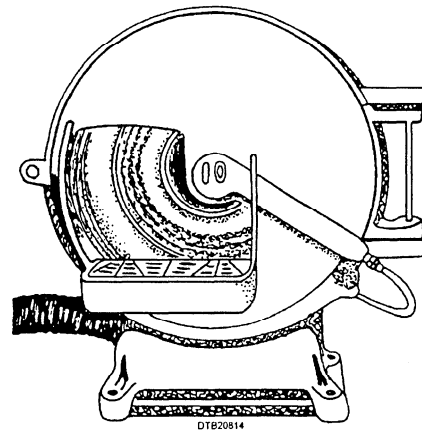


Figure 8-14.—Cast trimmer.

DTB20814

the procedure is complete. This will flush most of the particles from the trimmer drain and help prevent clogging.

**WARNING**

**When operating the trimmer, be sure to keep your fingers away from the wheel. Always wear safety glasses or goggles.**

Using light pressure, press the cast against the trimming wheel. Ensure that the water spray is sufficient to contain the grindings.

Check the unit for water leaks and the power cord for wear or damage. If the unit it does not operate correctly, contact the dental equipment repair technician. Clean the trimmer at least quarterly, or more frequently, depending on the amount of usage.

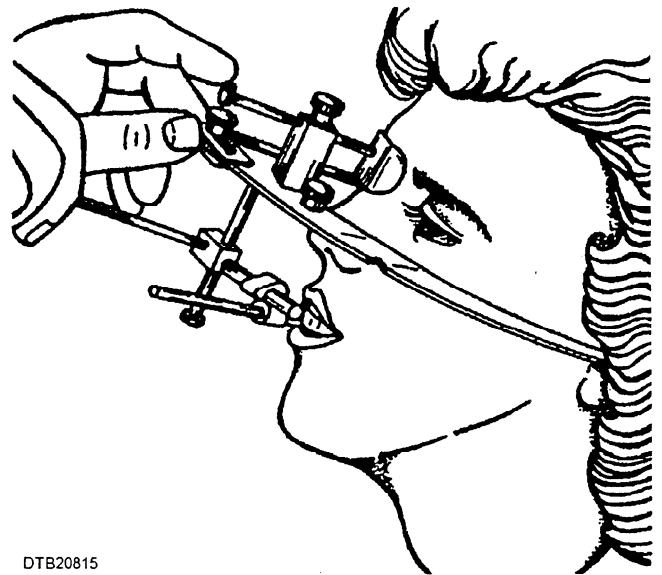


Figure 8-15.—Face-bow.

DTB20815

## FACE-BOW

The face-bow is a mechanical device (fig. 8-15) used to duplicate the position of the maxilla to an articulator. The face-bow rests on the patient's face and a wax bite plate is inserted into the oral cavity to record the patient's bite. Several types of face-bows are available for use.


## IMPRESSION TRAYS

Impression trays hold the impression material in place while it sets. The impression may include a portion of the arch or the entire arch. Generally, the impression tray is shaped to match the natural contour of the arch. The two basic types of trays are stock and custom trays. With either type, the tray used for the mandibular impression differs from the maxillary tray because it allows free tongue movement.

### Stock Trays

Stock trays come in many sizes for both the maxillary and mandibular arches. As figures 8-16 and 8-17 illustrate, stock trays may be rimlocking or mesh. Both stock trays are available in regular, edentulous, and orthodontic styles. Generally, the size of a tray will be identified on the handle tray.

Rimlock trays are easily identified by a rim that resembles a metal wire soldered along the inner part of the tray at the edge of the outer borders. The maxillary impression tray has a U-shaped wire soldered to a palatal area on the tray. Semiliquid impression



DTB20817

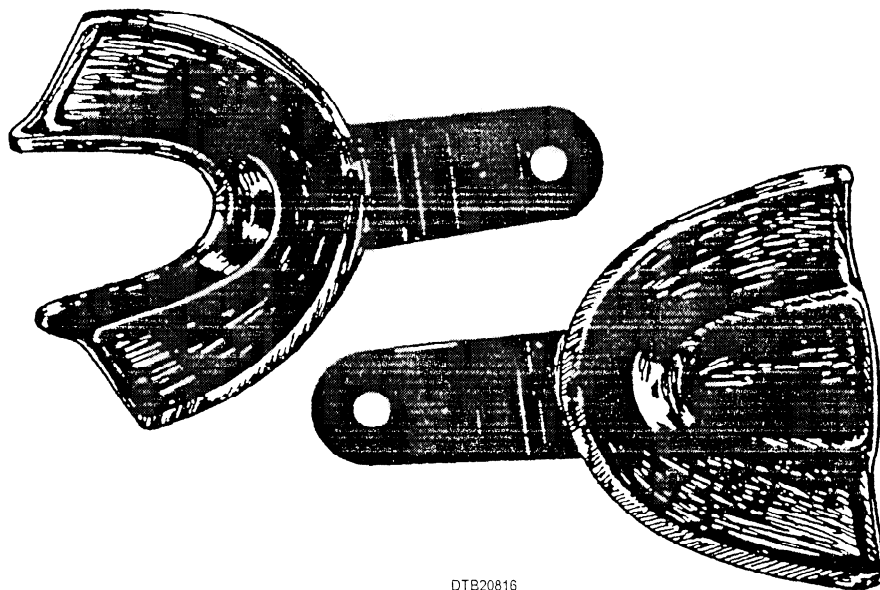
Figure 8-17.—Maxillary and mandibular mesh stock trays.

material flows into the undercuts (ledges) formed by the rim and sets (hardens). This locks the material in the tray.

Use liquid tray adhesive or the spray type on impression trays to ensure that the impression material does not separate from the tray. Stock trays are used for hydrocolloid impression materials. Unless disposable, stock trays must be cleaned and sterilized after each patient use.

### Custom Trays

Custom trays are made in the dental laboratory from tray acrylic. Since custom trays are made for individual patients, you must have a dental cast of the patient's teeth. The fabrication of custom trays is discussed later in this chapter.



DTB20816

Figure 8-16.—Maxillary and mandibular rimlock stock trays.

## MIXING BOWL

The mixing bowl is made of flexible material, either rubber (fig. 8-18) or flexible plastic, and used to mix alginate impression material and dental stone. It comes in small, medium, large, and extra large sizes. All sizes are used in the dental laboratory. A spatula is used to blend the powdered alginate or dental stone and water together. You may also find that a regular table knife may be used as a mixing spatula. In either case, the rounded ends on the spatula or table knife should approximate the contour of the mixing bowl.

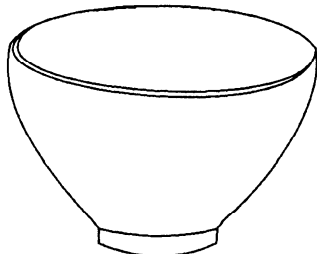
## PNEUMATIC CURING UNIT

The pneumatic curing unit (fig. 8-19) is commonly called a pressure pot. It is used during the polymerization of self-curing acrylic resins. It is used to cure relines and repairs of complete and removable partial dentures. The unit has a compressed air inlet that allows air pressure to fill the pot. Curing of the resin under pressure significantly reduces the possibility of pores or voids with the resin. Lukewarm water (115°F) is usually placed in the pot to hasten polymerization. To use, place the appliance that is to be cured in the pot. Ensure the appliance is completely submerged in the water. Secure the pot top. Fill the pot with compressed air. The normal curing time is 30 minutes at 20 psi.

### WARNING

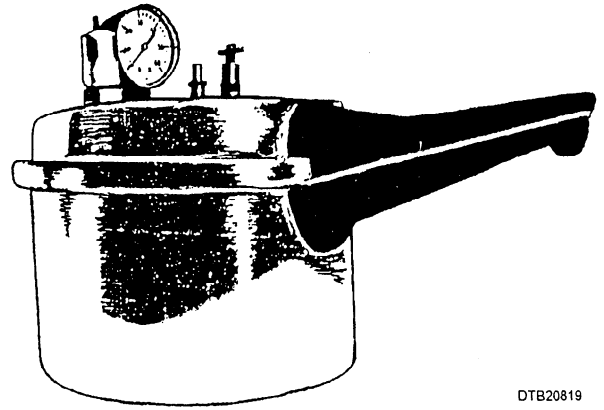
**You must never exceed the maximum air pressure indicated in the manufacturer's instructions. Excessive pressure may cause the pot to explode.**

Curing time may vary depending on the thickness of the resin being cured. After curing, use the air relief valve to let the air escape. Ensure that no air pressure remains in the pot when retrieving the cured prosthesis from the pot.



DTB20818

Figure 8-18.—Rubber mixing bowl.



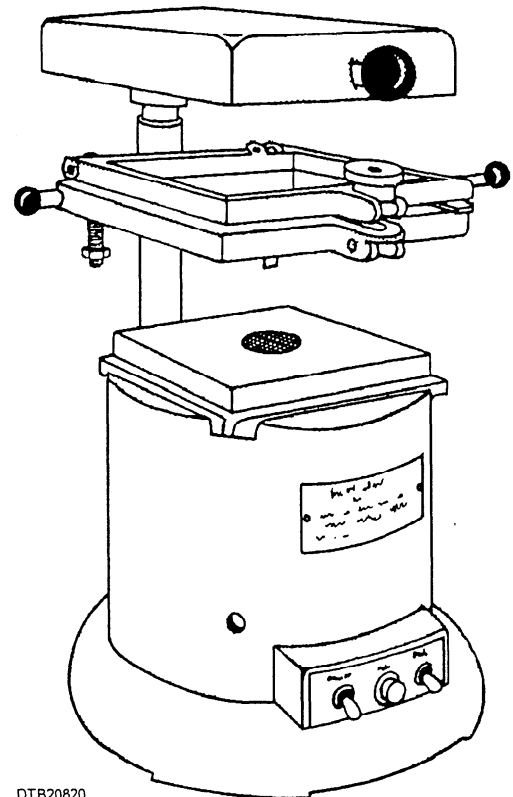
DTB20819

Figure 8-19.—Pneumatic curing unit.

Periodically check the seals, air inlets, and outlets for malfunction. Activate the pressure relief valve to ensure it is operational. When necessary, lubricate the "O" ring inside the lid with petrolatum.

## VACUUM ADAPTER

The vacuum adapter (fig. 8-20) is used for the rapid fabrication of custom trays, stents, mouthguards, and bite guards. This unit is also referred to as the vacuum former. The vacuum former will soften a sheet of plastic or acrylic resin and then draw it onto the cast with suction.



DTB20820

Figure 8-20.—Vacuum adapter.

The heating element is housed inside a metal assembly at the very top portion of the unit. This section will become extremely hot when in use. Use caution. Before use, inspect the vacuum holes in the platform to make sure they are not obstructed. Inspect the rubber sealing gasket for cracks and deterioration. Clean the exterior of the unit and inspect the electrical cord and plug before each use.

## VIBRATOR

The vibrator (fig. 8-21) is used to move dental plaster or dental stone mixes when pouring a cast. The vibrator also increases the density of the mix by eliminating air bubbles. A rheostat control is used to adjust the intensity of the vibration from a gentle agitation to a vigorous shaking.

To maintain the vibrator, cover the rubber platform and body of the unit with a plastic cover. As a safety precaution, check the power cord and plug for defects before use.

## BASIC PROSTHODONTIC INSTRUMENTS

Some of the common prosthodontic instruments you and the dentist will use during patient treatment and in the fabrication of dental prostheses are explained in the following paragraphs.

### CROWN REMOVER

To remove a crown from a tooth, the dentist uses a crown remover instrument (fig. 8-22). The handle on the crown remover is encircled with a heavy-steel weight that slides from one end of the handle to the other. Two interchangeable points make up the working end. One of these points is contra-angled and the other is straight. Both points have a right-angle


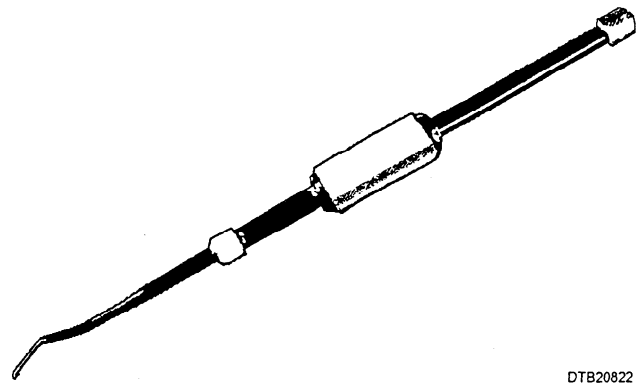


Figure 8-21.—Vibrator.

DTB20821



DTB20822

Figure 8-22.—Crown remover.

projection at the top. When the crown remover is used properly, the tip is placed over the margin or junction of the crown and tooth first. Then the sliding weight on the handle is tapped against the bottom part of the handle.

### ROACH CARVER

The roach carver (fig. 8-23) is a double-ended instrument used to cut, smooth, and carve dental waxes. At first glance, it appears to look like a wax spatula. A closer look reveals a spear-shaped blade at one end, with a deep-welled, very small spoon at the other end. Both ends have very sharp edges. The deep-welled end may also be used to carry melted wax.

### PROSTHODONTIC KNIVES

Usually, two kinds of knives are used in the prosthodontic treatment room: the compound knife and plaster knife. As the names imply, one is used with compound, and the other with plaster.

#### Compound Knife

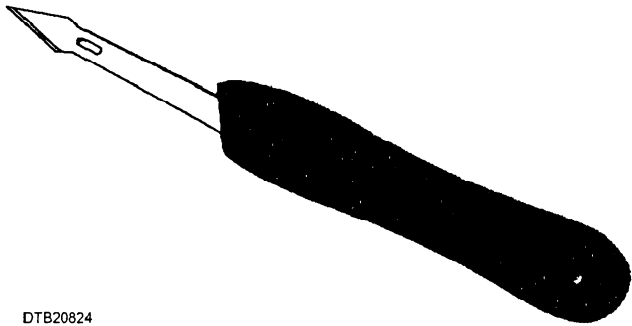
The compound knife (fig. 8-24) has a fairly large, red plastic handle and detachable blade. Routinely the #25 blade is used to trim impression compound, wax, and other materials that require an extremely sharp cutting edge. The blade is almost identical to a larger version of the #11 surgical blade. Your primary concern with the compound knife is to replace broken or dull blades.



DTB20823

Figure 8-23.—Roach carver.





DTB20824

Figure 8-24.—Compound knife with #25 blade.


### Plaster Knife

The plaster knife (fig. 8-25) is a heavy-duty knife used to trim and chisel gypsum products and impression compound. It has a large flat blade at one end with a wide projection shaped like a screwdriver at the other end. The handle is made of wood and is riveted in place. You must keep its blade sharp.

### PROSTHODONTIC SPATULAS

Spatulas are used in prosthodontics for handling dental waxes and mixing impression materials. The laboratory spatula shown in figure 8-26 is used to mix the various impression materials. It has a 2-1/2 inch flexible blade, which is about 1-inch wide with a rounded end. The handle is usually made of wood or plastic.

The wax spatulas commonly used are the #7 (fig. 8-27) and the #31 (fig. 8-28). Both spatulas are used to hold small bits of wax over a Bunsen burner flame that delivers liquid wax.




DTB20825

Figure 8-25.—Plaster knife.




DTB20826

Figure 8-26.—Laboratory spatula.



DTB20827

Figure 8-27.—Wax spatula, #7.



DTB20828

Figure 8-28.—Wax spatula, #31.

### PRELIMINARY IMPRESSIONS

Preliminary impressions are a three-dimensional record of a patient's dentition and anatomy of the alveolar process. Almost all prosthodontic treatment requires preliminary impressions be taken so that a dental cast can be made and used by the dentist as a diagnostic tool and to fabricate various prosthodontic appliances.

### MATERIALS REQUIRED

The dentist may direct you, under supervision, to take preliminary impression of the dental arches of a patient. You will need the following materials:

- Alginate
- Impression trays
- Rope-style utility wax
- Mixing bowl, spatula
- Mouth mirror
- Mouthwash
- Water

### IMPRESSION PROCEDURES

Once you have all your materials standing by, take a few minutes and explain to the patient what is involved in the impression procedure. The key to taking good impressions is to have the correct size impression tray fit the arches, to mix the alginate, position the tray correctly in the mouth, have the patient relax and breathe through the nose, let the

alginate set, and correctly remove the impression tray. Use the following steps to take preliminary impressions:

1. Select the correct size impression tray and ensure its fit in the patient's mouth is correct. Allow 3-4 mm of space between the tray, teeth, and soft tissues when the tray is positioned in the mouth.

2. Place utility rope wax around the top border of the maxillary and mandibular trays to extend their height. This will also act as a "pad effect" on the soft tissues. Place the trays in the mouth again to ensure the fit.

3. Mix the alginate and water together in the mixing bowl with a spatula. Follow the manufacturer's instructions. Mix into a creamy, smooth consistency. Use the sides of the mixing bowl and press the mixture against it to eliminate air bubbles. Total mixing time is usually 1 minute depending on the type or manufacture of alginate used.

4. Have the patient rinse with mouthwash vigorously. This aids in removing food particles and thick saliva that may cause voids in the impression.

5. As the patient is rinsing, load the **maxillary** tray with the mixed alginate. Load the tray with one large portion of alginate on the spatula using a wiping movement to avoid air being trapped in the material.

6. Wipe off any excess alginate, and smooth the surface of the tray with your index finger. Use the excess alginate from the mixing bowl and place some directly onto the palate with your index finger before seating the impression tray. This prevents a large void within the palatal vault.

7. Have the patient open his/her mouth about halfway. Using your left index finger, retract the patient's right cheek. Carefully place the filled tray into the patient's mouth and use the tray to move the left cheek out of the way.

8. Guide the tray in the mouth and center it over the maxillary teeth. Pressing up with the posterior border of the tray, raise the tray to the hard palate area to form a seal.

9. Keeping the posterior border of the hard palate in place, next raise the tray up over the maxillary teeth. The tray should be seated so that it is parallel with the occlusal plane.

10. Holding the tray in place with your right hand, use your left hand to gently lift the patient's lips and cheeks away from the tray until it is completely seated.

The maxillary arch should now be completely embedded in the alginate material.

11. While keeping the tray parallel with the occlusal plane, pull the upper lip over the anterior border of the tray to form the anterior section of the impression. The average working time from mixing the alginate material to this step is 1 1/2 minutes. After this time, the alginate begins to gel and set up.

12. Still holding the tray in place, look in the patient's mouth and ensure that no alginate material is running down into the throat area. If needed use a mouth mirror to remove any excess. Have the patient relax and tilt the head down and breathe through the nose as the material is setting up. A saliva ejector or patient napkin needs to be in place to catch any excess saliva while the alginate is setting up.

13. After the alginate has set, place one of your index fingers along the lateral border of the tray and press down to break the seal formed by the set alginate material. Once the seal is broken, carefully remove the tray from the patient's mouth and wrap the tray in a moist paper towel. Have the patient rinse his/her mouth out to remove any excess material left from the impression. Have the dental officer inspect the maxillary impression for accuracy.

14. Next, take the mandibular arch impression using the same basic steps as with the maxillary arch technique. When seating the mandibular tray onto the lower arch, have the patient raise the tongue to allow the alginate in the tray to take an accurate impression of the lingual aspects of the alveolar process.

15. Once the tray is seated, gently pull the lower lip over the anterior border of the mandibular tray to form the anterior section of the impression.

16. After the alginate has set, remove the mandibular tray in the same fashion as with the maxillary arch, except push up to break the seal.

17. Have the patient rinse his/her mouth again, and have the dental officer inspect the mandibular impression for accuracy. Wrap in a moist paper towel.

18. The dental assistant will now disinfect the maxillary and mandibular impressions. While in the DTR, remove the moist paper towels. Rinse and disinfect using an accepted phenyl disinfectant on the impression material and trays. Wrap in moist paper towels again and place impressions in a headrest cover for transportation to the dental laboratory.

## FABRICATING CAST

The laboratory technicians will usually pour most of the impressions, but there will be times when you must perform this task. To fabricate a quality cast, you must first start with a quality impression.

### PREPARING TO POUR IMPRESSIONS

Once you have an accurate impression, producing an accurate cast is simple if the impression and materials are prepared correctly. A minor mistake in any of these areas could cause a distorted cast.

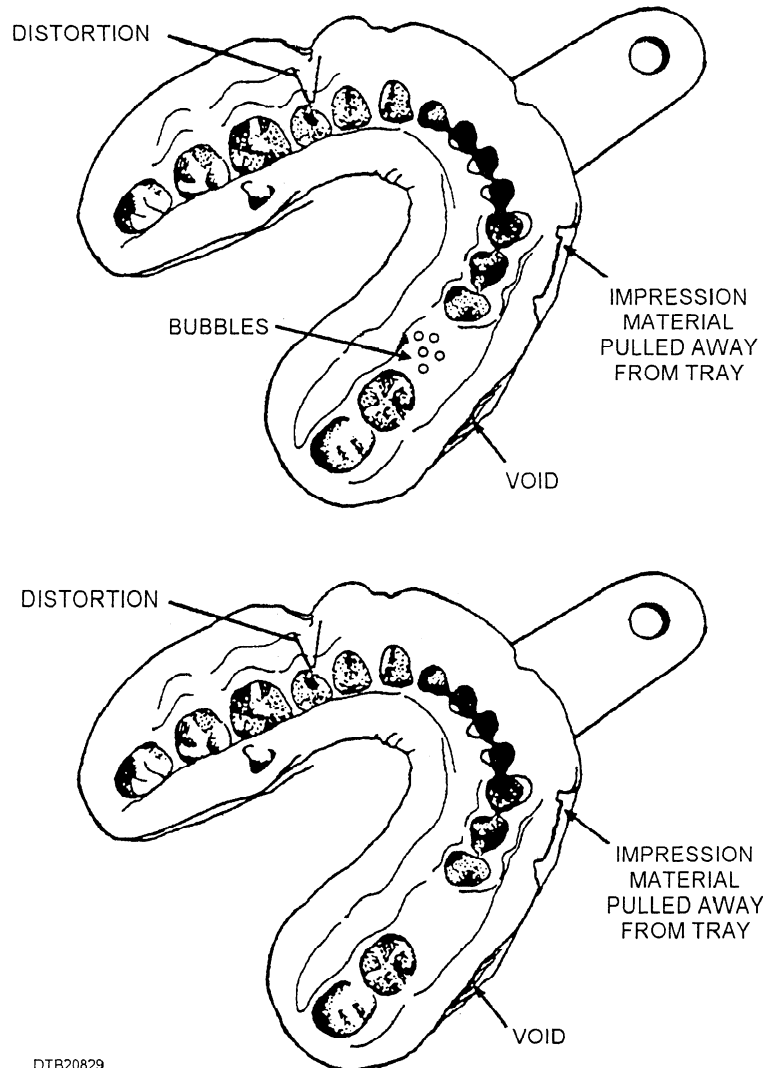
### IMPRESSION

Pour the impressions as soon as possible because all impression materials are subject to distortion. Cleanse impressions to remove mucous and saliva. This helps to ensure accurate surface detail and

eliminates the chance of soft spots in the cast. To cleanse the impression, rinse it under cool tap water, or lightly sprinkle stone into the impression and thoroughly rinse the stone away. If there is heavy mucous and blood in the impression, you might need to brush it lightly with a large soft sable paint brush. Remove excess moisture by gently shaking the impression. Never dry an impression or use an air blast to remove moisture because you might distort or tear the impression material. Figure 8-29 illustrates common problems with alginate impressions.

### MATERIALS AND MIXING

To produce a good cast from the impression, you need to use a properly mixed gypsum product. Most often you will use hydrocal (dental stone). To assure a good cast mix, perform the following steps.



DTB20829  
Figure 8-29.—Common problems with alginate impressions.

1. Always use a clean mixing bowl and spatula. The best time to clean a bowl and spatula is immediately after pouring the impression while the material is still soft and easy to remove.

2. Measure the volume of water and weigh the powder before you mix any gypsum material. An accurate water-to-powder ratio is a must to preserve the properties of any gypsum product.

3. Always add the powder to the water, never the water to the powder.

4. Spatulate thoroughly by hand, incorporating all the powder evenly throughout the mix until creamy. Avoid whipping the mix; doing so will cause the final product to have excessive air bubbles.

5. Vacuum mix using a power mixer-investor whenever possible. Vacuum mixing helps to eliminate incorporation of air into the mix. If you can't vacuum mix, tap the mixing bowl against the bench top or hold it on the vibrator for a few moments to express any air that might be trapped in the mix.

6. Never add water to a mix that is too thick; this interferes with the setting properties. It would be better to discard the mix and start over again.

## POURING IMPRESSIONS

The primary objective when you pour a cast is to capture all the surface detail of the impression, and as bubble-free as possible. This is done using a vibrator to make a thick gypsum mix, which flows into all the crevices of the impression. There are several ways to pour impressions, such as the upright, two-step, and boxed methods. We will only discuss the two-step method of pouring a cast, because it is the most successful method of pouring preliminary and final impressions.

### First Pour

Begin by holding the impression tray so that the handle rests against the vibrator. Start at one end of the arch and flow a small amount of stone into the impression, letting it slowly advance to the other side as shown in figure 8-30. Flow the stone slowly enough to watch the progress of the stone as you fill each tooth imprint. This should eliminate bubbles. If a bubble appears and does not go away with vibration, pop it with a small instrument. Use an acrylic mixing spatula to place small amounts of stone into minute preparations or teeth with wide incisal and narrow


cervixes. Touch the impression to the vibrator to flow each addition of stone.

After covering all the critical surfaces of the impression, you may safely add progressively larger amounts of the mix. There is a rate of vibration that is best for each mix's ability to flow. The vibration intensity should be set high enough to make the material move across the surface of the impression. The vibrator is set too high if the impression "jumps" in your hand, moves so fast that it skips over surface detail, or if vibration wave patterns develop on the surface of the mix. Continue filling the impression stone to a level slightly above the height of the impression walls (about 2 mm thick). Do not flow stone over the outside of the tray because it must be removed before the impression can be separated from the cast.

Lastly, add retention nodules to this first pour as shown in figure 8-31(A). Stone retention nodules are used between the first and second pours so the two stone layers can be locked together mechanically. Place the handle of the tray in a holding device; do not lay the impression on the counter or the cast will be distorted. Now let this first pour set for about 45 minutes, or at least until the stone loses its glazed appearance before making the cast base.

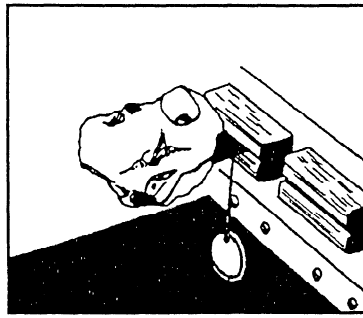
### Second Pour

It is now time for you to make the cast base. Use the cast trimmer to grind down the long retention nodules (if completely set), reduce the base of the cast's thickness, and make the top of the tray parallel to the cast's bottom. In general, the length of the retention nodules should equal the height of the tray flanges.

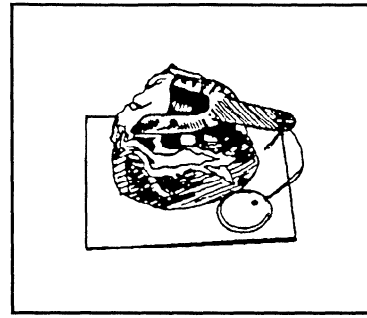


D1B20830

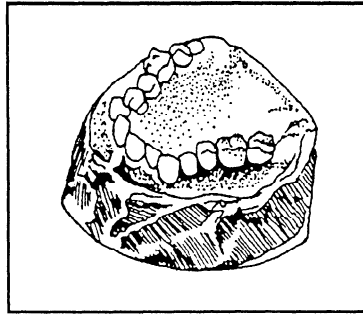
Figure 8-30.—Pouring the first pour of an impression.



(A) FIRST POUR WITH RETENTION NODULES



(B) HARDENED FIRST POUR FLIPPED ONTO A STONE PATTY



(C) CAST SEPARATED FROM THE IMPRESSION

DTB200831

Figure 8-31.—Two-step method of cast fabrication.

With a second mix of stone, form a patty for the base. Add stone around the retention nodules and invert the first pour into the patty. Now use your spatula to shape the sides of the cast base as shown in figure 8-31(B). Take care not to bring stone up onto the tray embedding the tray into the base. **With a mandibular cast, you must take time to smooth and contour the tongue space while the second mix is still soft.**

### TRIMMING CAST

Casts should present as neat and attractive as possible. After the heat generated by the final setting reaction dissipates completely (about 45 minutes), trim any stone from the outside of the tray with a plaster knife and separate the cast from the impression as shown in figure 8-31(C). Do not hurry and force the tray or you may break off some teeth, especially if the tray is embedded in the base. If a cast is not separated from an alginate impression before the alginate shows signs of dehydration, the cast will probably show unacceptable surface damage.

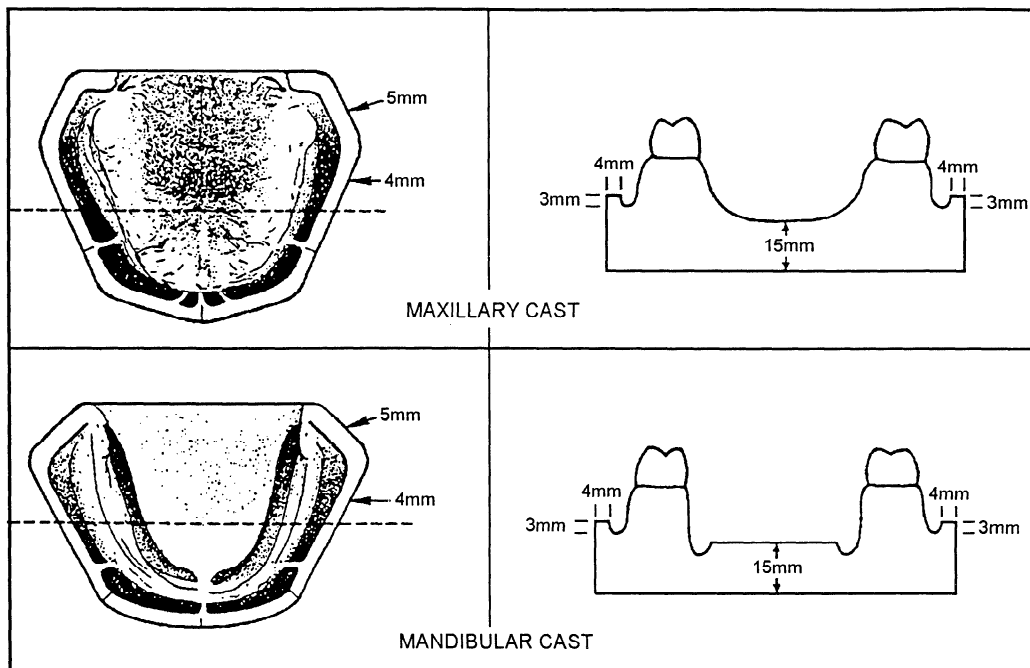
### PRELIMINARY STEPS

Before trimming the cast, you must soak it in a saturated dihydrate solution (SDS). Never trim a dry cast because the slushy debris coming off the trimming wheels will fall on the dry surface and become

permanently attached to the cast surface. Mark the cast with trimming lines. These lines will help you determine the base thickness; align the base plane to the occlusal plane of the teeth; and trim the outer boundary alongside the posterior teeth, the anterior teeth, and the posterior border of the cast.

### TRIMMING

Figure 8-32 shows the desired cast dimensions of a trimmed cast. Start trimming the cast by grinding the cast bottom parallel to the occlusal plane of the teeth. The cast should be about 15 mm (5/8 inch) thick at its thinnest place (usually the palatal vault of the upper and the tongue space region of the lower). Make sure the cast includes all the denture support areas and all of the features that define denture borders. Keep the cast free of nodules or voids. When trimming a maxillary cast, make it as much like the general shape shown in figure 8-32. Trim a mandibular cast to correspond with the shape shown in the same figure. Fully represent the sulci area in the cast, but not more than 3 mm deep. The sulci are routinely protected by a peripheral "land" area or ledge extending 4 mm outward. Make sure the cast extends 5 mm beyond the hamular notch area of the maxillary arch and 5 mm beyond the retromolar pads of the mandibular notch.



DTB20832

Figure 8-32.—Trimmed maxillary and mandibular cast.

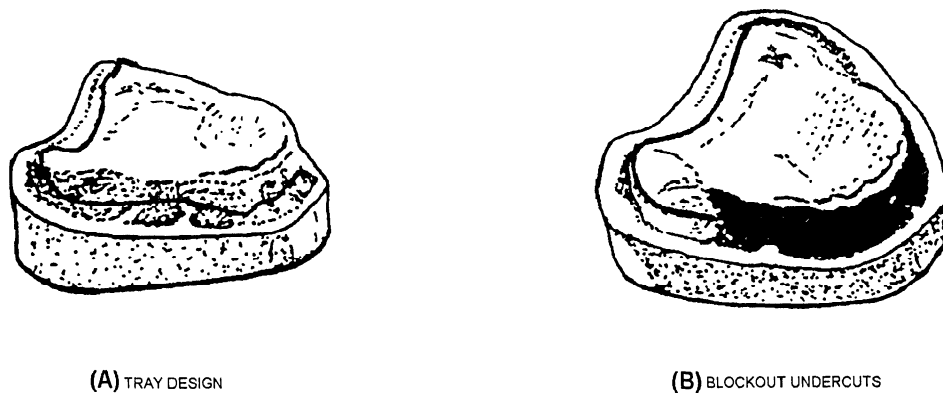
### FABRICATING CUSTOM IMPRESSION TRAYS

Prefabricated trays are made to fit everyone moderately well, but will not fit anyone very well. On the other hand, a custom tray provides a dentist with an impression material carrier that permits the dentist to make a more accurate impression that they could make using a stock (prefabricated) tray. The custom tray is made on a diagnostic cast. The dentist draws the border outlines of the proposed custom tray on the diagnostic cast, as shown in figure 8-33(A), and gives other directions, such as handle position and the need for vertical stops. You may then make the tray so it conforms to the design. Two of the most popular ways of making custom trays are self-curing resin dough

method and the vacuum method. We will limit this discussion to the more frequently used dough method.

### SPACERS

The dentist will usually prefer a custom tray that provides room for a controlled thickness of impression material. Spacers used to develop vertical tissue stops accomplish this purpose. The stops are made to hold the tray off the cast by a distance equal to the thickness of the spacer. When the spacer is removed and the tray is placed in the patient's mouth, the stops hold the inner surface of the tray out of contact with the patient's tissue. The subsequent space between the tray and tissue is then later filled with impression material.



DTB20833

Figure 8-33.—Design and blockout for a custom tray.

## FABRICATING TRAYS WITHOUT SPACERS

Custom trays for complete denture patients are often made without spacers and adapted directly to the ridge. If a spacer is not used for tray construction, the undercuts on the cast must be eliminated very carefully using baseplate wax. Failing to do so will result in a damaged cast or tray when you attempt to remove the hardened tray.

### Preparing the Cast

First, paint the cast with two layers of tinfoil substitute to prevent the acrylic resin from sticking. Next, use baseplate wax to generously block out (fill in) all undercuts within the tray area outlined on the cast as shown in figure 8-33(B).

### Mixing the Resin

Using premeasured amounts of monomer and polymer, add the powder to the liquid and mix the materials. Allow the mix to set until it reaches the doughy stage.

### Adapting the Resin

Use a simple stone mold to control the shape and thickness of the resin dough. This preshaped resin mass results in a tray of consistent quality when adapted to the cast.

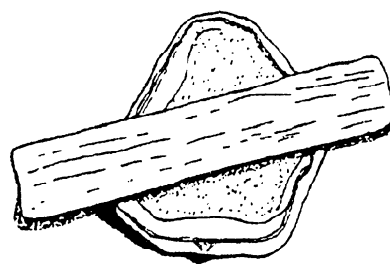
Lightly coat your fingers with petrolatum before placing the dough in the stone mold. Be sure the mold is also coated with petrolatum. Cover the dough with a moistened polyethylene sheet. Quickly roll out the resin to match the mold's shape and thickness as shown in figure 8-34(A). Trim away the excess dough and lift the acrylic resin blank from the mold.

Center the resin over the cast and rapidly adapt the dough by hand to the cast's surfaces. Be careful not to create thin spots by pressing too hard. Shape the resin to the borders and cut away the excess with a sharp knife as shown in figure 8-34(B).

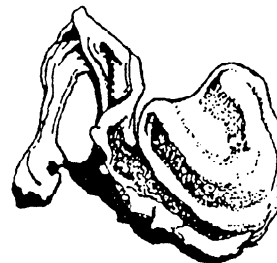Next, attach the handle to the tray, ensure the handle is strong enough to withstand considerable force, and that its shape will not interfere with lip movement. Mix another small amount of tray resin. When polymerization reaches the dough stage, form it into an L shape. Use a few drops of monomer to moisten the attachment site between the handle and the tray. Press the handle onto the moistened area. The fluid monomer should provide good bonding. If you work fast enough, you should be able to use the unpolymerized excess from the first mix for the handle as shown in figure 8-34(C).

### Finishing the Tray

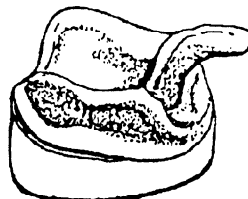
After the acrylic has set, remove the tray from the cast and remove any wax adhering to the inside of the tray. Trim the tray's flanges back to the peripheral



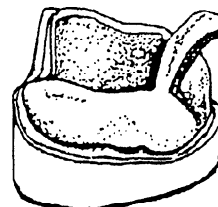
(A) ROLL OUT RESIN DOUGH



(B) APPLY RESIN WAFER;  
CUT AWAY EXCESS



(C) FORM A HANDLE



(D) FINISHED TRAY

DTB20834

Figure 8-34.—Fabricating custom trays using the dough method.

border markings as drawn by the dentist and shown in figure 8-34(D). Use the bench lathe with an arbor band to remove bulk. The posterior border of the maxillary custom tray is supposed to extend a short distance onto the soft palate. Mandibular custom trays cover the retromolar pads. Use acrylic finishing stones and burs for finer details. Be sure there are no sharp edges on the tray's borders.

### FABRICATING A TRAY WITH SPACERS

The preceding paragraphs described trays that were closely adapted to the diagnostic cast. In contrast, custom trays for **fixed restorative** patients are always made over wax spacers. The design for this type of tray appears in figure 8-35(A). With the exception of the tray's design and the use of a wax spacer, the procedures for fabricating a fixed custom tray are the same as we mentioned before. Let's briefly look at the differences.

#### Applying a Wax Spacer

After the dentist traces the outline on the diagnostic cast, you can fill the undercuts, and adapt two layers of baseplate wax to the tray area on the cast. Adapt each layer of wax, one layer at a time. Cut out four small pieces of the baseplate wax over the crest of the ridge areas outlined in the molar and cuspid regions

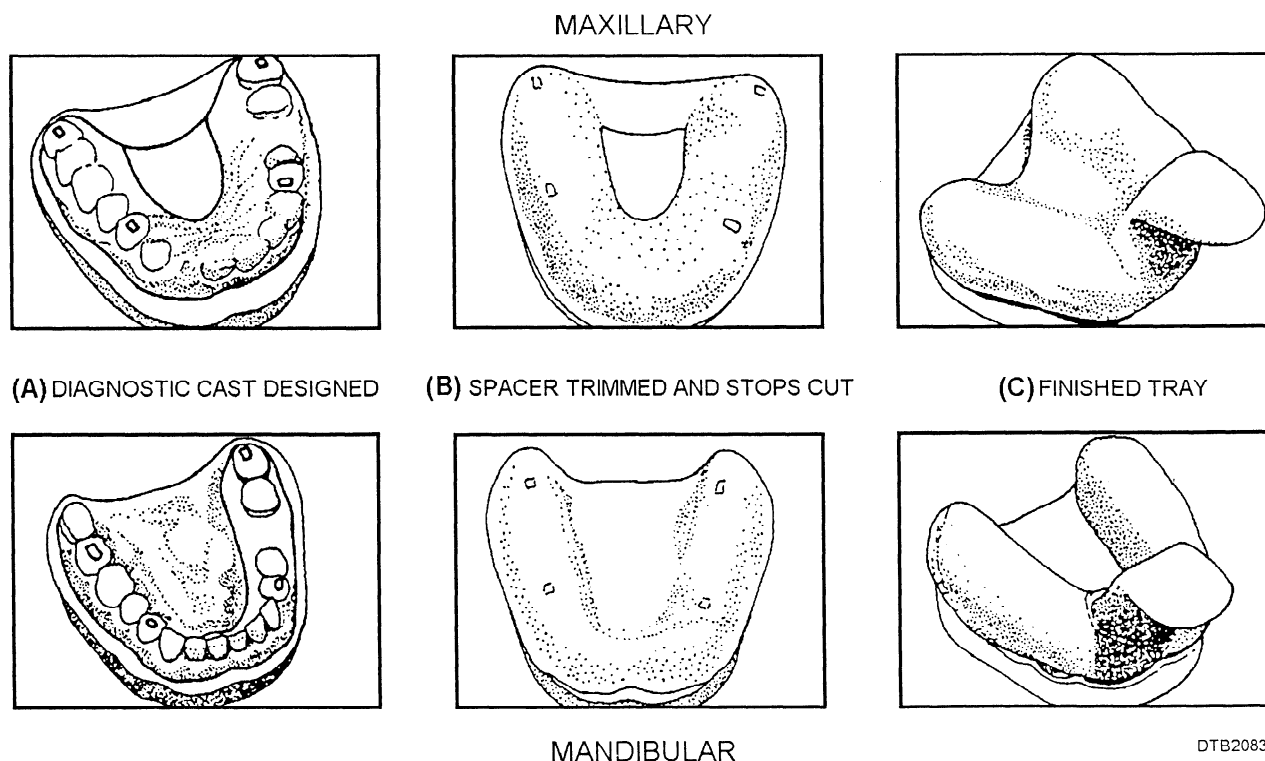
for tissue stops as shown in figure 8-35(B). Remove the spacers from the cast and apply a tinfoil substitute to the gypsum surfaces of the cast to prevent the acrylic resin from sticking. Place the spacer back on the cast and apply a **thin** layer of petrolatum to the surface of the baseplate wax. This will make removal of the wax from the polymerized tray easier.

#### Fabricating the Tray

Use the self-curing dough method to make the tray. After the resin is hard, remove the tray from the cast and pull the baseplate wax off the tissue surface of the tray. (Four tissue stops should appear on the ridge areas where the four pieces of baseplate wax were originally cut out.) Trim any excess acrylic resin to the outline border on the cast. Round and smooth the borders of the tray. Your finished trays should appear like those in 8-35(C). **Be certain to clean away all traces of petrolatum that might be present on the tissue surface of the tray.** (Sandblasting does this very effectively.) Clean and disinfect the tray, place it on the cast for storage.

### FABRICATING MOUTHGUARDS AND VACUUM-FORMED TEMPLATES

In addition to pouring and trimming study casts, and fabricating custom trays, you may be called upon



DTB20835

Figure 8-35.—Fabricating custom trays over wax spacers.



to fabricate mouthguards and vacuum-formed templates. Many of the steps involved in fabricating these devices are similar and fairly simple to learn.

## **FABRICATING MOUTHGUARDS**

Mouthguards are constructed of acrylic resin or vinyl-like material that covers and protects all of the teeth in the arch. The purpose of a mouthguard is to reduce the potential for injury to the teeth and surrounding tissues. Although a mouthguard does not prevent the teeth from fracturing, it does keep the fragments from lacerating or embedding in the oral tissue. The mouthguard also reduces the risk of concussion by acting as a shock absorber. If the head is impacted, the guard cancels part of the force, reducing the risk of concussion.

### **Preparing the Cast**

The first step in fabricating a mouthguard is to draw the outline of the mouthguard on the cast with a soft lead pencil. Design the mouthguard by drawing or scribing a line around the maxillary arch in the buccal flange area to the highest point to which you want the material to extend. Normally, the mouthguard extends to the point where the soft tissue meets the attached gingiva. Next, trim the working cast as close to the outline as possible as seen in figure 8-36(A). The thickness of the cast base should not exceed 6 mm. The reason for trimming the cast as specified is to facilitate the vacuum formation and to minimize stretching and thinning of the vinyl plastic during the molding. For the same reason, drill a hole in the palate with a large pear-shaped bur. Soak the cast in water for a couple of seconds to prevent the hot thermoplastic material from adhering to the cast. Remove excess water from the cast. Place the wet cast on the perforated plate of a vacuum-forming device.

### **Vacuum-Forming the Mouthguard**

Several different types of vacuum-forming machines can be used to adapt thermoplastic material. Most machines consist of a perforated plate connected to a source vacuum, an electrical heating element, and a metal frame in which the vinyl plastic blank can be clamped. Regardless of the machine's manufacturer, the procedures used to adapt the material are basically the same. The construction procedures, in general, consist of the following steps:

1. Clamp a vinyl plastic blank in the frame, and place it in position to be heated. The molding temperature usually is estimated by the amount the sheet of vinyl plastic material "sags" as it softens (fig. 8-36(B)). Excessive heating of the material will cause the mouth protector to stretch and thin out. Sharp reproductions of the surface detail are not necessary.

2. When the material is ready, turn the vacuum on and move the frame to the molding position (fig. 8-36(C)). Hold it in this position until the vinyl plastic is completely adapted to the contours of the cast.

3. Turn off the vacuum. Release the clamp on the frame and set the cast with the mouth protector aside until it cools completely.

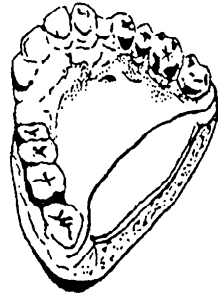
### **Completing the Mouthguard**

Trim excess material away with scissors as shown in figure 8-36(D). Heat a Bard-Parker blade and trim the outline of the mouthguard. Remove the mouthguard and reduce the borders to approximately 5-7mm. A large bur, arbor band, or finishing stone may be used to reduce the border thickness. Polish the edges with pumice, or lightly flame the mouthguard with an alcohol torch. Flaming has the benefit of clearing any cloudy areas in the material. Wash and disinfect the mouthguard, then place it in a prosthetic denture bag for delivery to the patient.

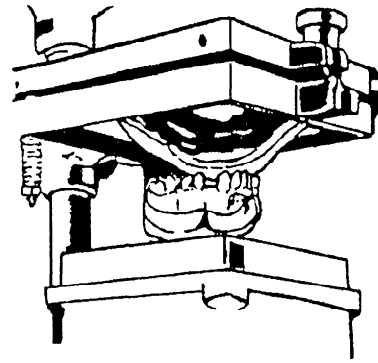
The completed mouthguard should conform to the general outline presented in figure 8-36(E). Notice that the posterior border of the maxillary mouthguard ends on the hard palate, and that the facial flanges do not restrict the movement of any frenula. The posterior border may end in the rugae area to increase the patient's speech and comfort.

## **FABRICATING VACUUM-FORMED TEMPLATES**

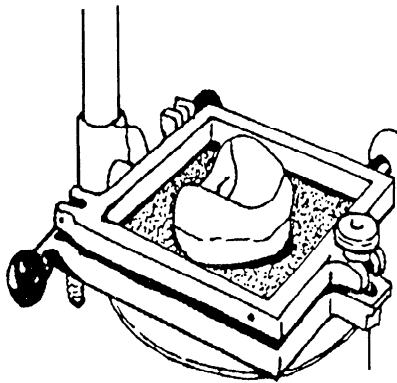
Provisional fixed restorations (temporaries) are usually made using some type of matrix or template. Two methods more commonly used for providing these templates are the impression method and the vacuum-forming method. Basically, the template or impression is a shell that will be filled later with tooth colored resin and seated on the prepared teeth, forming the provisional restoration. For this purpose, we will only discuss making a template using the vacuum-forming method since you are already familiar with how to make an impression.



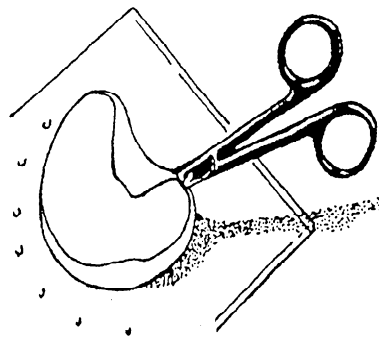
(A) CUT BACK THE CAST, OUTLINE THE MOUTH PROTECTOR'S BORDERS



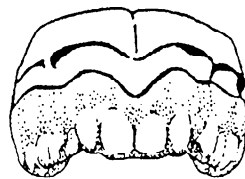
(B) HEAT MOUTH PROTECTOR MATERIAL IN AN ADAPTING UNIT



(C) SUCK THE MATERIAL DOWN ONTO THE CAST'S SURFACES



(D) TRIM THE EXCESS



(E) FINISHED PROTECTOR

DTB20836

Figure 8-36.—Fabricating mouthguards.

Vacuum-formed templates are made using clear splint material (.020-inch), a vacuum-forming machine, and a cast. If the teeth that the dentist intends to prepare have large cavities, fill in the defects with dental cement and carve the cement to the proper shape. If the temporary prosthesis is for a proposed FPD site, also adapt spare resin denture teeth to the edentulous space as shown in figure 8-37. Sticky wax them in place and if needed, adjust the occlusion.

Place the cast on the vacuum-forming machine and mount the plastic sheet below the heating element.

Heat the material until it sags about 1 1/2 to 2 inches, and vacuum-form the clear splint material over the cast. At first, the material appears cloudy and then will become clearer. You know the material is overheated when you begin seeing small bubbles appear.

Splint material is not pliable like mouthguard material, making it difficult to remove from the gross soft tissue undercuts that may be present on the cast. Use a heated Bard-Parker knife to cut away the excess material in the sulcus areas and around the base of the cast. You should now be able to pry the arch form

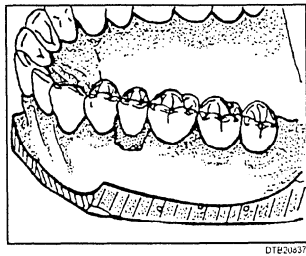


Figure 8-37.—adapting a denture tooth to the edentulous space.

template off the cast for final trimming with scissors. Cut out the section needed for the provisional restoration **plus** one or two uninvolved teeth anterior and posterior to it as shown in figure 8-38. When you are finished, clean and disinfect the template; and place it and any of the unused arch sections back on the cast so they won't distort. Often, subsequent restorations are made for the same patient, and the unused arch sections are kept in case they will be needed at a later date.

### SIMPLE ACRYLIC REPAIRS

Occasionally, you will be required to perform minor repairs on complete and removable partial dentures. These repairs may include fractured dentures, or replacing fractured, missing or loose teeth. These repairs may be caused by changes in the oral tissues, careless handling, etc. The dentist will decide if any impression of the patient's mouth is needed for the repair, and will tell you what needs to be done to complete the repair. Since every repair is a little different, these next procedures describe some, but not all, of the possible repair solutions. If you need assistance, refer your questions to the dentist or prosthetic technician.

### DENTURE BASE REPAIRS

Figure 8-39 shows a **simple** denture base fracture. The repair procedures will include aligning the fractured parts, pouring a plaster cast (matrix),

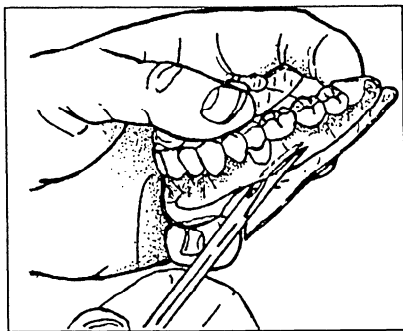


Figure 8-38.—Trimming away excess material with scissors.

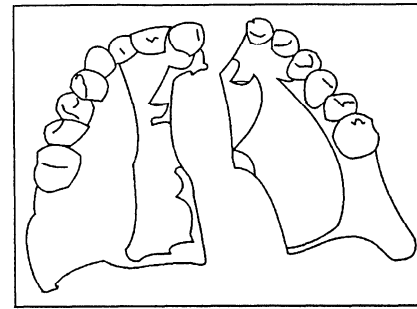
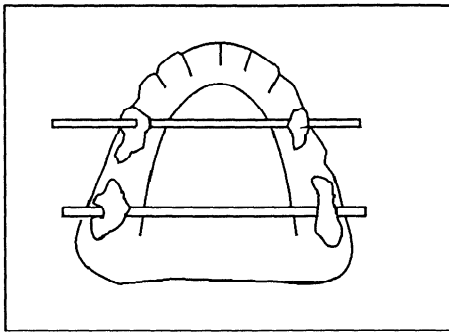


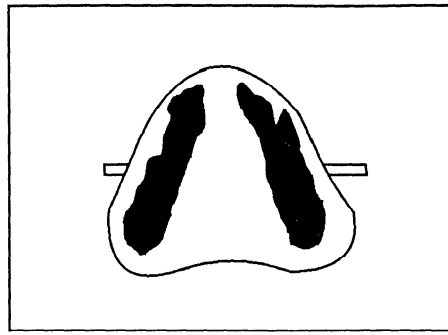
Figure 8-39.—Simple denture base fracture.

widening the fracture line and making retentive grooves, applying self-curing acrylic resin, adjusting, and polishing. When the pieces of the denture base cannot fit against one another in a precise relationship, or one or more fragments have been lost, this type of a fracture is classified as **complex**. Since complex fractures should be repaired by prosthetic technicians, they will not be covered in this chapter. To repair a simple denture base fracture, perform the following steps (A-H) shown in figure 8-40:

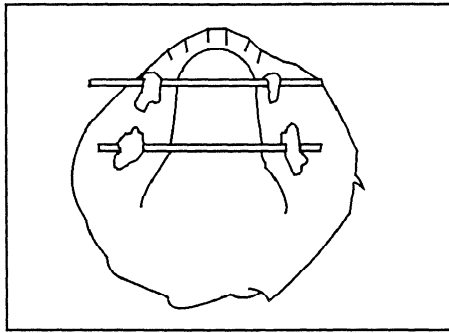
1. Align the fractured denture parts and apply sticky wax over the fracture line on the external surfaces of the denture.
2. Stabilize the parts by positioning denture burs with sticky wax as shown in step A.
3. Block out all undercuts on the internal surface that will be exposed to the plaster with a wet pumice mix or block out wax (step B). Do not block out undercuts along the fracture line. Blocking out the undercuts enable you to remove the plaster cast after it sets.
4. Prepare a plaster mix.
5. Slowly pour the plaster into the internal surface of the denture. The plaster cast should cover the fracture line, but not the entire denture. This procedure is accomplished by holding the denture in you hand and gently resting it against the vibrator.
6. Place the denture in an upright position (step C) and allow the plaster to cure.
7. Once the plaster is set, gently remove it from the cast.
8. Remove the denture burs and all traces of the sticky wax and pumice.
9. With a new denture bur, widen the fracture lines (step D) on the denture and place retentive grooves along the fracture line.
10. Paint two thin, even coats of tinfoil substitute on the cast (step E).



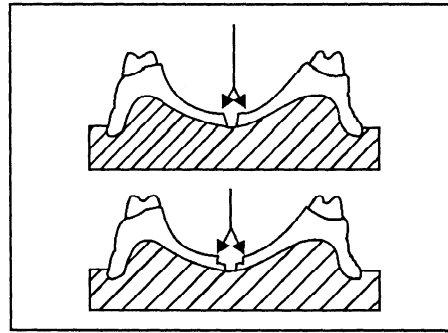
**A.** ALIGN AND STABILIZE THE FRAGMENTS.



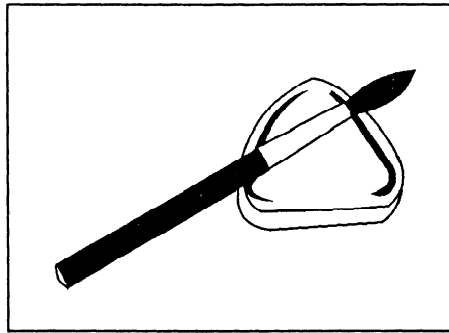
**B.** BLOCK OUT TISSUE SURFACE UNDERCUTS.



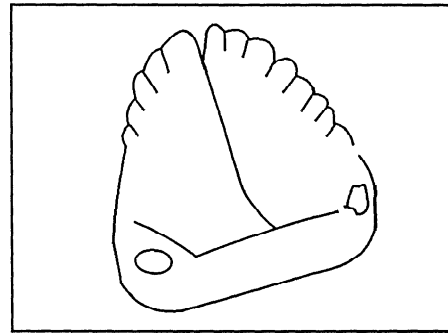
**C.** DENTURE UPRIGHT POSITION



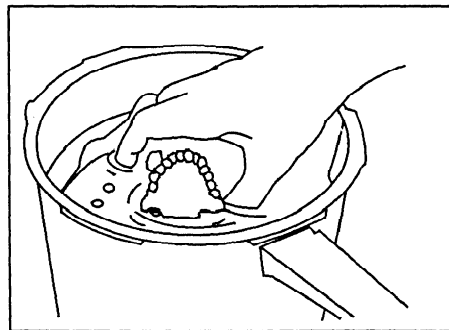
**D.** CROSS SECTION OF DENTURE, SHOWING WIDENED FRACTURE LINE.



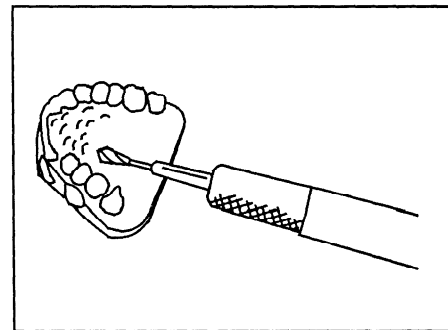
**E.** PAINT THE CAST WITH TIN FOIL SUBSTITUTE.



**F.** STICKY-WAX THE DENTURE FRAGMENTS TO THE CAST.



**G.** PLACE IN A PRESSURE POT.



**H.** TRIM EXCESS.

DTB20840

**Figure 8-40.—Denture base fracture repair steps.**

11. Align the denture parts on the cast and hold them in place with sticky wax at the posterior edges (step F).

12. Prepare the self-curing acrylic resin.

13. Moisten the brush with monomer and dip it into the polymer (powder), and apply it to the fractured area. Repeat this procedure until the fracture is covered and slightly overfilled.

14. Allow the denture to stand for a few minutes until the sheen of the resin disappears from the surface.

15. Place the denture and the cast in a pneumatic curing unit (step G).

16. Cover the denture with lukewarm water (115°F) and secure the lid.

17. Attach the rubber tubing to the air valve on the lid and till with compressed air to 20 psi.

18. The curing process will take 30 minutes.

Note: If a pneumatic curing unit is not available, place denture and cast in a bowl of lukewarm water for 30 minutes or until the resin hardens. This is not the recommended procedure but may be used in emergencies.

19. Gradually turn the air release valve on the lid to relieve the inside pressure. When the pressure gauge reads zero, carefully remove the lid.

20. Remove the repaired denture base from the pressure pot.

21. Using a denture bur, trim all excess acrylic from the denture (step H).

22. Polish the external surfaces with pumice and a muslin or brush wheel that is mounted on a bench lathe. If a lathe is not available, you may use a mandrel-mounted wheel on a straight handpiece.

23. Disinfect and place denture in a prosthetic bag with water for delivery.

## **DENTURE TOOTH REPAIRS**

The original tooth can be reattached if it is still intact, but some repairs will require a new denture tooth. The following procedures describe simple denture tooth repairs that do not involve the facial denture base plastic (complex fracture). The example given is of an anterior tooth that fell out. If the facial denture base plastic needs repair, a prosthetic technician or a dental officer will perform the repair. To accomplish a denture tooth repair, perform the following steps (A-F) as shown in figure 8-41:

1. Roughen the lingual aspect of the acrylic teeth to guarantee good chemical bonding with the repair material. Use an inverted bur to undercut a hollow opening in the lingual aspect of the acrylic tooth.

2. Make a box preparation (step A) in the denture base, lingual to the tooth to be repaired.

3. Position the tooth (step B) in its seat and sticky wax it in place from the lingual.

4. Construct a plaster cast facial matrix to hold the tooth in position during repair. It should include the tooth that is being repaired and the tooth on each side (step C).

3. After the plaster has set, remove the matrix and clean all wax from the box preparation (step D).

6. Paint the matrix with a tinfoil substitute (step E).

7. Reassemble the denture, the tooth, and the matrix in correct alignment. Sticky wax the tooth to the matrix, and the matrix to the denture (step F).

8. Place self-curing resin to the repair area in the same manner as described in the denture base repair section. Build up the repair resin slightly higher than the surrounding denture base.

9. Place the tooth repair in a pneumatic curing unit and follow the same steps as described in the denture base repair section for curing, finishing, and polishing.

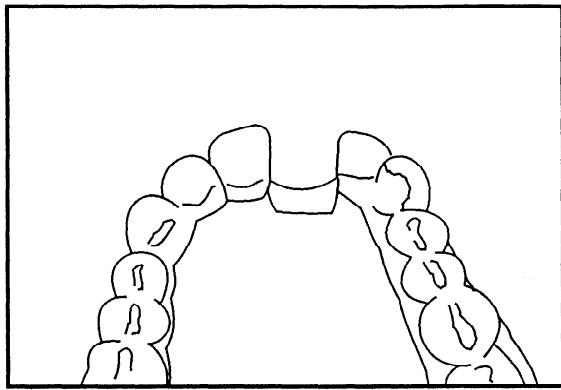
10. Disinfect and place the repaired denture in a prosthetic bag with water.

## **PROSTHODONTIC CHAIRSIDE ASSISTING**

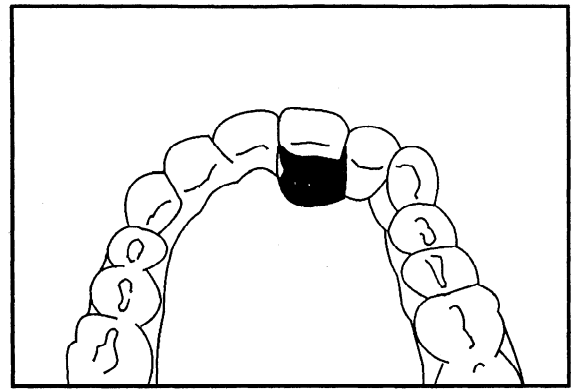
The basic clinical procedures are essentially the same as in all direct patient care in dentistry. The prosthodontic procedures, sequence of treatment, and materials required vary with the specific treatment requirements for the patient and the individual dentist. This section covers the basic chairside duties a prosthodontic assistant performs with a dentist. In-depth techniques and procedures should be learned from on-the-job training.

Most prosthodontic cases require a series of appointments. It is your duty as the assistant to schedule these appointments. Two basic factors influence the scheduling of prosthodontic patients:

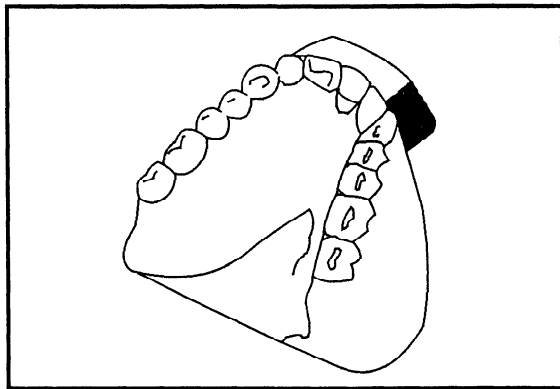
- The procedures to be done during the appointment



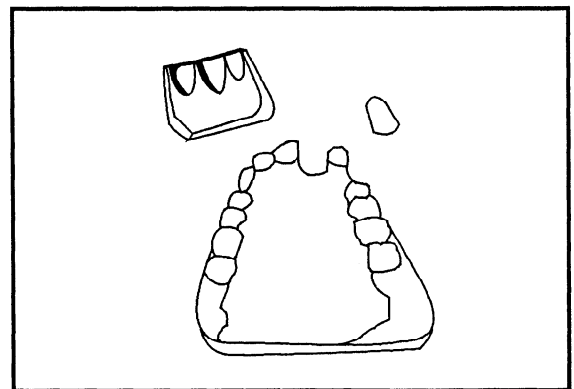
A. MAKE A "BOX" PREPARATION



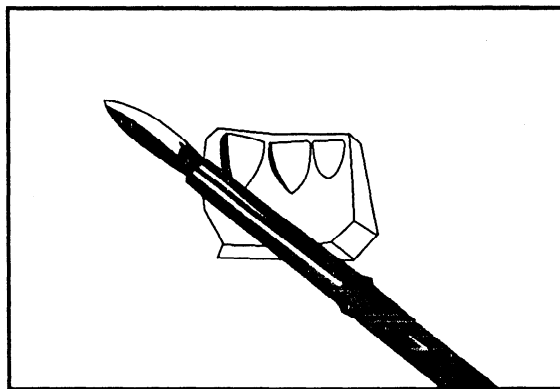
B. POSITION THE REPLACEMENT TOOTH



C. CONSTRUCT A FACIAL MATRIX




D. CLEAN ALL WAX FROM THE BOX PREPARATION



E. PAINT THE MATRIX WITH TINFOIL SUBSTITUTE

DTB20841



F. REASSEMBLE THE TOOTH, DENTURE,  
AND MATRIX

Figure 8-41.—Anterior denture tooth repair steps.

- The laboratory time required between appointments

These factors will, of course, dictate the time allocation and date for which you should reschedule the patient. Each new prosthodontic patient requires

an evaluation that may include complete oral radiographs. The dentist uses the radiographs to diagnose cysts, residual roots, unerupted and impacted teeth, periodontal conditions, caries, bone density, or toher conditions requiring restorative or surgical correction before prosthodontic treatment is started.

At the evaluation appointment, preliminary impressions are made and diagnostic casts are then poured from the preliminary impressions

### USE AND COMPLETION OF DD FORM 2322

Whenever dental laboratory work is required to support prosthodontic treatment, a DD Form 2322, Dental Laboratory Work Authorization (figs. 8-42), must be completed. This triplicate form has several purposes. It contains patient information and fabrication instructions, and is used as a precious metals voucher and an entry form for composite laboratory value (CLV) codes.

The responsibility for initiating the patient data for this form is usually delegated to the dental assistant. In doing so, you must take care to fill out the form completely and accurately. The dentist will fill in blocks 15-28. It advises the laboratory, in writing, exactly what materials to use and the services to be provided. An incomplete or inaccurate form may result in the lack of necessary items required to fabricate the prosthesis.

### FIXED PROSTHETIC PROCEDURES

Most steps in tooth preparation for crowns and FPDs are similar. The number of appointments to complete the fixed prosthesis will vary depending on what is being fabricated. A single metal crown can be delivered in 2 to 3 appointments; whereas, a porcelain fused to metal crown or bridge usually requires 3 to 4 appointments. A basic prosthodontic tray setup is illustrated in figure 8-43. You should become thoroughly familiar with each instrument and understand its use. The basic steps involved at this appointment involve selecting a shade (if porcelain is used), preparing the tooth or teeth, making the final impression, and preparing and cementing the temporary restoration.

### Shade Selection

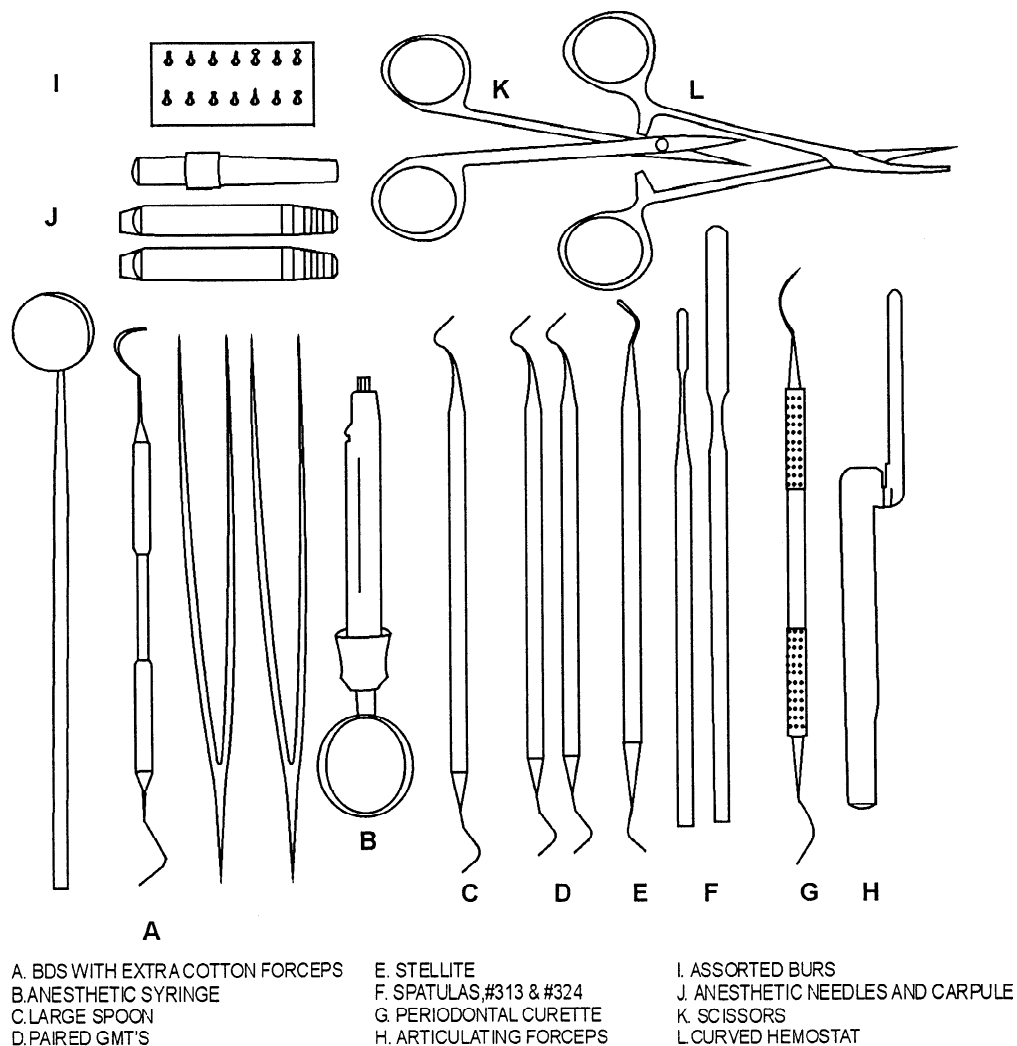
Before any tooth preparation, it is best if the dentist selects a tooth shade. Each manufacturer provides a number of different colors in its porcelain system and a shade guide for use in the selection of the tooth color. One the shade is selected, ensure that you or the

1. Local Case No.		2. Name of Treatment Facility, Mailing Address & Autovon No.			3. ADL Case No.		
4. Patient's Name (Last, First, Middle Initial)			5. SSN	6. Grade	7. Age	8. Date Initiated	
9. Beneficiary Type		10. Organization, Duty and Home Telephone Nos.			11. Date Forwarded		
12. Type of Prosthesis or Restoration			13. Shape and Mold by Guide		14. Date Delivered		
15. Prosthesis Design							
Request(s) (Check appropriate box(es))				16. <input type="checkbox"/> Framework Only		17. <input type="checkbox"/> Set-Up	
18. <input type="checkbox"/> Process		19. <input type="checkbox"/> Fully Fabricate		20. <input type="checkbox"/> Bisque Bake		21. <input type="checkbox"/> Consultation	
Included Items							
22. <input type="checkbox"/> Diagnostic Casts		23. <input type="checkbox"/> Jaw Relation Record		24. <input type="checkbox"/> Radiographs		25. <input type="checkbox"/> Other (See remarks)	
26. Clinician's Remarks/Instructions							
27. Typed Name and Grade of Dental Officer				28. Signature			
DD FORM 2322 83 OCT				S/M 0102-LF-002-3220		DENTAL LABORATORY WORK AUTHORIZATION	

LABORATORY DATA								
1. Name of Dental Laboratory								
2. Date Received	3. Date Completed	4. Teeth, Facings or Pontics						
		Location	Tooth Nos.	Shade	Guide	Mold		
		Max Ant						
		Max Post						
		Men Ant						
		Men Post						
5. Articulator		6. Metals Voucher No:						
Number and Settings		Metals Used		Out		In		
		Type	DWT	GR	DWT	GR	DWT	GR
7. Laboratory Remarks, Instructions, or Consultation Report								
8. Typed Name and Grade of Laboratory Officer				9. Signature				

Figure 8-42.—Dental Laboratory Work Authorization, DD Form 2322 (Front and back).

DTB20842



DTB20843

Figure 8-43.—Basic instrument tray setup for prosthodontic treatment.

dentist record the information in block #13 of DD Form 2322.

### Preparation

The primary purpose of the initial tooth or teeth preparation appointment is to remove tooth structure, and provide adequate space for the crown or bridge being made. The initial preparation of the tooth is accomplished with a tapered diamond bur in an ultra-speed handpiece. The dentist must reduce the tooth for the crown or bridge so that it is thick enough to provide for an adequate amount of strength, without increasing the size of the tooth. The basic procedures of tooth or teeth preparation you will assist in are:

- If the tooth or teeth have not been endodontically treated, the dentist will administer dental anesthesia.

- Isolate the working area by using cotton rolls and retract the cheek, lips or tongue, and evacuate debris during the removal of tooth structure.

- Assist in placing gingival retraction cord when the dentist creates the margin of the preparation so as not to damage the supporting structures of the free gingival margin. The dentist may have you take a piece of retraction cord and place it in a hemostatic agent that assist with control of hemorrhage.

- The cord is placed into the gingival crevice with a flat-bladed instrument (fig. 8-44) and then the end of the cord is cut and the preparation finalized.

### Final Impression

After the dentist is satisfied with the preparation, you will prepare the materials for the final impression. A custom tray has usually been fabricated for this appointment. Preparation for the tray impression



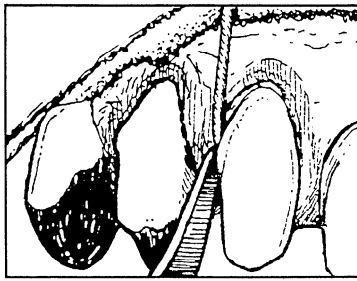


Figure 8-44.—Placing gingival retraction cord into gingival crevice.

actually begins during tooth preparation at the stage when the gingival area is isolated with retraction cord. A properly positioned cord serves two functions:

- It displaces the free gingiva for completing the tooth preparation.
- It opens the gingival sulcus for the impression.

Before you prepare the impression materials, you must paint the custom tray with a tray adhesive that is compatible with the impression material. Be sure to accomplish this well in advance to allow the adhesive to set.

At this stage, one end of the cord should protrude from the sulcus so it can be easily grasped with cotton forceps for removal before injecting the impression material into the gingival sulcus. Additional preparation of the mouth for the impression includes, irrigation, aspiration, and isolation of the preparation site with clean dry cotton rolls.

The impression materials that the dentist will select for use may be light-cured, or supplied as a two-paste base and catalyst system that is mixed in equal length. Some manufacturers market the two-paste impression materials in a manner that eliminates the need to manually mix the material. These materials are mixed using a gun-like dispenser, which is loaded with twin tubes of catalyst and base. Whatever material the dentist chooses, always refer to the manufacturer's instructions to mix the material.

Usually, impression material of two different viscosities (bodies) are used. You will prepare **regular-bodied** material and load it into the custom tray, and also prepare a **light-bodied** material and load it into a syringe (if not using the gun-like dispenser method). As the retraction cord is removed, the dentist injects the light-bodied material around the sulcus of each individual tooth preparation. During this procedure, you assist with retraction of the lip, cheeks and/or tongue, and have the impression filled custom

tray ready for insertion. Once the dentist seats the tray, you will place a saliva ejector in the patient's mouth to remove excess saliva while the impression material sets. Once set, the dentist removes the impression and inspects it for quality. Allow you patient to rinse with water, and provide a hand mirror and tissue to allow them to clean excess material from the face. Before you take the impression to the laboratory, be sure to disinfect it according to current infection control standards.

### Bite Registration

The dentist may determine that an accurate bite registration is necessary to establish the proper occlusal relationship during mounting. A bite registration can be made in many ways. Some of the common methods use reinforced bite registration wax, or dental stone mixed with slurry water (water from model trimmer).

### Interim (Temporary) Crown or FPD

The last step in this appointment is that a temporary crown or FPD must be made to cover and protect the prepared tooth or teeth while the permanent prosthesis is being fabricated. To protect tooth sensitivity, the temporary should extend to the margin of the tooth preparation but not beyond it. A temporary that extends beyond the margin into the gingival tissues will become an irritant to the tissue. A properly constructed temporary will have the following characteristics:

- Smooth and polished so it does not irritate the tongue, lips, cheeks, or gingival tissues.
- Provides the appropriate occlusal form and relationship to any opposed teeth.
- Provides appropriate proximal contact relationships with unprepared adjacent teeth to prevent drifting.
- Provides acceptable esthetics if placed in an anterior area.

Temporary crowns or FPD's can be constructed from preformed acrylic resin and aluminum shells. Plastic stints and alginate impressions can also be used with self-curing acrylic resin to make an interim prosthesis.

When the temporary is finished, a temporary cement such as zinc oxide and eugenol is used to deliver the interim restoration onto the prepared tooth or teeth. Consult the manufacturer's instructions for

proper mixing of the material. After the temporary cement has set, use the mirror and explorer to gently remove all excess cement from the crown and gingival area. Check the patient's occlusion again and allow you patient to rinse his/her mouth with water to remove any debris or loosened excess cement.

At the end of this appointment, make arrangements for future visits before dismissal of the patient. Be sure to annotate the DD Form 2322 with the date, time, and step of the next treatment planned. This information is essential to the dental laboratory for fabrication of the requested work.

## INSERTION OF FIXED PROSTHETICS

The basic steps involved in inserting crowns and fixed FPDs are the same. Your instrument tray setup for insertion is the same as shown in figure 8-43. You will need to include assorted stones and burs for adjustment of the prosthesis. Usually, local anesthesia is not required since most patients can tolerate the minimal discomfort associated with the insertion of the prosthesis. The basic steps in delivery of the final prostesis include removal of the temporary, try-in and adjustment, stain and glaze, and permanent cementation.

### Removal of the Temporary

The removal of the temporary is usually delegated to the dental assistant. Do this gently since your patient usually does not have anesthesia and may experience some slight sensitivity. Use the following steps when removing a temporary:

1. Use an instrument, such as a stellite, to loosen the temporary bond at the margin of the temporary.
2. Once removed, clean any debris or retained temporary cement on the tooth or teeth with a cotton pellet and cotton forceps.

### Try-In

One of the first steps in the try-in of the prosthesis is the adjustment of the proximal contacts. Proximal contacts between adjacent teeth should exist, but be nonwedging. The proper amount of contact exists when there is a slight snap of dental floss as the dentist passes it through the contact areas. The dentist will check other aspects of the prosthesis as follows:

- Ensures the prosthesis is fully seated.

- Evaluates the pontic adaptation visually, and then passes dental floss between the pontic tip and the tissue ridge to ensure very little, if any, pressure is on the residual ridge mucosa.

- Uses articulating paper to mark any areas of interference between the prosthesis and the opposing teeth, and then reduces them with dental stones and burs in a dental handpiece.

If the prosthesis is completely metal, any surface roughness resulting in clinical adjustments is eliminated, and the metal is highly polished before cementation.

### Stain and Glaze

If the prosthesis involves porcelain, the dentist will stain and glaze the porcelain to characterize the porcelain for maximum esthetics. Unstained and unglazed porcelain is referred to as being in a *bisque bake* state. Before the prosthesis can be cemented, it must be returned to the laboratory to fire the stain and glazed porcelain. After glazing, the laboratory will highly polish the exposed metal of the prosthesis. The prosthesis is now ready for cementation.

### Cementing the Prosthesis

The final step in this appointment is the cementing of the prosthesis. The treatment site must be kept clean and dry throughout the procedure.

Zinc phosphate ( $ZnPO_4$ ) and glass ionomer cement have been recognized as excellent permanent cementing agents for fixed prosthetics.  $ZnPO_4$ , however, is highly acidic during the initial setting stage because of the presence of phosphoric acid. Therefore,  $ZnPO_4$  can be quite irritating to the pulp tissues if the cementation process is not handled properly. Some dentist prefer to coat the preparation with copalite varnish before cementation with  $ZnPO_4$ . Other permanent cements such as reinforced Zinc oxide and Eugenol (ZOE), ethoxybenzoic acid (EBA), and polycarboxylate (PCA) cements are less irritating to the pulp tissues, but have not proved to be clinically superior to glass ionomer as a permanent cement. You must follow the manufacturer's instructions for dispensing and mixing the particular cement selected.

To accomplish cementation of FPD, perform the following steps A through C shown in figure 8-45:

1. Isolate the treatment site with clean, dry cotton rolls, and gently dry the prepared tooth or teeth with a gentle blast of warm air or cotton pellet (step A).

2. Prepare the cement according to the manufacturer's instructions.

3. Carefully place mixed cement into each retainer or crown in a manner that eliminates the possibility of trapped air.

4. The dentist seats the prosthesis over the prepared tooth or teeth and applies firm finger pressure with a cotton roll to the occlusal or incisal surface to express the excess cement (step B).

5. For posterior areas, the patient is instructed to bite firmly into balsa wood, orange wood stick, or a cotton roll that is placed over the prosthesis for the final seating.

6. While the cement is still fluid, the dentist uses a sharp explorer tip to examine the marginal fit and verify the seating of the completed restoration.

7. Place a saliva ejector in the patient's mouth to ensure the area remains dry while the cement sets.

8. Do not attempt to remove excess cement until it has set to the point of being "brittle-hard".

9. When hard, use an instrument such as a periodontal curette, to remove all cement from around the restoration, tooth, and the gingival sulcus area (step C).

10. Gently floss the area, irrigate, and evacuate the area to ensure it is clean.

Before dismissing patients with fixed prosthetics, instruct them in procedures for cleaning the restorations.

## REMOVABLE PARTIAL DENTURES

Some of the basic procedures for RPDs are the same as FPDs, but require much more laboratory and appointment sittings. The following is a typical treatment plan you may be involved with if assisting with the fabrication of an RPD. Each bullet represents a scheduled appointment.

- Prosthetic examination and alginate impressions for study casts.
- Mouth preparations for RPD framework and final impressions.
- Framework try-in and adjustment.
- Final impression of edentulous ridges for fabrication of the acrylic denture base, occlusal registration, and denture tooth selection.

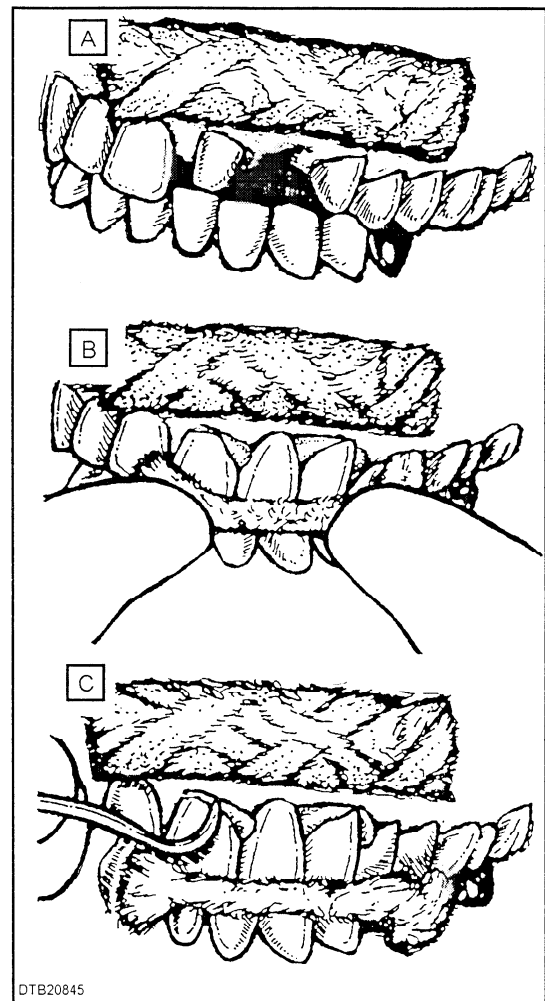


Figure 8-45.—Steps in cementing a permanent FPD.

- Deliver RPD and make initial adjustments as necessary.
- Follow-up adjustment RPD appointments as required.

## COMPLETE DENTURES

As with FPDs and RPDs, many of the basic procedures are the same. With increased public awareness on proper oral hygiene, personnel who require complete dentures are becoming a very small population of the armed services. The procedures that you will assist in are interocclusal registration, tooth and tooth shade selection, tooth arrangement, impressions, and CD delivery.

### STANDARD OPERATING PROCEDURES PROSTHETICS LABORATORY

As a chairside prosthetic assistant, you must become familiar with the procedures of the prosthetic

laboratory. If you do not know these procedures, patient cases can be lost or routed improperly. If you have any questions about different procedures, ask the dentist or prosthetic technician.

## **CASE REQUESTS**

Cases entering the laboratory are required to be accompanied with a work authorization request (DD Form 2322). Requests are to be filled out with instructions, signed by the requesting doctor, and must indicate desired completion date. The case is then entered into the Prosthetic Log and assigned a case number. This entry must be made by the person delivering the case to the laboratory.

## **IMPRESSIONS**

Before entering the laboratory ALL impressions are to be sprayed with an approved disinfectant in accordance with BUMEDINST. 6610.10, chapter 6, and covered with a plastic wrap (head rest covers work great). The laboratory technician is to be informed of the arrival of the impressions.

### **Alginate Impressions**

Alginate impressions are to be placed into the tray holder at the plaster bench to prevent distortion of the impression (a moist paper towel should be placed over the impression to prevent dehydration of the material).

### **Final Impressions**

This includes complete dentures, removable partial dentures, crowns, and bridges. These impressions are poured as prescribed by the doctor; if no instructions are provided, they will be poured with stone mixed with liquid stone hardener.

### **Study Casts**

Study casts are fabricated for diagnostic purposes and poured as prescribed by the doctor. If no instructions are provided, they will be poured in plaster.

## **STONE OR PLASTER CASTS**

Trim the casts once they are separated from the tray. Casts are trimmed to remove excess material by use of the model trimmer.

- You are required to don protective ear and eyewear.

- Turn on water supply to desired flow.
- Activate the model trimmer.

Trimmed casts will be rinsed, dried, and marked with the patient's last name and case number (if space is available). The case will then be routed according to the work authorization request.

## **CASES WHILE IN THE LABORATORY**

Casts will be kept in case pans, protected in plastic (when available). Case pans will be labeled with patient's name, doctor, date started, and prosthesis being fabricated.

Pumice and polishing procedures for the fabrication of new prostheses will not require special precautions. Repairs, relines, rebases, or adjustments of any prosthesis that has had contact with patient's body fluids are considered old cases and will require precautions. Lathe instructions for pumice and polishing are as follows:

- The technician is required to ensure correct placement of the protective shield is in the down position before activating the lathe.
- Pumice is to be replaced after each use.
- Wheels/brushes used for pumice and polishing are to be removed from machine and sent to CSR.
- Prostheses should be put into a glass beaker or ziplock bag containing cleaning solution, then placed into ultrasonic.

### **Ultrasonic Cleaner**

The prosthetic ultrasonic cleaning machine is the same as the CSRs except that dental prostheses are run through. The following are guidelines for its use:

- Ultrasonic to contain water approximately 1 to 1-1/2 inches. Special solutions to be used in ziplock bags or glass beakers.
- General-purpose cleaner or stone and plaster remover solutions can be reused when used on new cases. Once solution is used for an old case, the solution is to be discarded.
- Stain and tarter solution is used for old cases and will be used one time then discarded.

Once the ultrasonic cleaning procedure is completed, the prosthesis is then brushed and rinsed with water. It is then bagged and replaced into the assigned case pan.

## **Completed Cases**

The work authorization request will be closed out in the Prosthetic Log by entering the date of completion. This is done by the delivering dentist or the technician. The work authorization request will be retained in the laboratory for two years. The case pan and its contents will be placed on the plaster bench for cleaning. Cleaning includes the emptying of used models and the spraying down of the case pan.

## **GUIDELINES FOR INFECTION CONTROL IN THE DENTAL LABORATORY**

When you are working in the prosthetic department or the laboratory, infection control is still a major concern. Follow BUMEDINST 6600.10, *Dental Infection Control Program*, for complete guidance and instructions. Prostheses or impressions may carry a multitude of bacteria in dental plaque, blood, or saliva. To protect everyone from cross contamination and possible infection, dental personnel must use proper techniques for disinfection of material before sending it to the laboratory from the DTR and vice versa.

### **BARRIER CONTROL**

Place barriers wherever possible to prevent cross contamination. Establish a designated area in the dental laboratory where technicians disinfect all incoming and outgoing items.

### **DTR INFECTION CONTROL**

Wipe contaminated shade guides, face-bows, articulators, and alcohol torches with an

EPA-registered disinfectant. Also disinfect pliers and other special instruments after each use, even if they do not come in contact with blood or saliva. An alternate method is immersing the instruments in an EPA-registered intermediate or high-level disinfectant such as iodophor or 2 percent glutaraldehyde.

### **Instrument Sets**

When possible, use trays to allow sterilization or disinfection of multiple instruments.

### **Unit Dose Concept**

Use of the unit dose concept prevents contamination of bulk supplies. Dispense enough to complete the entire procedure when using such items as petroleum jelly, impression materials, waxes, pressure disclosing or indicator paste, disposable brushes, and orthodontic brackets and wires.

### **Processing and Transfer to the Laboratory**

When possible, rinse and disinfect impressions, prostheses, and intraoral devices before transfer to the laboratory to reduce chances of cross contamination. If the integrity of the item or material is compromised by this disinfection, a waiver should be requested through the command on the item (for example, porcelain-stained crown before bake). Place casts and prostheses in self-sealing plastic bags to prevent contact with adjacent materials, the shipping box, foam insulation, or paper work. Consider everything returned from a dental laboratory as contaminated. The receiving facility must disinfect these items.



## CHAPTER 9

# DENTAL TREATMENT ROOM EMERGENCIES

### INTRODUCTION

Medical emergencies can and do occur in dental clinics. They can be life threatening as a result of a medical condition or an accident (e.g., chemicals or scrap amalgam getting in eyes). Most accidents are preventable if you observe and follow safety procedures. All dental patients must wear approved safety glasses with side shields. Also, passing of instruments and medications over a patient's face, should be avoided to prevent injuries. The dental officer will always be in charge of an emergency. As a dental assistant, you must know how to react and treat the injured until the medical department arrives and assumes responsibility. Since each command may have slightly different equipment and procedures, you should become familiar with these emergency procedures as soon as possible.

### PREVENTING MEDICAL EMERGENCY SITUATIONS

The best means of handling medical emergencies is to take every precaution to prevent them. Precautions taken in the dental treatment room or facility include: close review of the Dental Health Questionnaire, checking a patient's vital signs, and knowledge and use of emergency equipment.

### VITAL SIGNS

The physical condition of a patient can be determined by checking the following vital signs: body temperature, pulse, blood pressure, and respiratory rate.

#### Body Temperature

An adult's normal body temperature may range from 97°F to 99°F (36.1°C to 37.2°C). A person with a body temperature above 99°F has a fever, and a person with a body temperature below 97°F has a subnormal temperature. Most dental clinics commonly use an electronic thermometer that displays body temperature as numbers in a digital display. It uses a disposable plastic cover that goes over the temperature probe and is placed under the tongue. Always discard the plastic cover after

each use. Follow the manufacturer's instructions for use and maintenance.

#### Pulse

As the heart pumps blood through the arteries, they expand and contract, producing a regular heart beat or pulsation. The number of beats per minute is the pulse rate. For adults, a normal pulse rate ranges from 60 to 80 beats per minute; for a child, it ranges from 80 to 110 beats per minute.

Normal site for taking the pulse is the carotid artery, located on either side of the neck (fig. 9-1). You should **always** check the carotid pulse on the same side that you are on. **Never** reach across a patient's larynx. To locate the carotid pulse, slide your index and middle fingers into the groove between the trachea and the muscles at the side of the neck where the carotid pulse can be felt. **Do not** use your thumb because it has a



DTV2f901

Figure 9-1.—Locating the carotid pulse.

pulse of its own and will confuse your counting. To determine the pulse, once you feel the artery beating, count the beats for 30 seconds, multiply by 2, and then record the results.

If you notice any irregularity, take the patient's pulse again. This time, however, count the beats for a full minute. If the pulse is still irregular in rate or rhythm, inform the dental officer.

The other common site for taking the pulse is the radial artery on the thumb side of either wrist (fig. 9-2). If you are taking the pulse at the radial artery, have the patient place his arm in a relaxed position on the arm of the dental chair. Lightly rest your index and middle finger on the patient's radial artery to determine pulse.

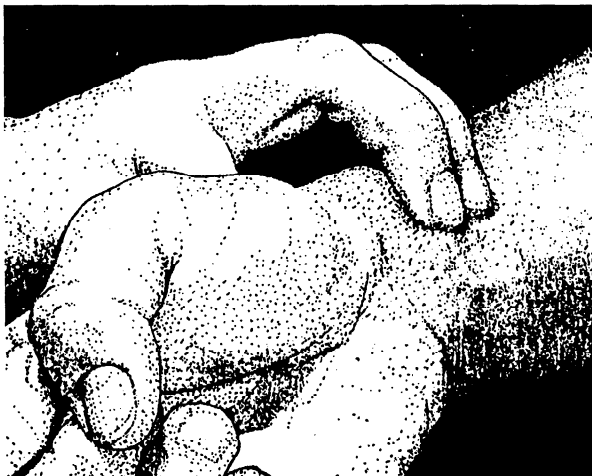
### Blood Pressure

Blood pressure is the force that the blood exerts against the walls of the arteries as it flows through the arterial system.

The maximum blood pressure occurs when the heart contracts. This is referred to as the **systolic pressure**. Normal blood pressure range for the systolic reading for an adult is 90 to 140 millimeters of mercury (mm Hg).

The minimum blood pressure occurs when the heart relaxes. This is referred to as the **diastolic pressure**. Normal blood pressure range for the diastolic reading for an adult is 60 to 90 mm Hg.

Take the blood pressure of each patient over the age of 5 at the initial and annual examinations, or when directed by the dentist. Record the results on the



DTV2f902

Figure 9-2.—Taking the radial pulse.

patient's Dental Exam Form. An entry of 120/80 would indicate the systolic pressure is 120 mm Hg (millimeters of mercury) and the diastolic pressure is 80 mm Hg.

Blood pressure is measured with a sphygmomanometer and a stethoscope or an electronic unit that provides a digital reading. Follow manufacturers' instructions for use and maintenance of your particular equipment.

### Respiration

Respiration is the act of inhaling and exhaling. One inhalation and one exhalation is a complete cycle. The respiration rate for an adult may range from 12 to 15 cycles per minute; for a child the rate is 15 to 18 cycles per minute; and for an infant the rate is 18 to 20 cycles per minute.

Respiration can be controlled by the patient. To obtain an accurate respiration rate without the patient's knowledge, watch the chest rise and fall, and count the respirations.

### EMERGENCY RESPONSE TEAM

Your command will have an emergency response team that is appointed by the commanding officer or branch director. This team responds to all emergencies when called upon. It consists of at least one dental officer and two dental technicians. It is activated by the front desk personnel and announced over the clinic's loud speaker system. An example of this may be as follows: attention in the clinic, code blue in dental treatment room five. The front desk personnel should repeat this message twice. Your command instruction will have specific guidelines for announcing the emergency.

When activated the appointed dental officer goes directly to the emergency and the technicians appointed retrieve the medical emergency equipment and bring it to the scene. A mobile **crash cart** is brought to the emergency and will consist of an automated external defibrillator and emergency drugs. A portable unit of oxygen is also brought. The oxygen tank is an E size cylinder that provides approximately 78 liters of oxygen per minute for one-half hour. An extra cylinder should be standing by if needed. A clear oxygen mask or hand operated resuscitator will be attached to the oxygen unit.

Once the dental officer assesses the emergency, he may direct a member of the team to notify the front



desk to activate the medical clinic's emergency response team to take over the emergency. Dental personnel should be standing by at the entrance where medical personnel will arrive in order to direct them to the emergency.

Please note that not all dental commands have the same procedures as described above. You must read your own command's instruction on emergency medical procedures for your specific command.

### BASIC LIFE SUPPORT

Respiratory failure and cardiac arrest occur when a victim's heart suddenly stops beating, causing the blood to cease circulating.

A victim of respiratory and cardiac arrest must receive cardiopulmonary resuscitation (CPR) within 4 to 6 minutes after the heart stops beating. You must be able to recognize what is wrong and provide immediate emergency medical treatment including basic life support (BLS) until the medical department arrives. BLS is the attempt to restore lung and heart function. These procedures can be summarized in terms of the ABC's of basic life support. The primary emphasis is placed on maintaining an open **airway** to counter upper airway obstruction, restoring **breathing** to counter respiratory arrest, and restoring **circulation** by chest compressions to counter cardiac arrest.

### MEDICAL EMERGENCY GUIDELINES

The guidelines for medical emergencies are as follows:

- Get organized
- Remain calm
- Take charge of the situation
- Act quickly but efficiently
- Get assistance from other staff personnel so they can notify the emergency response team if needed
- Make a preliminary assessment of the victim's condition in the position you found him in if possible
- Determine the foremost life-threatening condition
- Maintain treatment until qualified assistance arrives

### CPR COURSE CERTIFICATIONS

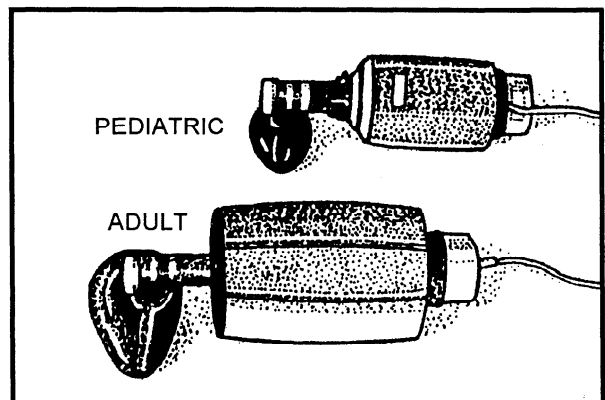
There are three types of CPR courses, each related directly to the curriculum:

- Heartsaver course—teaches learners in one-rescuer CPR, management of foreign-body airway obstruction, and the use of barrier devices for ventilation.
- Pediatric BLS course—teaches learners how to administer CPR and first aid for choking infants and children.
- Healthcare provider course—teaches healthcare professionals in one-rescuer CPR, management of foreign-body airway obstruction, two-rescuer CPR, the use of barrier devices, and (optionally) the use of an automated external defibrillator (AED).

All dentists, dental technicians, and auxiliary dental personnel must be certified in the healthcare provider course for BLS if directly involved with patient care.

### RESUSCITATING DEVICES

Among the standard emergency equipment in the DTR is the hand-operated resuscitator (fig. 9-3), also referred to as a bag-valve mask. It allows the operator to rescue breathe for the patient without mouth-to-mouth contact. This device consists of a face mask and an inflating bag joined by a valve. A connector at the end of the bag allows the resuscitator to be connected to an oxygen supply. The mask is clear so the operator can see the patient's mouth in case regurgitation occurs. If this happens, gently turn the patient's entire body on the right side, wipe out the mouth, return the body to its original position, and continue to rescue breathing with the hand-operated resuscitator.



DTV2f903

Figure 9-3.—Pediatric and adult resuscitators.

The resuscitator is very difficult to use. The primary problem is keeping an effective seal between the patient's face and the mask. Due to this, it is recommended that the resuscitator be used only when there are two rescuers available to operate the resuscitator. One to maintain an air tight seal while the other rescuer squeezes the bag.

## USE OF OXYGEN SUPPLY

At the dentist's direction you may hook up the resuscitator to an oxygen supply. Oxygen tanks are always painted **green**. Attach the oxygen hose from the oxygen bottle to the connector on the end of the resuscitator.

On the top of the oxygen tank is the cylinder valve. A yoke is used to attach the liter gauge and pressure gauge to the oxygen tank. When directed, turn the oxygen supply cylinder valve counterclockwise (fig. 9-4) until it is completely open. Next, turn the regulator control adjust handle clockwise until the proper flow rate in liters per minute is established on the liter gauge. The normal flow rate is 6 liters per minute. Once the oxygen is turned on, place the mask over the victim's nose and mouth. Pump the inflating bag once every 5 seconds for an adult, once every 4 seconds for a child, and once every 3 seconds for an infant.

**NOTE:** Oxygen in the atmosphere occurs in an approximate concentration of 21%, commercial oxygen is pure 100% oxygen.

## Safety Precautions

- Combustible materials must never come in contact with the oxygen cylinder
- No smoking in any area where there are oxygen cylinders or where oxygen is being administered
- Use only a properly fitting regulator valve
- Close all valves when the cylinder is not in use
- Secure cylinder(s) upright in a proper storage rack or carrier for transportation
- Always stand to the side of the cylinder

## OTHER MEDICAL EMERGENCIES

Other medical emergencies may occur in the dental operatory, X-ray, or even the reception area. You must always be prepared to recognize and treat these emergencies.

## ANGINA PECTORIS

Angina pectoris, also known as *angina*, occurs when there is a narrowing of the coronary arteries with decreased blood flow to the heart. The constriction of blood flow may cause the patient to experience similar signs associated with a heart attack such as pain radiating in the arms and chest. Some of the major causes are as follows:

- Extreme physical exertion
- Emotional stress

## Signs and Symptoms

- Pain from under the sternum
- Heavy feeling or pressure on the chest
- Burning feeling between the shoulder blades
- Cyanosis, shortness of breath
- Anxiety

## Treatment

- Place patient in a 45-degree angle (sitting up).
- Administer 100 percent oxygen and one nitroglycerin tablet sublingually (beneath the tongue).

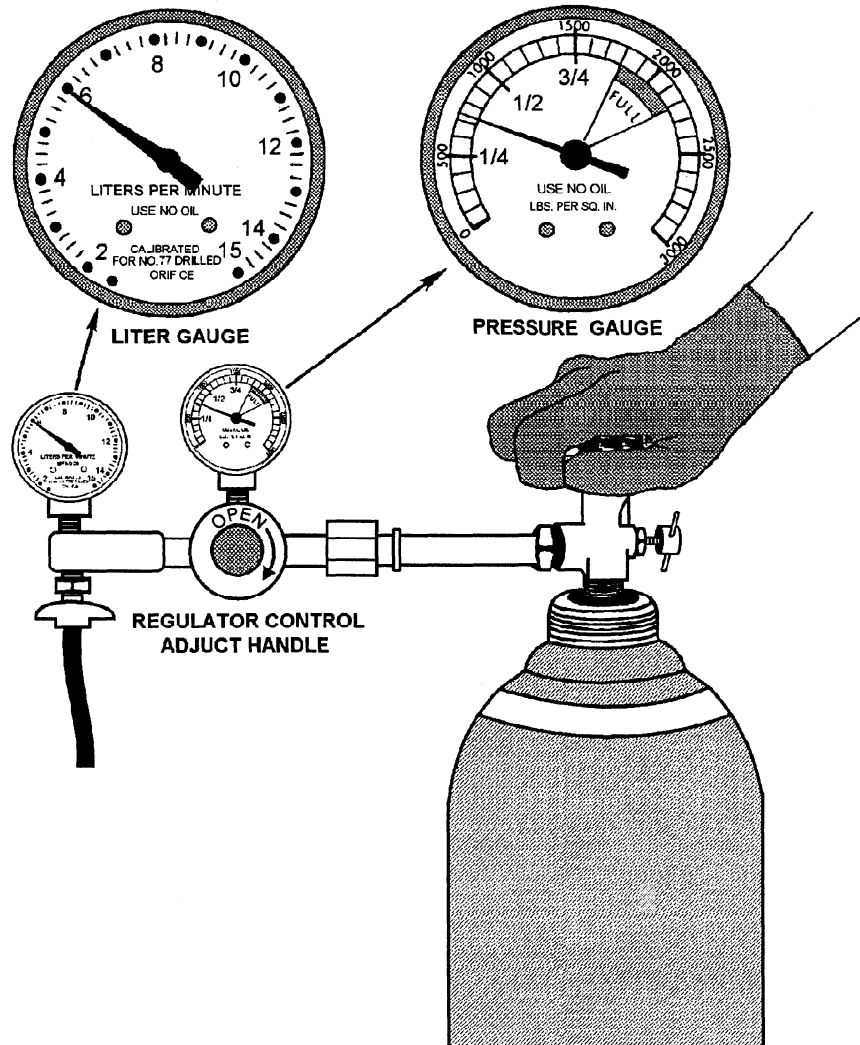
## NOTE

One additional sublingual nitroglycerin tablet or tranlingual spray dose may be repeated every five minutes until relief is obtained. If the pain persists after a total of three tablets of spray doses in a 15-minute period, the patient should be brought to medical for an evaluation by a medical officer. Also check to see if the patient is wearing a transdermal form of nitroglycerin. If they are, a second dose is **not usually** recommended unless prescribed by a medical or dental officer.

## SHOCK

*Shock* is a syndrome (a collection of symptoms) that results from a rapid decrease in blood circulation due to a loss of blood and/or vascular collapse, and from the body's attempt to compensate for these decreases. Some major causes of shock are as follows:

- Allergic reactions
- Severe or extensive injuries
- Bites or stings from poisonous snakes or insects



DTV21804

Figure 9-4.—Turning on cylinder valve.

- Severe pain or burns
- Loss of blood
- Digestion of poisons
- Exposure to extreme heat or cold
- Electrical shock
- Emotional stress
- Gas poisoning
- Certain illnesses

**Signs and Symptoms**

- Restlessness, anxiety, weakness, anxious or dull expression, and disorientation
- Weak, rapid pulse
- Shallow, irregular breathing

- Vacant, dull eyes with dilated pupils

**Treatment**

- Activate clinic’s emergency response team
- Lay the victim down
- Elevate the feet
- Keep victim warm
- Keep victim calm

Maintain an open airway

**SYNCOPE (FAINTING)**

*Syncope* is a self-correcting, temporary form of shock. Usually, the serious problems related to syncope are injuries that occur when falling down from the temporary loss of consciousness. Fainting may be caused by stressful situations. Dental patients who

experience this may tell you they feel weak and dizzy while getting out of the dental chair after a procedure. If a patient is still conscious, have him sit back in the dental chair and place him in the Trendelenburg's position (fig. 9-5). Place the patient in a position slightly lower than supine with feet elevated slightly above the head.

### Signs and Symptoms

- Weakness, dizziness, black spots in vision
- Pale face, blue lips
- Cold perspiration
- Rapid, weak pulse
- Shallow breathing

### Treatment

- Activate clinic's emergency response team if deemed needed by the dental officer
- Lay victim down
- Elevate feet (Trendelenburg style)
- Loosen tight clothing
- Maintain an open airway
- Use an ammonia ampule

### ANAPHYLACTIC SHOCK

Anaphylactic shock is the result of a severe allergic reaction. It is a life-threatening emergency and usually occurs within seconds after the victim is exposed.

### Signs and Symptoms

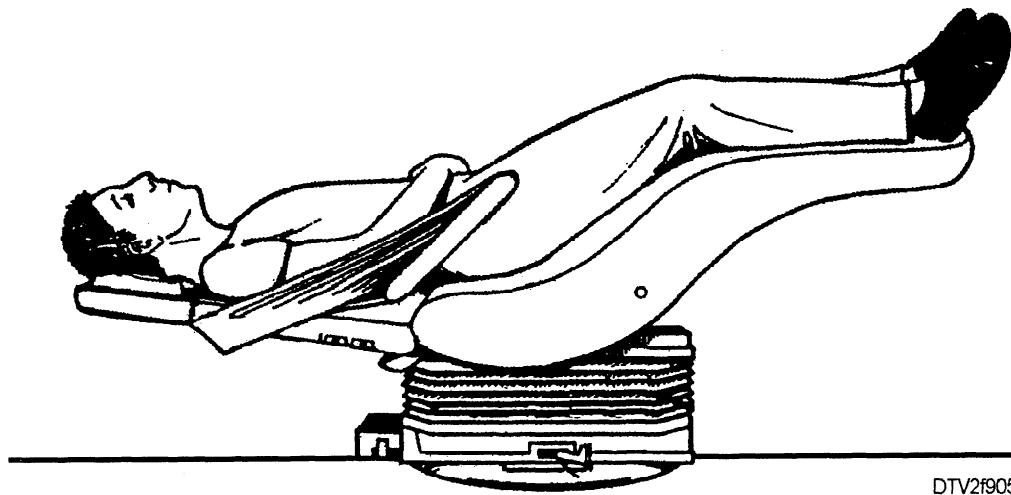
- Itching and burning of the skin with flushing
- Cyanosis around the lips
- Swelling of the face and tongue
- Paleness
- Swelling of the blood vessels just underneath the skin
- Weak, rapid pulse
- Low blood pressure
- Dizziness
- Restlessness
- Painful, squeezing sensation in the chest
- Difficulty breathing
- Respiratory wheezing
- Nausea, vomiting
- Abdominal cramps
- Diarrhea

### Treatment

Activate clinic's emergency response team. Provide treatment according to BLS procedures (including CPR).

### HYPOGLYCEMIA

Hypoglycemia is caused by low blood sugar in the body. Anyone can be affected by hypoglycemia. It can occur if a victim has not eaten for a long period of time,



DTV2f905

Figure 9-5.—Trendelenburg's position.

has overexerted themselves (such as overexercising), or has vomited. A victim can become unconscious—often referred to as insulin shock.

### **Signs and Symptoms**

- Extreme weakness
- Pale, moist skin
- Normal or shallow breathing
- Normal blood pressure
- Normal or rapid pulse
- Double vision
- Apathy and irritability
- Drooling
- Tingling and numbness in fingers or feet
- Dizziness
- Headaches
- Fainting
- Profuse sweating
- Eventual unconsciousness and coma

### **Treatment**

- If severe, or victim is unconscious, activate the clinic's emergency response team
- Never give an unconscious victim oral liquids
- If the victim is conscious, give the victim a drink of (soda or presweetened juice) or a piece of candy containing sugar
- If the victim is unconscious, place a sugar cube under the tongue

### **HYPERVENTILATION**

*Hyperventilation* is an abnormal respiratory condition where the victim overbreathes or breathes too rapidly. This condition usually occurs when apprehensive patients breathe more rapidly in response to their own anxiety.

### **Signs and Symptoms**

- Anxiety, nervousness, fear
- Dizziness or lightheadedness
- Blurred vision
- Dryness or bitterness of the mouth

- Tingling of the hands, feet, or area around the mouth
- Tightness or a lump in the throat
- Shortness of breath
- Pounding feeling of the heart (tachycardia)
- Tired or weak
- Feeling of impending doom
- Rapid breathing
- Fainting

### **Treatment**

- Calm the victim and provide reassurance
- Try to get the victim to slow his breathing down
- Place a paper bag over the victim's mouth and nose

### **ASTHMA ATTACKS**

*Asthma* attacks interfere with normal breathing and occur when the airways constrict making the patient produce a wheezing sound as he or she breathes. A patient who has been diagnosed as having asthma, will usually carry an inhaler containing medication to treat their mild attacks.

### **Signs and Symptoms**

- Difficulty in breathing
- Wheezing, gasping sounds when attempting to breathe
- Coughing spasmodically and unproductively
- Cyanosis

### **Treatment**

- Sit the victim down
- Calm and reassure the victim
- If the victim carries medication, help him take the medication
- Activate clinic's emergency response team if needed

### **SEIZURES**

In a conscious, healthy individual, muscular movements are usually smooth and coordinated. If the

normal functions of the brain are upset by injury, infection, or disease, the electrical activity of the brain can become irregular. This irregularity can bring about sudden uncontrolled muscular contractions known as seizures.

### **Signs and Symptoms**

- Body becomes rigid and then jerks violently
- Jaw clamped shut
- Foaming at the mouth
- Loss of consciousness

### **Treatment**

- Activate clinic's emergency response team
- Lay the victim down
- Loosen or remove tight clothing
- Turn victim on her side with the head extended and face turned slightly downward
- Maintain airway
- Do not restrain the victim unless she is in immediate danger

- After the seizure is over, reassure and reorient the victim and allow her to rest

### **DUTIES DURING ADMINISTRATION OF MEDICATION**

After the patient has been anesthetized or premeditated with a drug, you should observe the patient to ensure that the drug is working and be watching for signs of an adverse reaction. Never leave a patient alone that has been anesthetized or premeditated with a drug.

### **SIGNS AND SYMPTOMS OF ADVERSE REACTION**

- Raised, hive-like patches with severe itching  
Wheezing, difficulty in breathing  
Nausea, vomiting

### **TREATMENT**

if necessary administer basic life support and activate clinic's emergency response team immediately.

## CHAPTER 10

# FORENSIC DENTISTRY

### INTRODUCTION

*Forensic dentistry* may be defined as that branch of forensic medicine that applies dental knowledge to civil and criminal problems. The military simply expands this definition to include the unique needs of the military services. While it is true that our primary mission is to support requests for aid in forensic dental identification, you must understand that dental identification is only one of a number of major areas in forensic dentistry. These include: dental identification, bite mark analysis, human abuse and neglect, dental malpractice and negligence, and dental anthropology and archaeology.

As a basic dental assistant, your primary duties will be assisting dental officers and civilian dentists with the dental identification section in forensic dentistry when directed. The other major areas in forensic dentistry will not be covered in this book because they pertain mainly to dental officers and dentists.

### PURPOSE

The primary reason we in the Navy have been directed to establish a forensic dental identification (ID) capability is to assure our ability to assist in the ID of human remains. In most cases this means identifying members of the Armed Forces, but occasionally it may include civilians. We are tasked to do this to meet both the civilian needs and the unique military needs for positive ID of individuals. The first four of these needs are common to both the military and civilian communities and include estate, insurance, legal, and psychological considerations. The last two needs are military considerations and include manpower and intelligence needs.

### ESTATE

Positive ID is necessary to allow probate of the last will and testament and transfer of any inheritance to the deceased's next of kin. Without positive ID, this process could be delayed until the person is declared legally dead, or up to 7 years.

### INSURANCE

Positive ID also is necessary to allow survivors to properly claim any life insurance held by the victim. Again, if a positive ID is not accomplished, the payment of insurance to the beneficiaries could be delayed for years. This would defeat the purpose for buying the policy in the first place and could deny any survivors the funds needed to adjust to the loss of the provider's income.

### LEGAL

A less common but important consideration is the possibility of legal action such as malpractice or wrongful death litigation. Obviously, it would be very difficult, if not impossible, to prove wrongful death in a court of law if one cannot prove that an individual is dead. This would not only eliminate any possibility for compensation for loss of a loved one, but also could affect the legal handling of the deceased's estate as well as payment of any life insurance benefits.

### PSYCHOLOGICAL

The last of the common needs is the psychological aspect of an individual's death. The loss of a loved one is frequently psychologically devastating to those left behind. In fact, many persons are not able to accept the death of their child, parent, or spouse until long after the occasion. Not knowing positively their loved one is dead complicates this process leading to false hopes and preventing the survivors from getting on with their lives. A graphic example of this was the tremendous agony experienced by the next of kin of our Vietnam missing in action.

### MANPOWER

Simply stated, you need to know who the casualties are so you can rapidly replace them. If we do not know who the Sailors are, it will be impossible to replace them with persons of similar training and skills in their areas of expertise to restore full combat readiness.

## INTELLIGENCE

You also must know the location and condition of our personnel familiar with sensitive operational information. If a Sailor who knows the details of an upcoming operation is missing, you need to know whether he is wounded, dead, or captured, and if the operation plans have been compromised.

## OTHER METHODS OF IDENTIFICATION

Now that we have established the purpose for forensic dental identification and explained why we have been tasked to do so, we need to look at why dental techniques have become so important in forensic identification operations. To do this we need to look at some of the other different methods of forensic identification. Various methods of ID have been used depending on the individual situation.

### Body Characteristics

Many body characteristics can be used to identify an individual. Recognition includes using visual, scars, deformities, and tattoos methodologies.

- **Visual recognition**—this is the most common method. It is reserved for instances in which no real

doubt exists about the identity of the individual and death did not occur under unusual circumstances. Its drawbacks occur when changes in appearance because of illness, fire, water immersion, or decomposition make ID quite difficult. Figures 10-1 and 10-2 show soft tissue trauma from fire and water. Visual recognition, therefore, is considered an unreliable means of identification in medico-legal death investigation and not usually acceptable as positive proof on the identity of the deceased individual.

- **Scars**—this method is useful in some cases. Surgical scars are probably the most commonly found but are of the least value since they are seldom distinctive. Like visual recognition, scars can change or be destroyed by the same processes affecting visual recognition.

- **Deformities**—may be either soft tissue alterations or because of bony abnormalities. Radiographs of the deformity on file in the medical record can be useful in the ID process. The bony deformity must be significantly distinctive, however, to be of value as a means of ID.

- **Tattoos**—can assist in the identification process. Figure 10-3 shows a tattoo on an arm. Multiple tattoos would increase the likelihood of positive

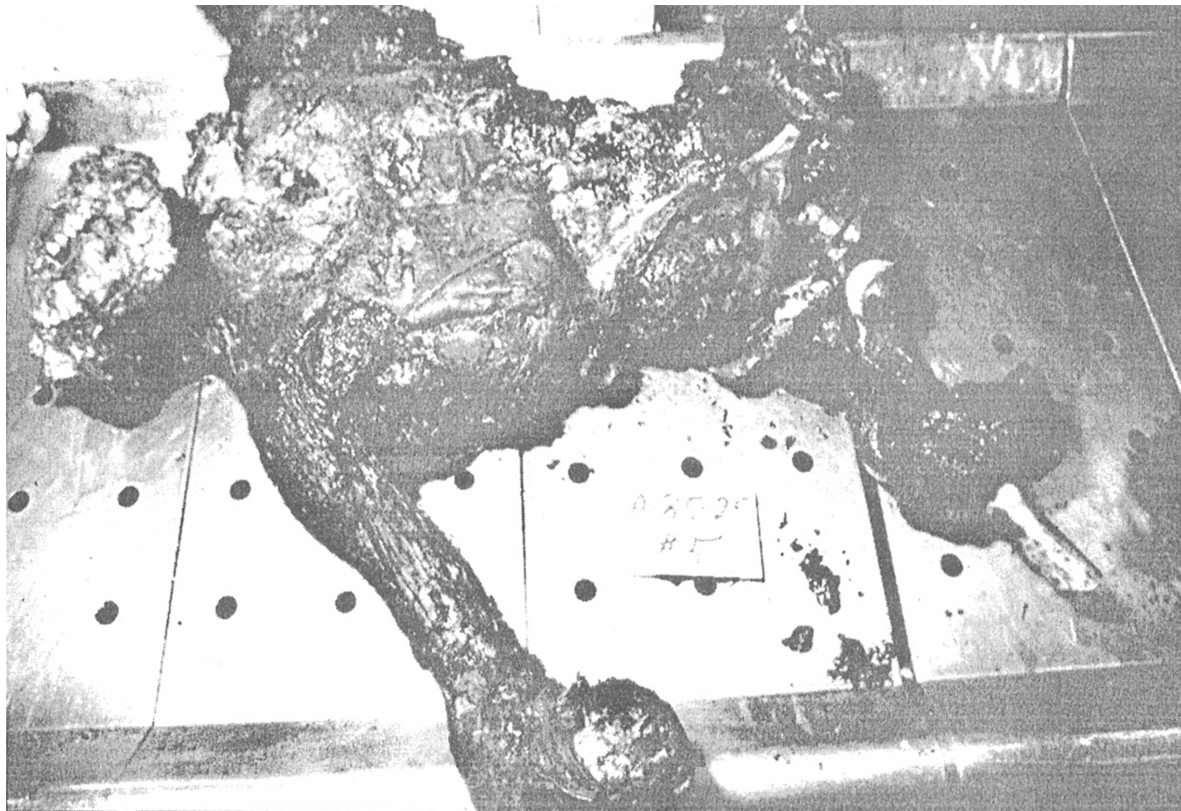
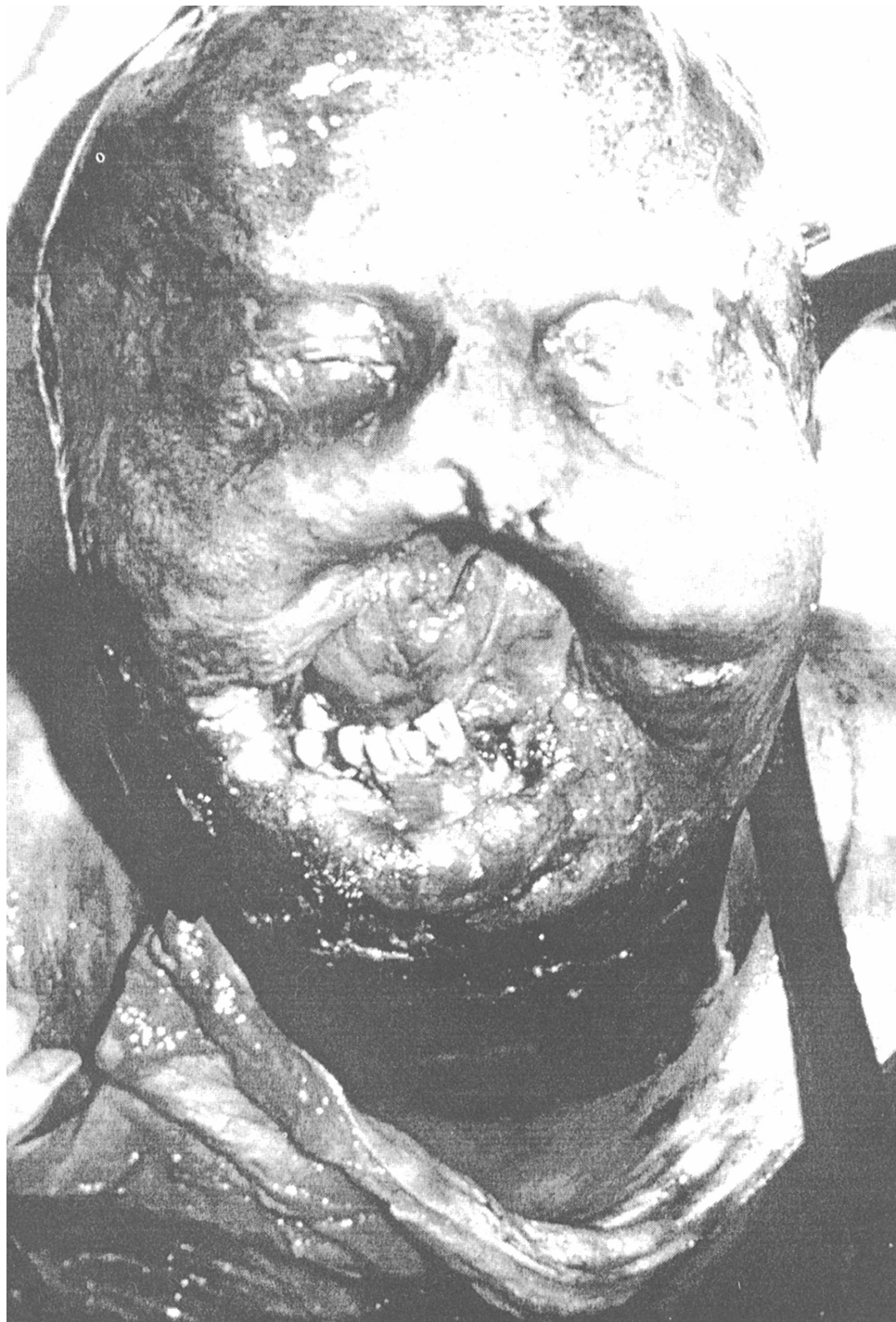

Figure 10-1. Charred remains from fire.





**Figure 10-2.—Remains from immersion in water for two weeks.**

identification. Again tattoos are soft tissue evidence and therefore are prone to easy destruction by environmental effect. For many reasons, tattoos should be used only as a secondary means to a positive ID.

### **Personal Effects**

Personal effects may include anything that is found on the body of the deceased that can be used to

assist in establishing the identity of the individual. Drivers' licenses, credit cards, ID cards, ID badges, and passports are just a few such items. In the military, dog tags are used specifically for this purpose. Other examples of personnel effects that may be helpful in establishing an identity include name tags sewn into clothing, distinctive jewelry, inscribed jewelry, and family photographs. Personal effects, however, are the



Figure 10-3.—Tattoo on an arm.

least reliable means of establishing an identity. They are not a physical part of the body, and, therefore, they may easily be transferred from one individual to another. In addition, lost or stolen items, and jewelry in particular, are very likely to be found in the possession of an individual other than its owner. Falsified documents may be found improperly identifying an individual as someone else. In most instances, the identity established by the personal effects will prove to be the actual identity of the deceased, but this must still be verified by a more objective, definitive means of ID.

### **Skeletal Remains**

Identification by skeletal remains may be an excellent means to identify an unknown individual. In some cases, it can provide positive proof of identity that is acceptable in a court of law. Identification by skeletal remains requires matching of postmortem radiographs with radiographs that were taken before death. Features that can be used for ID by skeletal remains would include healed fracture sites, pathologic lesions, and medical hardware.

The main problem with ID by skeletal remains is the fact too few individuals in the general population have such characteristics. This makes it difficult to rely on as a routine method of ID of an unknown body.

### **Fingerprints**

Of all the methods of ID, fingerprints are probably the **best known**. Fingerprints are an excellent means of positive ID. Figure 10-4 demonstrates a fingerprinting technique used by the FBI. Many individuals will argue that fingerprint ID is the most definitive means of identifying an unknown set of human remains, and it is generally accepted that no two individuals have the same set of fingerprints. Fingerprint ID, therefore, is always acceptable in a court of law.

### **DNA Analysis**

DNA analysis, also known as DNA fingerprinting, is a fairly new technology that may replace dental identification and fingerprint identification as the most definitive means of identifying unknown remains. It will be fully implemented when an adequate database of DNA specimens can be established.

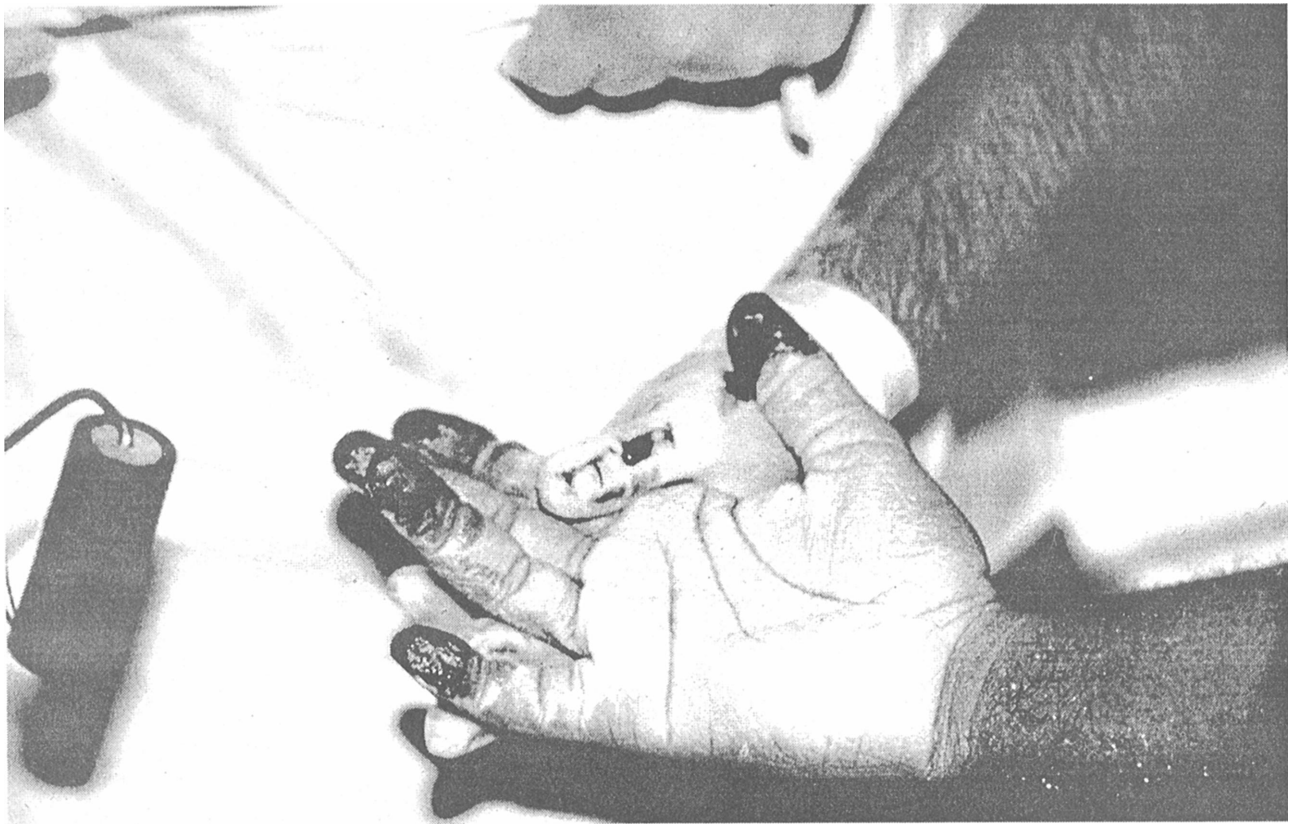

Figure 10-4.—Fingerprinting

## DENTAL IDENTIFICATION

Dental ID, like fingerprint ID, is a definitive means of positive identification of unknown human remains. It also is routinely acceptable as evidence in court. It has several significant advantages, and only a few disadvantages when compared with fingerprint identification. The bulk of the remaining chapter will center on dental ID.

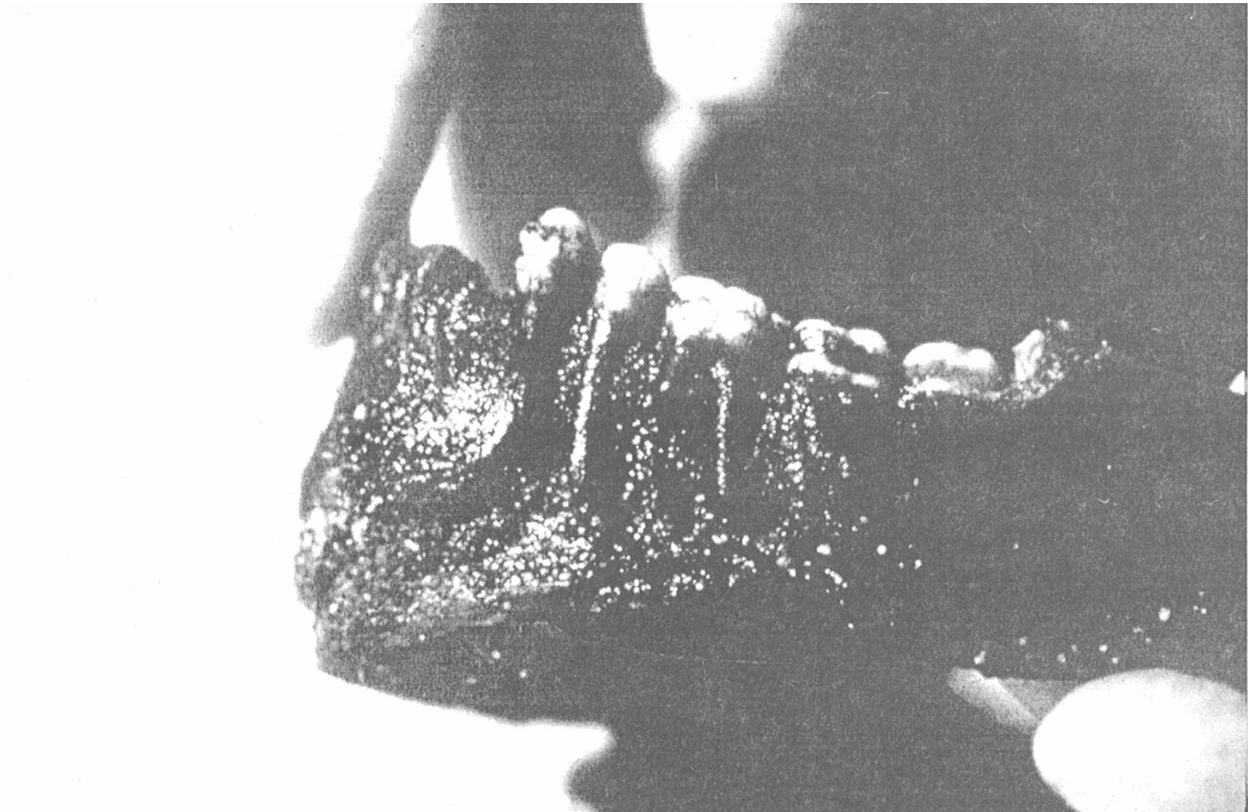### WHY DENTAL IDENTIFICATION WORKS

Dental evidence tends to survive much better than does soft tissue evidence such as facial characteristics or fingerprints. Teeth are calcified structures and are the hardest substance in the human body, even harder than bone. Because they are calcified, they are resistant to the environmental effects that destroy soft tissue evidence. Thus teeth are not destroyed by immersion in water, by desiccation (drying up), or by decomposition. Even in cases of skeletalization of remains, teeth are available for ID purposes. In addition, teeth are relatively resistant to destruction by fire. However, teeth can be destroyed in rare instances by heat if the temperatures are greater than 1000°F and the teeth are unprotected by the soft tissues of the cheeks and lips. Figure 10-5 shows intact dentition of a

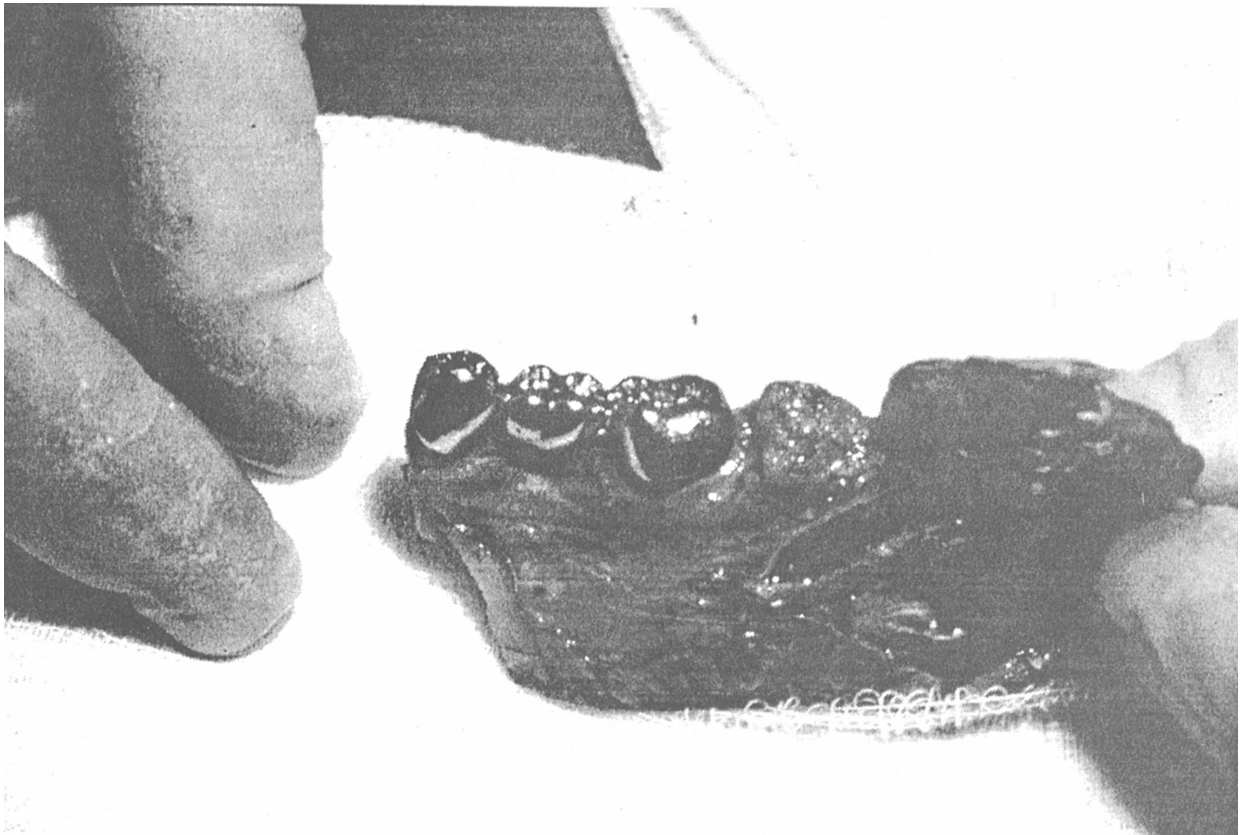
charred mandible. Teeth are further protected by the soft tissue mass of the tongue. The roots of the teeth are encased in the alveolar bone, providing an additional layer of protection. Therefore, even in fires where temperatures approach 1600°F, teeth are ordinarily found intact within the oral cavity and can be used for ID when all other means have been destroyed. In addition to the teeth, the materials used for dental restorations are also resistant to destruction by the environment, even more so than the natural teeth themselves. Gold alloys, as shown in figure 10-6, fused porcelain, synthetic porcelain, and porcelain denture teeth all will withstand temperatures exceeding 1600°F. Silver amalgam, the most commonly used restorative material, will resist temperatures up to 1600°F.

### Large Number of Potential Points of Comparison

The human dentition is composed of 32 teeth, each of which may be restored, unrestored, or missing. When restored, any of the 5 different surfaces may be involved in the restoration. The number of potentially different dental chartings, considering even one restorative material, is astronomically large ( $1 \times 10^{48}$ ). In addition to restorations, the tooth crown form, root



**Figure 10-5.—Charred teeth.**



**Figure 10-6.—Gold fixed partial denture from a fire.**

canal, and root form provide numerous other potential points of comparison that make each set of teeth unique. Therefore, it can be said with complete confidence that, given sufficient data, no two sets of teeth are identical.

### **Antemortem Database**

A decided advantage of dental ID over fingerprint ID is the relatively comprehensive nature of the antemortem database. An extremely high percentage of the general population has visited the dentist at some time in their life. Dentists routinely create dental records for these patients that detail the antemortem (before death) dental condition. These records are often maintained for long periods of time. Most importantly, dental radiographs are generated on almost every patient. Radiographs are hard evidence that is not subject to human error to the same extent that a written dental record might be. The radiographs also provide multiple additional potential points of comparison for establishing ID. With adequate dental records available to the forensic dentist, nearly 100% of unknown remains can be identified.

## **PROBLEMS IN DENTAL IDENTIFICATION**

The dentist and you, the Dental Technician, may encounter many problems with dental ID. These problems can waste numerous hours or days before the final determination of ID.

### **Illegible Dental Records**

Because in many cases the dental records are handwritten, the task of determining what treatment has been provided can be quite difficult.

### **Inadequate Dental Radiographs**

Radiographs may not be found useful for comparison purposes for a variety of reasons. Most often this is because of poor quality of the radiograph obscuring the features necessary for comparison. It may also be because of a lack of positioning of the radiograph or absence of a date on the radiograph.

### **Lack of Adequate Charting**

Many civilian dentists do not record the status of the dentition at the first appointment as required in the Navy. Pre-existing restorations, therefore, may not be

documented in the dental record, leading to confusion in the final analysis.

### **Lack of Uniformity of Charting and Numbering Systems**

Dentists might use multiple systems to record the treatment provided for a patient and to indicate which tooth was treated. Unless the forensic dental team is familiar with every possible charting and numbering system, a dental record may be unintelligible despite being legible. Luckily, most of the civilian and Navy dentists use a single system for charting and numbering teeth in the United States.

### **Changes in Dentition**

Teeth are not fixed in the jaws. Small changes in position are constantly occurring in addition to the normal functional wear produced by chewing. These changes are not distinct over a short period of time, but over an extended time period these small changes can accumulate to produce significant differences.

### **Human Error**

No matter how conscientious and persistent a dentist or Dental Technician might be about the accuracy of their dental records, errors in the written record will occur on occasion. This can cause discrepancies in the comparison and problems in establishing the ID.

## **PRINCIPLES OF DENTAL IDENTIFICATION**

The principles of dental ID are identical to those used in any other ID method. The postmortem (after death) remains are examined and documented, then the antemortem records are obtained and reviewed, and finally the two are compared to establish similarities and discrepancies. In evaluating the comparison, the forensic dental team looks first at discrepancies. Discrepancies are more important than similarities since a single discrepancy can negate a whole list of similarities. It is important for the dental team to consider the source of the discrepancy. If the discrepancy is found in the written dental record, it may be possible to explain it on the basis of human error. However, if the discrepancy is in a radiographic comparison, it is extremely difficult to ignore. Discrepancies may be classified into two broad categories, relative and absolute.

## Relative Discrepancies

These represent differences between the antemortem and the postmortem dental exam findings that can be explained by continued dental treatment. For example, an unrestored tooth may have been restored in the time interval between the last dental record entry and the death of the individual. Or, a small restoration may be enlarged because of additional decay. In any case, these discrepancies do not necessarily negate an identification if there are enough similarities in the remaining evidence.

## Absolute Inconsistencies

These represent differences between the antemortem records and the postmortem exam findings that are physically impossible and prove the remains cannot be those of the individual under consideration. For example, an unrestored tooth is found in the unknown remains. On examination of the antemortem records, however, the radiographs reveal the tooth in question had previously been restored. Since natural tooth structure can never be replaced once it has been restored, this finding would verify that the remains were not of those of the suspect individual.

Once discrepancies have been examined, the dental team will compare the number and degree of any similarities found in comparing the antemortem and postmortem records. No minimum number of similarities are required or accepted for positive ID. In many cases a judgment decision on the part of the examiner may be required regarding the certification of the ID.

## RADIOGRAPHIC COMPARISONS

At some point in the ID process, as shown in figure 10-7, the dental team will use dental radiographs and compare with the dental remains of the deceased. There are four categories in radiographic comparison.

### Exact Match

The postmortem radiographs show a restoration that in every respect is identical to a restoration in the same tooth in the antemortem radiographs as shown in figure 10-8. In some cases, the radiographs may be laid on top of each other to compare. Multiple distinctive points of comparison are normally documentable in a single restoration.



Figure 10-7.—Forensic dental team comparing dental remains with radiographs.

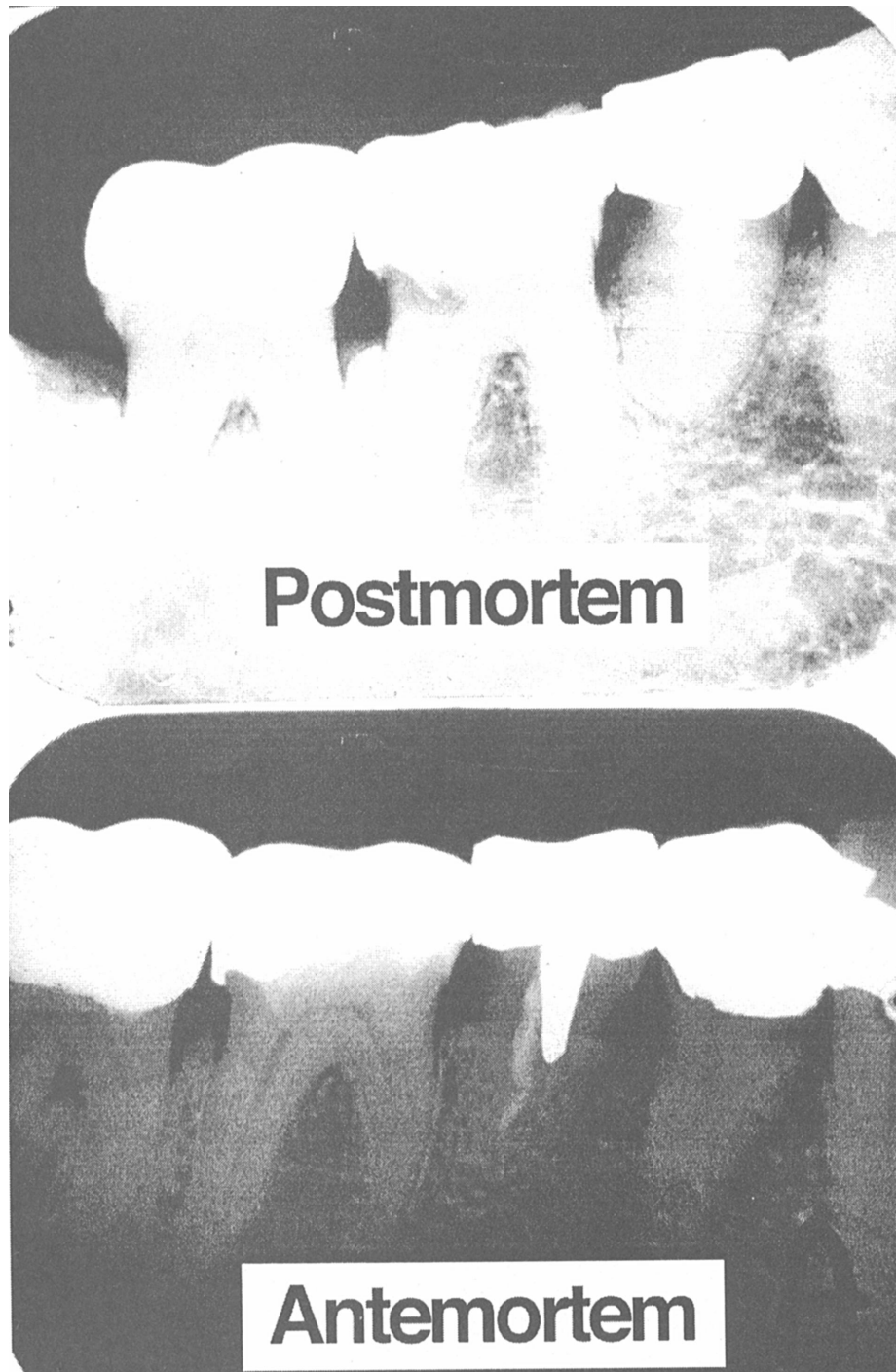


Figure 10-8.—Postmortem and antemortem exact match periapical X-ray.

### Similarity

The restoration in the postmortem radiographs is not identical to the restoration seen in the antemortem radiograph. The restorations occupy the same position in the tooth and many similarities in form are present, but there is no exact match. Similarities are caused by differences in the angulation at

which the antemortem and postmortem radiographs were exposed.

### Relative Discrepancy

A significant difference exists between the restorations in the antemortem and postmortem radiographs. Little or no similarity can be found

between them. However, the difference is explainable by continued treatment and no absolute inconsistency is present.

### **Absolute Inconsistency**

A significant difference between restorations or teeth in the antemortem and postmortem radiographs are presented that are not explainable by continued treatment. In fact, they are found to represent an impossibility in treatment.

## **CLASSIFICATION OF THE DENTAL IDENTIFICATION**

Classification is the last and most important step in the dental ID process. Five classifications can be used to establish identity.

### **Positive Identification**

The forensic dentist is positive they have determined the identity of the individual. Radiographic comparisons have been used in the ID process.

### **Positive Identification by Charting Only**

The forensic dentist feels confident in identifying the individual, but radiographic comparisons have not been used in the ID process. The ID is based solely on the written dental record. This category of ID leaves open the possibility that errors in the written dental record may be present and could affect the ID process.

### **Consistent With**

A good probability is the remains are those of the suspect individual. However, the findings are such that the forensic dentist is not confident enough to certify the remains. In this situation there is usually a deficiency in either the antemortem or postmortem evidence with which to make a comparison. It may also be because of a lack of similarities or because of the presence of too many discrepancies.

### **Exclusion**

Absolute inconsistencies are present. The remains cannot be those of the suspect individual.

## **Unidentified**

No sufficient evidence exists to determine the identity of the remains. While it could possibly be the suspect individual, it could just as easily not be the individual. Additional information, either antemortem or postmortem, is required before an identification can be established.

## **MANAGEMENT OF MASS CASUALTY OPERATIONS**

Although each mass casualty operation is unique in many ways, some basic principles are common to all such missions. First and foremost is recognition that these operations require a **team effort** by all participating parties. Figure 10-9 shows the forensic team receiving a victim to start the ID process.

While many specialty areas may be represented, all must work together and exchange information if the operation is to be a success. For our purposes, we will divide the participants into members of command/support elements or members of identification elements. The command/support elements consist of the following:

- Commander
- Public affairs
- Communications
- Registrar
- Data processing
- Security
- Facilities support
- Recovery/transportation
- Storage/handling
- Mortuary affairs
- Graves registration

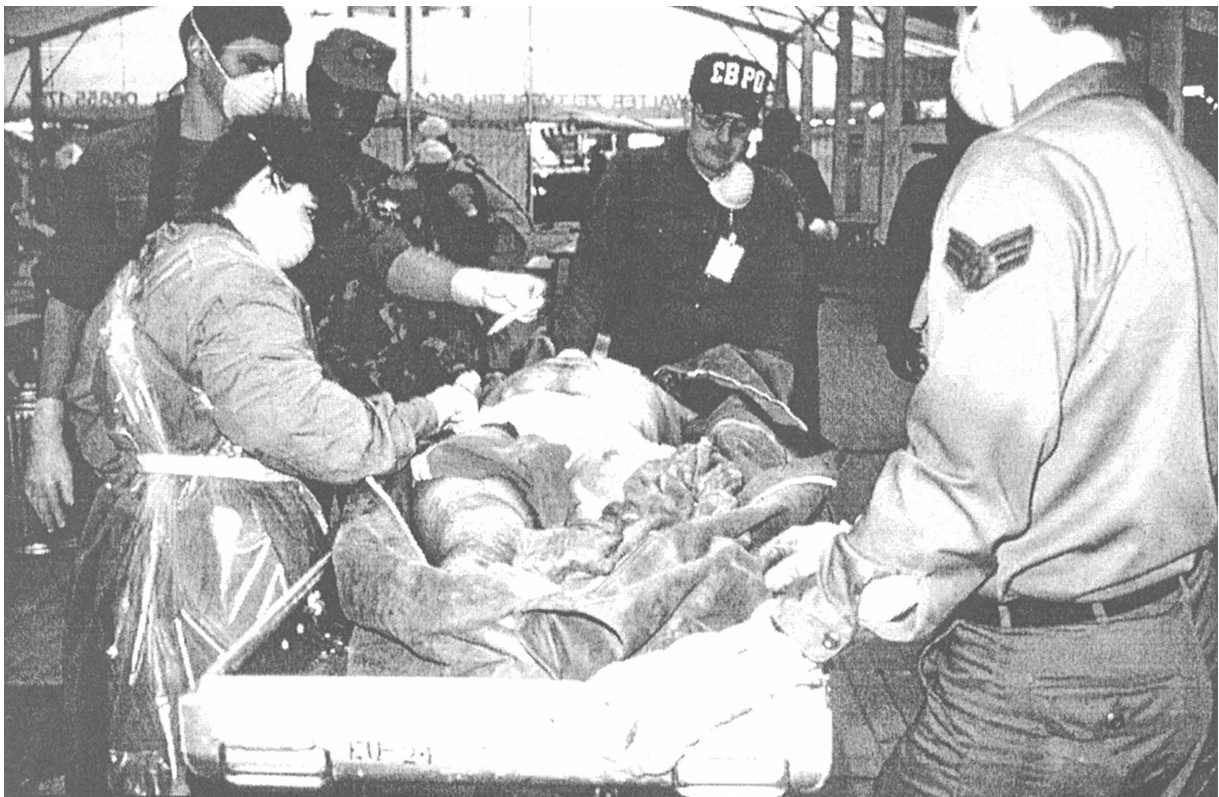The identification elements consist of the following:

- In processing
- Photographic
- Personal effects
- Finger/foot print
- Medical radiology
- Dental
- Medical exam/lab
- Anthropology
- Facial reconstruction

## **THE DENTAL TEAM IN MASS CASUALTY OPERATIONS**

Like the other elements of the operation, the different sections of the dental team work together with a common goal. The basic steps in forensic dental identification are (1) postmortem examination and





**Figure 10-9.—Receiving a victim.**

charting, (2) antemortem record acquisition and record reconstruction, and (3) antemortem and postmortem record comparison. The dental elements of the team are described next.

### **DENTAL TEAM LEADER**

The dental team leader (dental officer) performs the same tasks as the operations chief, only within the confines of the dental team. He brings back information to the dental sections and takes information to the operations commander and other members of the ID operation.

### **DENTAL REGISTRAR**

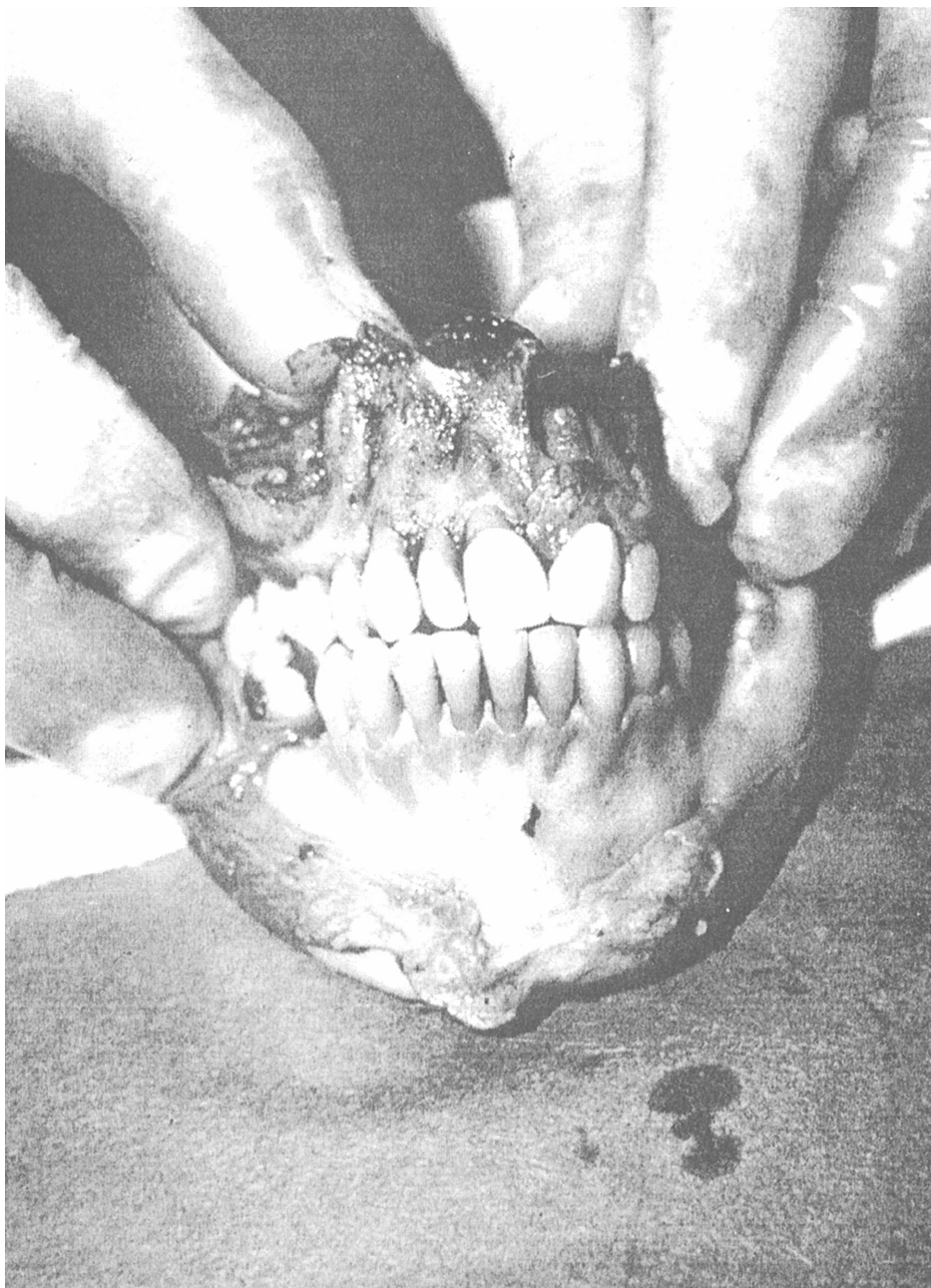
The registrar is one of the most important members of the dental element because he must control and protect all dental evidence coming into and going out of the dental area. He logs in and out all evidence, antemortem and postmortem, keeps track of workload figures (IDs per day, X-rays taken, photographs made, etc.), and coordinates with other areas of the operation to ensure that all potentially valuable sources of dental information are made available for review by the

dental officer or dentist. Figure 10-10 shows a dental registrar updating a forensic tracking board. He makes particular efforts to coordinate with personal effects, medical radiology, and medical examination sections and keeps the operations registrar updated with information the dental section needs. He also maintains and updates the dental exclusion matrix for use at the close of the operation.

### **ORAL SURGERY**

The surgeon's primary job, if needed, is to expose maxilla and mandible so that the postmortem examination team can examine and chart the dental arches. Figure 10-11 shows a maxilla and mandible that have been completely removed from a casualty. This is accomplished by removing tissue from around the oral cavity to expose the teeth, sectioning the ramus of the mandible and the pterygoid muscle to allow the release of the lower jaw. Also, making an incision in the floor of the mouth will release the mylohyoid muscle to ensure an accurate anatomical placement of the dental films. This is made by the Dental Technician who will take radiographs of the appropriate areas.





**Figure 10-11.—Exposed maxilla and mandible.**

### **Equipment**

In small operations with minimal number of remains to be processed, equipment is not a major consideration. However, as the number of remains increases, the availability of equipment becomes a major determining factor in the efficiency of the dental ID section. In situations where hundreds of remains require ID, you should have as many X-ray machines available as possible to speed up the initial processing of the remains. Postmortem radiographs are obtained

from regular floor-mounted, mobile endodontic, and portable military field types of dental X-ray units.

### **Exposure of Postmortem Radiographs**

The forensic X-ray section must realize that exposure of postmortem dental radiographs is the time limiting step for the dental ID section as a whole. It will normally require approximately 20 minutes to expose a complete series of postmortem radiographs. Therefore, a maximum of 3 sets of remains per hour can be processed with a single X-ray machine. Careful



**Figure 10-12.—Positioning dental fragment on X-ray film for exposure.**

planning is required to prevent confusion in the flow and tracking of the remains as they are processed.

The dental radiology section's job is to get, as nearly as possible, a full mouth series of periapical radiographs. On occasion, the forensic dentist may request occlusal and lateral jaw films. The proper technique to use is to expose the films in the proper anatomical orientation to prevent overlap, shorting, or elongation of exposed dental films. This is necessary because the postmortem films will be compared with the antemortem films that were exposed on a live patient using appropriate anatomical placement and angulation. Always expose a full mouth series using duplicate film packets even if areas appear edentulous or teeth are missing, fractured, or avulsed. Shoot different films at several angles and take care to expose all fragments in their proper anatomical orientation. It may not always be easy to take X-rays of teeth because postmortem dental remains may be fractured. The following supplies may be needed to assist you in exposing radiographs: hemostats, gauze, clay, and rope wax.

### **Developing**

Any X-ray developer can be used to process radiographs. The use of a daytime loader is

recommended to speed up the process. When multiple remains are being processed at the same time, the following procedures are normally prescribed.

- The entire series of postmortem radiographs is exposed before any has been developed.
- The series is placed into a labeled carrying container for transport to the developing area.
- Each series is developed at a single developing site or machine. Films from one series are never separated from one another for developing.

### **Mounting**

In forensic dental operations, it is not important which method is used for mounting periapical and bitewing X-rays, as long as the method selected is uniform. The raised dot on the film can be facing in or out. All postmortem radiographs should be mounted in the same manner so there will be no confusion by the examiners as to which side is which. The policy should be well publicized so that everyone working in the dental ID section, not just those in the dental radiology subsection, are aware of the standard.

**FILM ACCOUNTABILITY.**—One primary area of concern is the ability to determine, at any point

in time, if a film is missing from the film mount. This might occur because of its falling out of the mount or because an examiner has purposefully removed it for some reason. When dental evidence is incomplete and a complete series of postmortem radiographs has not been taken, there are two methods by which the examiners know for sure what films are available for their use. The first, and best method, is to fill all holes in the mount with undeveloped, unexposed film once all films from a set of remains are developed. An examiner who picks up a mount will immediately notice the green, opaque films in the mount and realize that no radiograph is available for this particular area. If an empty space is present in any of the mounting slots, the examiner immediately knows that a film was taken out of this site. The second method is to maintain a written inventory list of postmortem films exposed on each set of remains.

**ELIMINATION OF ERRORS.**—A routine mounting procedure is quite useful and involves taking the following actions:

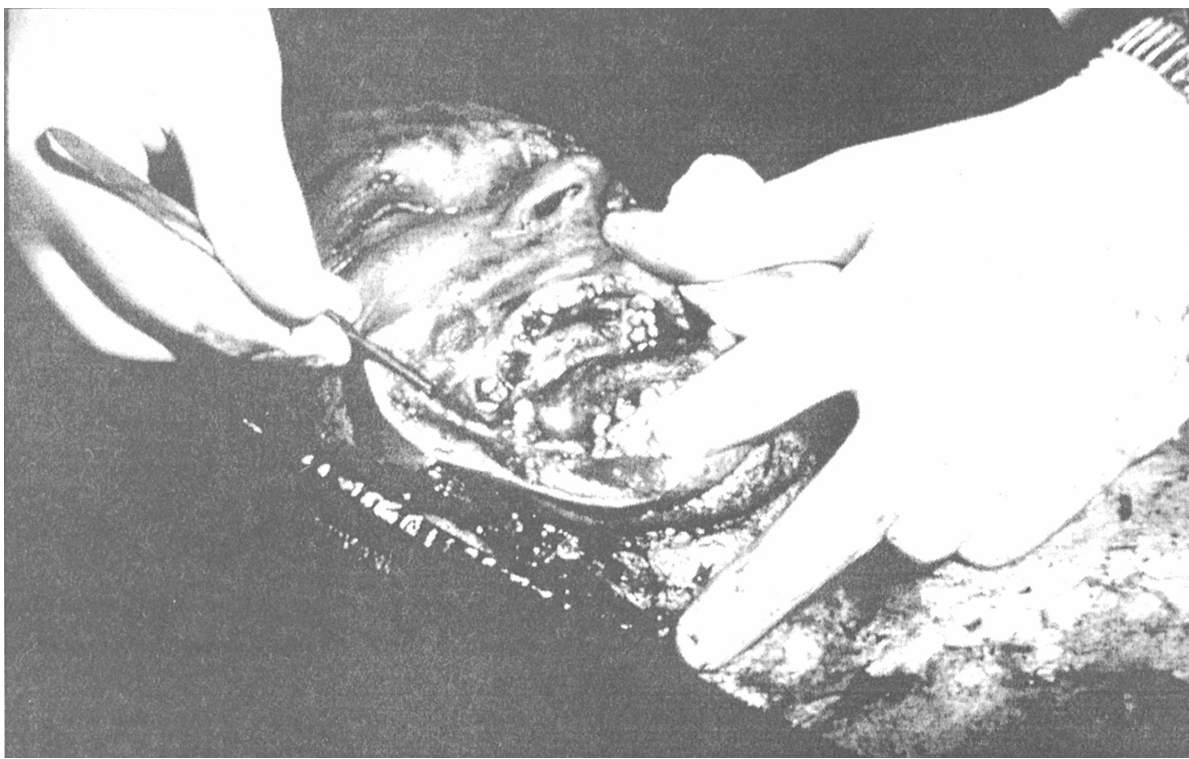
- Have one viewbox per developer and co-locate them so that loss of films in transport from developer to viewbox is not possible.
- Use viewboxes that can be laid flat to prevent dropping of films.

- Orient all dots in the correct position.
- Orient the entire series as it will appear in the mount before actually mounting any films.
- Remember whatever is in the center of the film determines its position in the mount.
- Have all series reviewed by a dental officer or a dentist at the postmortem examination station for correctness in mounting.

## DENTAL POSTMORTEM EXAMINATION

The postmortem examination team you may be on is responsible for examining and charting the dental remains to include the presence or absence of teeth, restorations, pathology, and any other feature that might be useful in the ID process. Figure 10-13 shows a forensic dental examination of a casualty.

The process starts with gentle cleaning of the dental remains with a tooth brush using sodium hypochlorite (bleach) and hydrogen peroxide. Remember that incinerated (burnt) teeth are brittle and will shatter if not handled carefully. Next, a team process including either a team of three dentists or a team of two dentists and a dental hygienist or a Dental Technician, chart all dental evidence on a postmortem dental record form. Figure 10-14 is an example of a completed postmortem dental record form.



**Figure 10-13.—Forensic dental examination.**

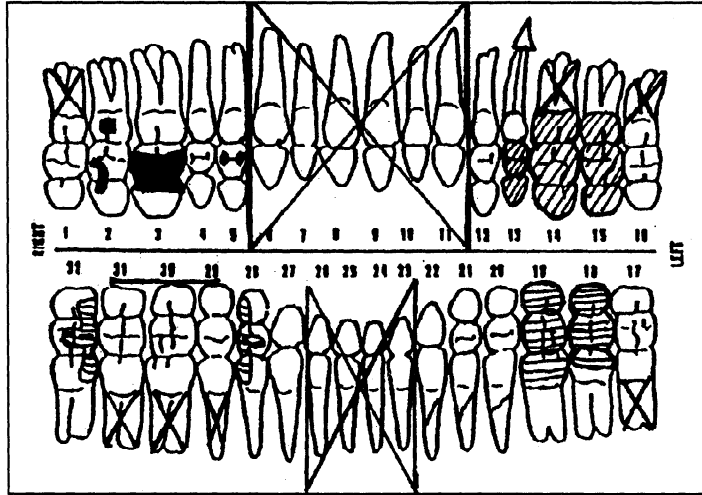
POSTMORTEM DENTAL RECORD

RECOVERY NUMBER A-97-3 EST. AGE: UNK RACE: UNK SEX: UNK DATE: 12 DEC 97  
 EXAMINERS: A. B. SMITH, CAPT, DC, USN PLACE OF EXAMINATION: NAVAL AIR  
P. T. BOATE, CDR, DC, USN STATION, PENSACOLA, FL

DESCRIPTION/COMPUTER CODES

1. X
2. OL-AM ; F-AM
3. MODL-AM
4. PN
5. O.O-AM
6. JM
7. JM
8. JM
9. JM
10. JM
11. JM
12. PN
13. FP-CV , RF-AP
14. FP-X
15. FP-CF
16. X
17. X
18. CP
19. CF
20. FX
21. FX
22. FX
23. TA
24. TA
25. TA
26. TA
27. PN
28. DOFL-GI
29. RP-X
30. RP-X
31. RP-X
32. MOFL-GI

RESTORATIONS & MISSING TEETH



CAPMI SYMBOLS

AM AMALGAM	CF CROWN FULL
GI GOLD INLAY	CP CROWN PARTIAL
GF GOLD FOIL	CV CROWN VENEER
SS ANY OTHER METAL REST	FP FIXED PARTIAL
CO COMPOSITE RESIN	RP REMOVABLE PARTIAL
JM JAW FRAGMENT MISSING	CD COMPLETE DENTURE
TA TRAUMATIC AVULSION	M MESIAL
FX FRACTURED CROWN	D DISTAL
RT ROOT TIP	O OCCLUSAL
PN PRESENT NOT RESTORED	I INCISAL
RO ROTATED	F FACIAL
RF ROOT CANAL FILLING	L LINGUAL
AP APICTECTOMY	C CARIES
IR INTERMEDIATE REST	U UNERUPTED
CT CROWN TEMPORARY	X EXTRACTED

REMARKS: BILATERAL MANDIBULAR TORI

DTV27014

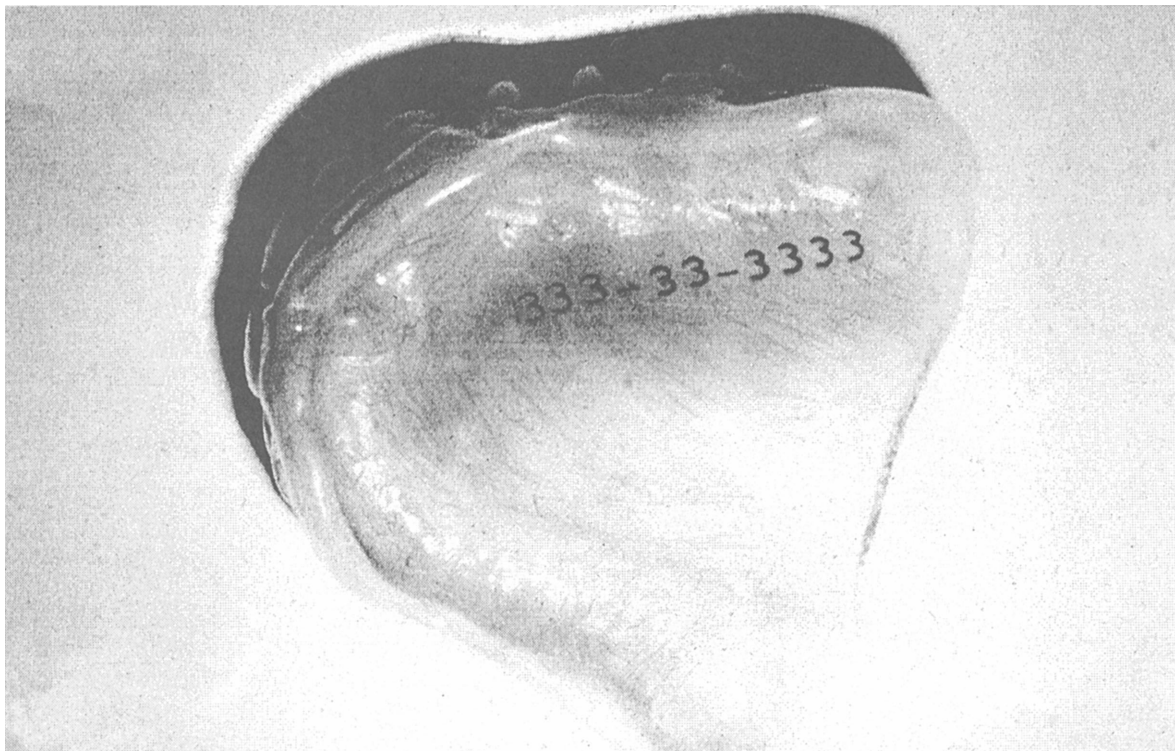
Figure 10-14.—Completed postmortem dental record form.

The entire dental team must agree to be consistent in charting methods. This is a slow process and much attention must be paid to details. Remember to check and double check each step. The team will decide which charting system they will use. The different branches of the service and civilian dentists all use different charting systems and abbreviations. The *Manual of the Medical Department*, chapter 6, describes the Navy's charting system and abbreviations used to complete all dental information for the different forms used in forensic dentistry. Other dental abbreviations used for charting, such as the Computer Assisted Postmortem Identification, may be used and will be covered later in this chapter under Computer Support. The use of a fiberoptic light is invaluable in the examination process. The examiner begins by evaluating tooth #1 and associated radiographs. The second dentist on the examination team evaluates tooth #1 and confirms the findings of the first dentist. The recorder charts the findings of tooth #1 and all three members confirm the charting. Tooth #2 is examined and the process is repeated until all 32 teeth have been charted. The approach is redundant, but errors are corrected as they are made. Charting should be done in pen, not pencil. Findings to

be recorded during the postmortem examination are as follows:

- Dental restorations
- Missing teeth
- Prosthetic appliances
- Pathology
- Unique anatomy
- Age estimate
- References to possible gender and racial group

Teeth missing because of the trauma of the mishap should be specifically noted to avoid confusion over extracted or congenitally missing teeth. A prosthodontist should be available to examine and describe dental prosthetic appliances. In some cases, the appliance may have been specifically marked for identification as shown in figure 10-15. It is wise to solicit from the victim's family study models or extra prosthetic appliances that may be available. Such evidence is important in providing antemortem data regarding ridge shape/size, rugae, and general oral anatomy. The antemortem dental record will be covered next.



**Figure 10-15.—Maxillary denture with SSN embedded in acrylic.**

## **ANTEMORTEM DENTAL EXAMINATION**

Another major section in forensic dentistry involves the antemortem dental record examination. Dentists, hygienists, and Dental Technicians can effectively operate this section. The task of this section will always be the most difficult in the entire forensic dentistry arena. They will be required to determine who was involved in the disaster, locate and procure all military or civilian dental records and radiographs, arrange for the delivery of these materials, and undertake the process of developing a composite antemortem record for each victim for the evidence supplied. You may not have all existing antemortem dental records for the victim from outside sources. This may lead to discrepancies in the antemortem record and postmortem record comparison. The quality, quantity, and variety of dental record documentation of this antemortem evidence present the major obstacles in this section. Clearly, all antemortem evidence must be compiled to a single antemortem dental record form as shown in figure 10-16, to provide a composite antemortem picture. The latter (computer/description codes column) may be easily compared to the postmortem findings recorded on a postmortem dental record of similar format. Comparing dental records sent directly from dental offices with a postmortem record is a near impossible task. At least two members of the antemortem dental record staff should review each composite antemortem dental record as a quality control mechanism. Figure 10-17 shows a dental staff reviewing antemortem dental records. The completed antemortem composite form should also be quality checked against antemortem dental radiographs.

### **COMPUTER SUPPORT**

In this day of data management and word processing, computers can now play a major role in forensic dental ID. The software we use is called the Computer Assisted Postmortem Identification (CAPMI) referenced in figure 10-18.

The basic principle is one in which antemortem and postmortem databases are built using the information charted on the antemortem and postmortem forms. These two databases are run against each other and the possibilities of matches are ranked to produce a most likely identities list. This list is then used by the forensic team to assist in the final ID process. The list does not make an ID, but merely minimizes the number of records that must be

compared manually by the team. The advantage is that, instead of having to look at every record to make a comparison, the dental officer or dentist who is reviewing the record is initially guided to the most likely match. This is tremendously efficient and offers a significant savings in time. CAPMI may be installed either on a portable or desktop computer. Your command can obtain copies of CAPMI software and instructions free of charge by writing to the following address:

The Director  
Armed Forces Institute of Pathology  
Attn: AFIP-AMS  
14th & Alaska Ave, NW  
Washington, DC 30306-6000

### **ANTEMORTEM/POSTMORTEM RECORDS COMPARISON**

The last section in the dental forensic ID process compares the antemortem and postmortem records. Here the results of all previous work are seen. Armed with the antemortem record and radiographs, postmortem record and radiographs, CAPMI printout (if used), and a summary sheet, the forensic team starts the process of comparing records and films. The size of the section is dependent on the number of fatalities, since there is a requirement to place all postmortem dental records face-up on tables in numerical order for a comparison with the antemortem composite dental records, as shown in figure 10-19.

After all postmortem dental records have been placed as described, the staff can systematically compare- the antemortem dental composite records as they are received with the postmortem dental records placed on the table. This is done by hand carrying the composite antemortem record and walking alongside the tables viewing the postmortem dental records looking for a significant point of comparison, such as a crown on tooth #30. Once significant points of comparison are noted between the antemortem and postmortem dental record forms, the radiographs of the respective records can be reviewed and a possible match established. Figure 10-20 shows dental team members reviewing radiographs.

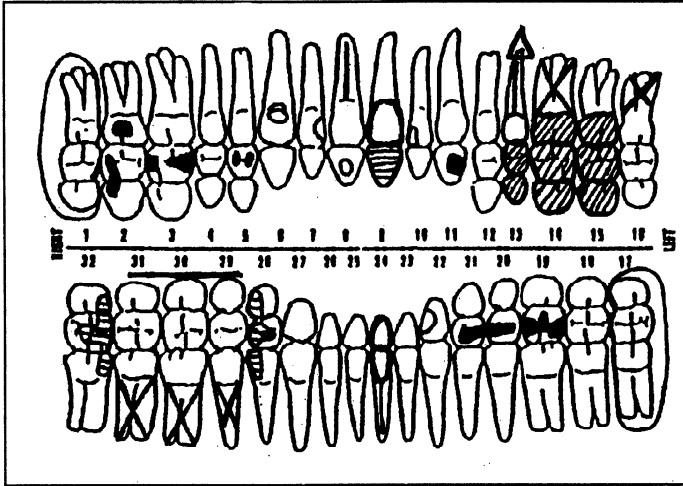
If it is possible to determine the gender of the disaster victims, it is possible to reduce the manual comparison task by placing the postmortem records in



# ANTEMORTEM DENTAL RECORD

NAME: FROST, JACK, R SSN: 333-33-3333 RANK: LT, USN  
 SEX: M RACE: C AGE: 31 XRAY TYPE & DATE: B/W 10/97 Pano 01/96  
 EXAMINERS: A.B. SMITH, CAPT, DC, USN DATE RECONSTRUCTED: 12 DEC 97  
P.T. BOATE, CDR, DC, USN RECORD SUPPLIED BY: NDC PENSACOLA FL

## RESTORATIONS & MISSING TEETH



## DESCRIPTION/COMPUTER CODES

1. U
2. OL-AM, F-AM
3. MO-AM, DO-AM
4. PN
5. O.O-AM
6. F-CO
7. M-CO
8. L-IR, RF
9. CV
10. MI-CO
11. D-AM
12. PN
13. FP-CV, RF-AP
14. FP-X
15. FP-CF
16. X
17. U
18. MODL-C
19. MOD-AM
20. MO-AM
21. DO-AM
22. ML-CO
23. PN
24. CT-RF
25. PN
26. PN
27. PN
28. DOFL-GI
29. RP-X
30. RP-X
31. RP-X
32. MOFL-GI

AM AMALGAM	CF CROWN FULL
GI GOLD INLAY	CP CROWN PARTIAL
GF GOLD FOIL	CV CROWN VENEER
SS ANY OTHER METAL REST	FP FIXED PARTIAL
CO COMPOSITE RESIN	RP REMOVABLE PARTIAL
JM JAW FRAGMENT MISSING	CD COMPLETE DENTURE
TA TRAUMATIC AVULSION	M MESIAL
FX FRACTURED CROWN	D DISTAL
RT ROOT TIP	O OCCLUSAL
PN PRESENT NOT RESTORED	I INCISAL
RO ROTATED	F FACIAL
RF ROOT CANAL FILLING	L LINGUAL
AP APICOECTOMY	C CARIES
IR INTERMEDIATE REST	U UNERUPTED
CT CROWN TEMPORARY	X EXTRACTED

REMARKS: BILATERAL MANDIBULAR TORI

DTV21016

Figure 10-16.—Completed antemortem dental record form.



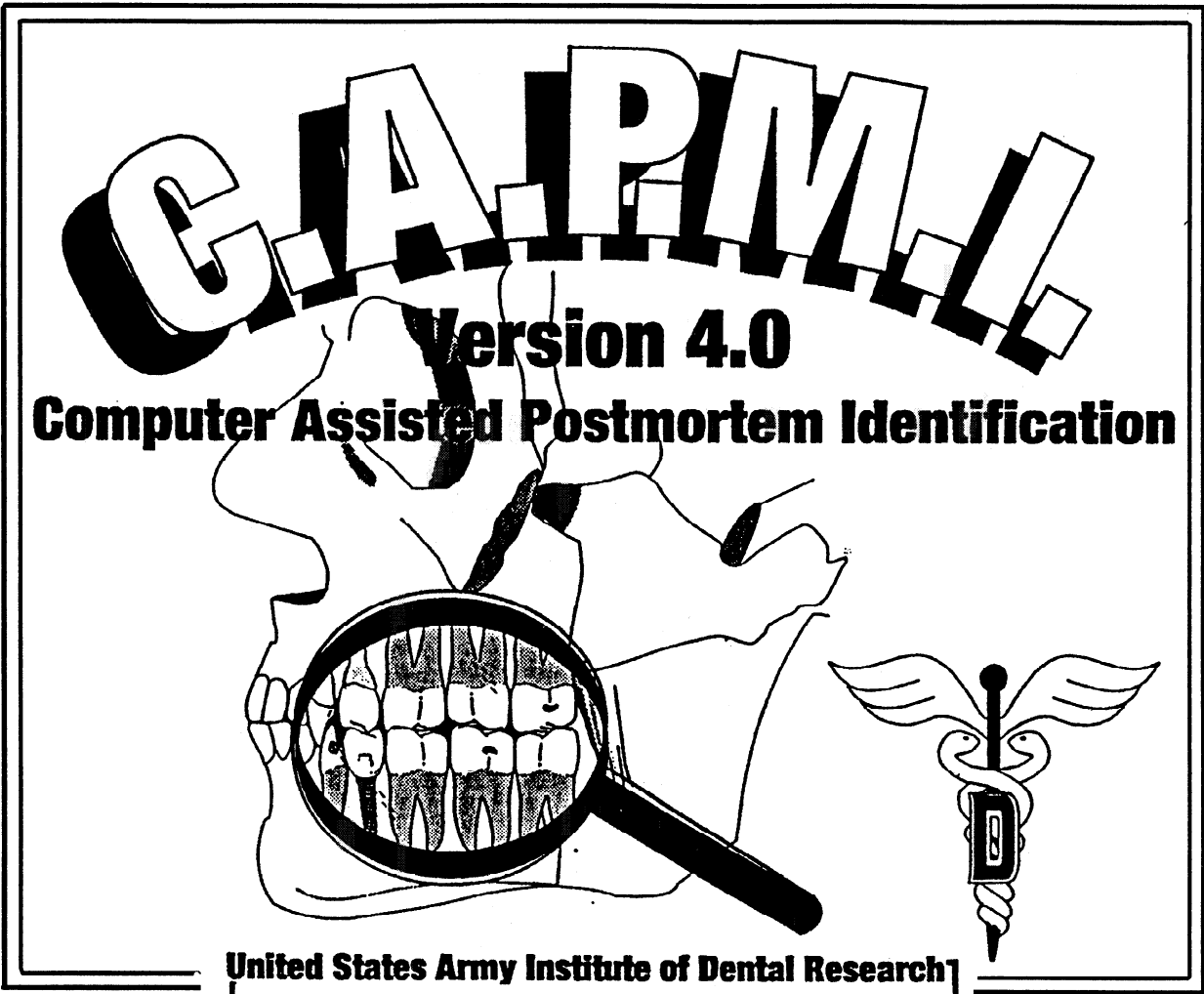
**Figure 10-17.—Reviewing antemortem dental records.**

numerical order on table by gender. Postmortem records of children may also be individually managed.

To provide quality control, provide the team leader of the forensic dentistry section the antemortem and postmortem dental records of potential positive ID established by the staff. The leader must reconstruct the positive dental ID. A dental identification form that summarizes the ID data can be completed at this

time. Figure 10-21 shows an example of a completed dental ID summary sheet.

This form is a tool in the decision-making and documentation process. It is used to provide rapid answers to questions when the team leader of the forensic dentistry section meets with the Identification Center chief at which time evidence regarding each case is presented. Only after all sections have



DTV2f018


Figure 10-18.—Computer Assisted Postmortem Identification (CAPMI).

presented their evidence and all inconsistencies have been explained or addressed should the Identification Center chief sign the case out as a positive ID. After the case has been signed out as a positive ID, the antemortem and postmortem dental records and associated evidence should be combined with the summary sheet into a single completed file. The antemortem composite dental record should be placed in the completed file only if the full dentition was present with the remains or if all dental/oral fragments have been recovered. If this is not the case and an additional oral fragment is recovered, the postmortem fragment may go unidentified since the necessary antemortem dental record was placed in the completed file. This mistake is made in almost every disaster. Please avoid it! In the consolidation process, the antemortem and postmortem dental radiographs that provided the conclusive evidence of the positive dental

identification should be photographed. These photographs or slides are indispensable for record keeping purposes and provide a superior method of displaying the evidence in court.

#### **EQUIPMENT, SUPPLIES, AND FACILITIES**

The following equipment, supplies, and facilities as listed in Tables 10-1, 10-2, and 10-3 are recommended for use in forensic dental operations. The items mentioned below are only a recommended list. Most of the equipment and supplies can be maintained in a medium-size tackle box and canvas bags for immediate availability and easy transport to the ID site. Your command should plan to add or subtract items or change quantities according to your local requirements.



**Figure 10-19.—Postmortem dental records.**



**Figure 10-20.—Reviewing radiographs.**

## DENTAL IDENTIFICATION SUMMARY REPORT

NAME OF DECEASED FROST, JACK, R RECOVERY NUMBER A-97-3  
 RANK: LT SEX: M RACE: C AGE: 31 SSN: 333-33-3333  
 EXAMINERS: A. B. SMITH, CAPT, DC, USN DATE: 12DEC97 PLACE: NAS, PENSACOLA, FL  
P. T. BOATE, CDR, DC, USN

COMPARISON OF ANTEMORTEM AND POSTMORTEM DENTAL RECORDS AND RADIOGRAPHS REVEAL CONCORDANCE ON TEETH NUMBER (DESCRIBE FEATURE):

1 <u>-</u>	9 <u>-</u>	17 <u>-</u>	25 <u>-</u>
2 <u>OL-AM. F-AM</u>	10 <u>-</u>	18 <u>-</u>	26 <u>-</u>
3 <u>-</u>	11 <u>-</u>	19 <u>-</u>	27 <u>PN</u>
4 <u>PN</u>	12 <u>PN</u>	20 <u>-</u>	28 <u>DOFL-GI</u>
5 <u>O,O-AM</u>	13 <u>FP-CV, RF-AP</u>	21 <u>-</u>	29 <u>RP-X</u>
6 <u>-</u>	14 <u>FP-X</u>	22 <u>-</u>	30 <u>RP-X</u>
7 <u>-</u>	15 <u>FP-CF</u>	23 <u>-</u>	31 <u>RP-X</u>
8 <u>-</u>	16 <u>X</u>	24 <u>-</u>	32 <u>MOFL-GI</u>

REMARKS: BILATERAL MANDIBULAR TORI NOTED. NO UNRESOLVED, CONTRADICTORY FINDINGS.  
TEETH 3, 18 AND 19 TREATED BY CIVILIAN DENTIST NOVEMBER 1997.

FINDINGS (CIRCLE ONE): POSITIVE IDENTIFICATION CONSISTENT WITH UNIDENTIFIED

SIGNATURE OF EXAMINERS: A.B. Smith P.T. Boate Mary (Chairman)

FINDINGS CONFIRMED BY: Walter T. Doan (DENTAL TEAM LEADER)

DTV21021

Figure 10-21.—Dental identification summary sheet.

**Table 10-1.—Equipment for up to 50 casualties**

<b>DESCRIPTION</b>	<b>QUANTITY</b>
50 KVP Endo X-ray unit, portable, self-contained	1
Portable lead screens	4
X-ray badges	9
X-ray film processor, with daylight loader	1
Fiberoptic light	1
Surgical saw (autopsy)	1
Headlamps	2
X-ray view boxes	3
Slide duplicator	1
Extension cords, 50 ft	3
CAPMI software and computer	1
35mm camera	1
Camera with self-developing film	1
Security badges	15
File cabinets, 4 drawer	1
Tables or gurney carts	As needed

**Table 10-2.—Forensic Dentistry Kit (Supplies)**

<b>DESCRIPTION</b>	<b>QUANTITY</b>
35mm film, 36 exposure	10 rolls
Paper pads	10
Identification forms: Postmortem, Antemortem, and Summary reports	100 each
Tags with string or wire	125
Manila envelopes for case records	100
Masking tape	2 rolls
Stapler with staples	2
Large felt tip markers	12
Felt tip pens (black ink)	12
Plastic denture bags	1 box LG 1 box SM
Pencils	2 boxes
Clip boards	10
Paper cups	1 box

Table 10-2.—Forensic Dentistry Kit (Supplies)—Continued

DESCRIPTION	QUANTITY
Work gloves, leather	4 pairs
Scrub suits	20 pairs
Surgical gowns, disposable	30
Surgical gloves, sizes 7 1/2 & 8	3 boxes each
Surgical mask	1 box
Dental X-ray film, double exposure	10 boxes
Chemicals for film processing	as needed
Self-developing film	5 rolls
Magnifying glass	1
Loops	2
Sodium hypochlorite	1 gallon
Safety glasses	5
Flashlights	6
Handsaw	1
Straight and curved retractors	1 set
Scaple handles	4
Scaple #10, #15, #20	1 box each
Large scissors, surgical	2
Small scissors, surgical	2
Large hemostats	4
Mouth props, large and small	1 each
Tongue blades	1 box
Cotton applicators	1 box
Mouth mirrors	1 2
Explorers	1 2
Periodontal scalers	3
Cutting pliers	1
Straight pliers	1
Straight chisel	1
Mallet	1
Millimeter rule	3
Spatula, #7 wax	1
Disclosing solution	2 bottles
Hydrogen peroxide solution	1/2 gallon

**Table 10-2.—Forensic Dentistry Kit (Supplies)—Continued**

DESCRIPTION	QUANTITY
4 x 4 sponges	10 boxes
Toothbrushes	20
Computer terminal paper	1 box
Ribbon for terminal printer	1
Occlusal X-ray film	1 box
Soap, antibacterial	6 bottles
Towels	10
Scrub brushes	5
Rubber aprons	10
Trash can liners	1 box

**Table 10-3.—Office Facilities**

<p><b>Office facilities:</b></p> <ul style="list-style-type: none"> <li>Room for antemortem records</li> <li>Room for postmortem records</li> <li>Postmortem exam area</li> </ul>
<p><b>Access to:</b></p> <ul style="list-style-type: none"> <li>Copy machine/computer</li> <li>Watts/DSN telephone lines</li> <li>Refrigeration</li> </ul>



## APPENDIX I

### REFERENCES USED TO DEVELOP THIS TRAMAN

- Dental Assistant Journeyman, Volume 1, Dental Administration, Management, and Supply*, CDC 4Y051A, Extension Course Institute, Air Education and Training Command, Air University, Maxwell Air Force Base, Montgomery, AL.
- Dental Assistant Journeyman, Volume 2, Dental Equipment and Instruments*, CDC 4Y051A, Extension Course Institute, Air Education and Training Command, Air University, Maxwell Air Force Base, Montgomery, AL.
- Dental Assistant Journeyman, Volume 3, Basic and Dental Sciences*, CDC 4Y051A, Extension Course Institute, Air Education and Training Command, Air University, Maxwell Air Force Base, Montgomery, AL.
- Dental Assistant Journeyman, Volume 4, Applied Dental Sciences*, CDC 4Y051A, Extension Course Institute, Air Education and Training Command, Air University, Maxwell Air Force Base, Montgomery, AL.
- Dental Assistant Journeyman, Volume 5, Radiology and Dental Health*, CDC 98150, Extension Course Institute, Air Education and Training Command, Air University, Maxwell Air Force Base, Montgomery, AL.
- Dental Assistant Journeyman, Volume 6, Infection Control and Emergency Procedures*, CDC 98150, Extension Course Institute, Air Education and Training Command, Air University, Maxwell Air Force Base, Montgomery, AL.
- Dental Assistant Journeyman, Volume 7A, Clinical Procedures*, CDC 98150-07A, Extension Course Institute, Air Education and Training Command, Air University, Maxwell Air Force Base, Montgomery, AL.
- Dental Assistant Journeyman, Volume 7B, Clinical Procedures*, CDC 4Y051, Extension Course Institute, Air Education and Training Command, Air University, Maxwell Air Force Base, Montgomery, AL.
- Dental Assistant Journeyman, Volume 7C, Clinical Procedures*, CDC 4Y051B, Extension Course Institute, Air Education and Training Command, Air University, Maxwell Air Force Base, Montgomery, AL.
- Dental Infection Control Program*, BUMEDINST 6600.10A, Department of the Navy, Bureau of Medicine and Surgery, Washington, DC, 1996.
- Dental Records Treatment Manual*, MED-631, Department of the Navy, Bureau of Medicine and Surgery, Washington, DC, 1997.
- Forensic Dentistry Manual, 32nd Annual Course*, Armed Forces Institute of Pathology, Washington, DC, 1996.
- Instructor's Manual for Basic Life Support*, American Heart Association, National Center, Dallas, TX, 1994.
- Manual of the Medical Department, US. Navy*, NAVMED P-117, Change 112, Department of the Navy, Bureau of Medicine and Surgery, Washington, DC, 1996.

*NAVMED 6600/3, Dental Health Questionnaire*, BUMEDINST 6600.12, Department of the Navy, Bureau of Medicine and Surgery, Washington, DC, 1993.

*Resuscitation Training*, BUMEDINST 1500.15A, Department of the Navy, Bureau of Medicine and Surgery, Washington, DC, 1996.

*Trial Implementation of Dental Examination and Associated Forms*, BUMED Notice 6600, Department of the Navy, Bureau of Medicine and Surgery, Washington, DC, 1997.

# INDEX

## A

- Accession examination, 2-4
- Acrylic repairs, 8-25
  - denture base repairs, 8-25
  - denture tooth repairs, 8-27
- Additional dental treatment forms, 2-25
  - Consultation Sheet, SF513, 2-25
- Air polishing unit, 3-7
- Alveolar Osteitis, 5-5
- Alveoloplasty, 5-4
- Amalgam restorations, 4-2
- Anatomical landmarks, 1-38
- Anesthetic, local, 4-19
- Antemortem dental examination, 10-18
  - computer support, 10-18
- Aspirating syringe, 4-7
- Aspirating syringe needle, 4-7
- Assembling matrices, 4-13
- Assisting in dental surgery, 5-20
  - circulating assistant, 5-20
  - scrub assistant, 5-20
- Automatic film processors, 1-27
  - with daylight loaders, 1-27
  - without daylight loaders, 1-27

## B

- Basic dental procedures, 4-19
- Basic life support, 9-3
  - CPR course certifications, 9-3
  - oxygen, use of, 9-4
  - resuscitating devices, 9-3
- Biopsy, 5-4
- Bisecting-angle technique, 1-14, 1-23
  - guidelines, 1-21

## C

- Calculus removal, 3-12
  - cement and insulating base instruments, 4-6
- Cast fabricating, 8-17
  - impression, 8-17
  - materials and mixing, 8-17
  - preparing to pour impressions, 8-17
- Cast trimming, 8-19
  - preliminary steps, 8-19
  - trimming, 8-19
- Cavity preparation, 4-23

- Cement and insulating base instruments, 4-6
- Charting, general, 2-6
- Charting markings, 2-6, 2-9
  - abbreviations/acronyms, 2-6
  - general, 2-6
- Circulating assistant, 5-20
- Composite resin instruments, 4-5
- Comprehensive examination, Type 1, 2-3
- Computer Assisted Postmortem Identification (CAPMI), 10-18
- Consultation Sheet, SF513, 2-25
- Current status form, 2-19
- Custom impression trays, 8-20
  - fabricating a tray with spacers, 8-22
  - spacers, 8-20
  - trays without spacers, 8-21
- Cutting instruments used in dental surgery, 5-9

## D

- Darkroom procedures, 1-29
- Dental classifications, 2-4
  - class 1, 2-6
  - class 2, 2-6
  - class 3, 2-6
  - class 4, 2-6
- Dental examinations, 2-1
  - examination duties, 2-21
  - patient preparation, 2-1
  - pre-examination duties, 2-1
- Dental floss, use of, 3-17
- Dental Exam Form (EZ603), 2-21
  - completing the back, 2-22
- Dental Exam Form (EZ603A), 2-22
- Dental identification, 10-5
  - classification, 10-10
  - principles, 10-7
  - problems, 10-7
  - radiographic comparison, 10-8
  - why dental identification works, 10-5
- Dental radiology, 1-1
- Dental X-ray machines, 1-3
  - control panel, 1-4
  - cylinder, 1-3
  - machine operation, 1-5
  - operational check, 1-4
  - securing the machine, 1-5
  - tubehead, 1-3
  - user maintenance, 1-6

Dentifrice, 3-18  
Designations, charting, and abbreviations, 2-6  
DTR infection control, 8-35

## E

Electrosurgery apparatus, 6-9  
Elevators, surgical, 5-10  
Emergencies, DTR, 9-1  
    emergency response team, 9-2  
    preventing, 9-1  
    vital signs, 9-1  
Emergencies, other, 9-4  
    anaphylactic shock, 9-6  
    angina pectoris, 9-4  
    asthma attack, 9-7  
    hyperventilation, 9-7  
    hypoglycemia, 9-6  
    seizures, 9-7  
    shock, 9-4  
    syncope, 9-5  
Endodontic procedures, 7-3  
    apicoectomy and periapical curettage, 7-4  
    bleaching, 7-4  
    incision and drainage, 7-4  
    pulp capping, 7-3  
    pulpotomy and pulpectomy, 7-3  
    retrograde filling, 7-4  
    root amputations, 7-4  
    root canal therapy, 7-4  
Endodontics, 7-1  
    accessories, 7-6  
    anesthesia, 7-11  
    apicoectomy, 7-4, 7-14  
    appointments, 7-5  
    bleaching, 7-4  
    canal cleansing and shaping, 7-13  
    causes, 7-1  
    diagnosis, 7-1  
    function, 7-1  
    incision and drainage, 7-4  
    instruments, 7-6  
    irrigation, 7-12  
    isolation, 7-11  
    materials, 7-5  
    medications, 7-13  
    periapical curettage, 7-4  
    pulp capping, 7-3  
    pulp removal, 7-12  
    pulpotomy and pulpectomy, 7-3  
    retrograde filling, 7-4  
    root amputations, 7-4  
    root canal filling, 7-14  
    root canal therapy, 7-4

Endodontic therapy, 7-11  
    anesthesia, 7-11  
    apicoectomy, 7-14  
    canal cleansing and shaping, 7-13  
    isolation, 7-11  
    irrigation, 7-12  
    medications, 7-13  
    opening the pulp and canals, 7-12  
    removing the pulp, 7-12  
    root canal filling, 7-14  
Equipment preparation, 2-2  
    dental chair, 2-2  
Examination and informed consent,  
    surgery, 5-1  
Examination duties, 2-2  
Examination types, 2-3  
    antemortem, dental, 10-18  
    antemortem/postmortem, records  
        comparison, 10-18  
    comprehensive examination, Type 1, 2-3  
    oral examination, Type 2, 2-3  
    other examination, Type 3, 2-3  
    postmortem examination, 10-15  
    screening evaluation, Type 4, 2-4  
Exostosis, 5-4  
Explorer, 3-10  
Exposure factors, film alignment, variations, 1-14

## F

Faulty radiographs, 1-34  
Film positioning devices, 1-26  
Film processing, 1-29  
    automatic processing, 1-29  
    darkroom procedures, 1-29  
    faulty radiographs, 1-34  
    film viewers, 1-36  
    mounting radiographs, 1-36  
    safety precautions, 1-29  
Finger rest, 3-10  
Fixed prosthetics, 8-1  
    artificial crowns, 8-2  
    inlay, 8-1  
    insertion, 8-32  
    interim fixed partial denture, 8-4  
    onlays, 8-1  
    partial denture, 8-2  
    procedures, 8-29  
    resin-bonded fixed partial denture, 8-4  
    splints, 8-4  
Foreign body removals, 5-5  
Four-handed dentistry, 4-15  
    zones and positions, 4-15  
Forceps, tooth extraction, 5-13

Forensic dentistry, 10-1  
  equipment, supplies, facilities, 10-21  
  estate, 10-1  
  identification, other methods, 10-2  
  insurance, 10-1  
  intelligence, 10-2  
  legal, 10-1  
  manpower, 10-1  
  psychological, 10-1  
Forensic examination, 2-8  
  charting and markings, 2-9  
Forensic form, 2-8  
  hard and soft tissue remarks section, 2-18  
Forms, EZ603A, 2-21  
Frenectomy, 5-4  
Fundamentals of dental radiology, 1-1

## H

Hand-cutting instruments, 4-1  
Home care, 3-16

## I

Incision and drainage, 5-5  
Identification of operative instruments. *See* operative instruments.  
Implants, 5-5  
Indications and contraindications, surgery, 5-1  
Infection control, 1-26  
  automatic film loader with daylight loader, 1-27  
  automatic film loader without daylight loader, 1-27  
  barrier control, 8-35  
  darkroom, 1-26  
  disposable plastic film packets, 1-27  
  DTR infection control, 8-35  
  film positioning devices, 1-26  
  handwashing, 1-26  
  intraoral film packets, 1-27  
  panoramic unit bite blocks, 1-26  
  X-ray chair, 1-28  
  X-ray tubehead and controls, 1-28  
informed consent, 5-1  
Instrument exchange, 4-16  
Instrument grasp, 3-10  
Instrumentation, scaling, 3-12  
Instrument preparation, 2-2  
Instrument sharpening, 6-14  
  periodontal chisel, 6-14  
  periodontal curette, 6-13  
  periodontal knife, 6-13  
  scalers, 6-14  
  sharpening devices, 6-12

Interproximal (bitewing) examination, 1-22  
  mounting, 1-37  
  parallel placement technique, 1-23  
Intraoral film, 1-27, 1-6  
  disposal plastic film packages, 1-27  
  precious metals recovery program, 1-7  
  storage, 1-6  
Intraoral radiographs, 1-6  
Impressions preliminary, 8-15  
  impression procedures, 8-15  
  materials required, 8-15  
Irrigation and aspiration, 4-20

## M

Mass casualty operations management, 10-10  
  dental radiology, 10-12  
  dental registrar, 10-11  
  dental team leader, 10-11  
  oral surgery, 10-11  
Mandibular occlusal examination, 1-25  
Maxillary occlusal examination, 1-25  
Matrix retainers, 4-12  
  assembling, 4-13  
Medical emergency guidelines, 9-3  
Medical examination (SF88), report of, 2-23  
Medication, administration, 9-8  
  adverse reaction, 9-8  
  treatment, 9-8  
Miscellaneous instruments, material and equipment, 4-7  
  surgical forceps, 5-8  
  surgical instruments, 5-5  
Modified pen grasp, 3-10  
Mounting radiographs, 1-36  
  anatomical landmarks, 1-38  
  full mouth, 1-38  
  interproximal, 1-37  
  procedures, 1-39  
Mouthguards, 8-22  
  fabricating mouthguards, 8-23  
Mouth mirror, 3-9

## O

Occasions for dental examination, 2-4  
  accession, 2-4  
  overseas screening, 2-4  
  periodic examination, 2-4  
  physicals, 2-4  
  separation, retirement, and special programs, 2-4

- Occlusal examination, 1-24
- Operative dentistry, 4-1
  - areas of, 4-1
  - four-handed dentistry, 4-15
  - operative procedures, 4-21
  - supply procedures, 4-27
- Operative instruments, 4-1
  - amalgam restoration instruments, 4-2
  - composite resin instruments, 4-5
  - oral examination, Type 2, 2-23
- Operative procedures, 4-21
- Oral hygiene instructions, 3-15
  - aids, 3-19
- Oral prophylaxis, 3-1
  - patient and operator positioning, 3-2
  - procedures, 3-11
  - system approach to systematic scaling, 3-11
- Oral surgery assistance, 5-1
  - assisting in dental surgery, 5-20
  - post-operative procedures, 5-25
  - surgical instruments, 5-5
  - surgical procedures, 5-24
- Oral surgery function, 5-1
  - examination and informed consent, 5-1
  - indications and contraindications, 5-1
- Oral surgery procedures, 5-3
  - tooth extractions, types, 5-3
- Osteotomy, 5-4
- Other examination, Type 3, 2-3
- Overseas screening, 2-4
  
- P**
  
- Pain and anxiety control, surgery, 5-3
- Palm grasp, 3-10
- Panoramic radiographs, 1-40
  - labeling, cassette, 1-42
  - operating machine, 1-42
  - operational check, machine, 1-40
  - preparing the film, 1-42
  - requirements for a good result, 1-42
  - user maintenance, 1-42
- Paralleling placement technique, 1-23
- Paralleling technique, 1-8
- Passing and receiving instruments, 4-16
- Patient and operator positioning, 3-2
- Patient dismissal, examination, 2-27
  - Patient preparation, X-ray, 1-7
- Pen grasp, 3-10
- Pericoronitis, 5-5
- Periapical examination, 1-8
  - bisecting-angle technique, 1-21
  - full mouth, 1-10
- Periapical examination—Continued
  - guidelines for taking, paralleling technique, 1-10
  - infect ion control, 1-26
  - interproximal (bitewing) examination, 1-22
- Periapical mounting, 1-38
- Periodic examination, 2-4
- Periodontal equipment, 3-4
  - air polishing unit, 3-7
  - sonic scaler, 3-9
  - ultrasonic scaler, 3-4
- Periodontal instruments, 6-5
  - furcation probes, 6-5
  - periodontal probes, 6-5
  - scaling and root planing, 6-5
- Periodontal procedures (routine), 6-9
  - gingival curettage, 6-10
  - occlusal equilibration, 6-9
  - periodontal scaling, root planning, and root desensitization, 6-10
- Periodontal procedures (surgery), soft and hard tissues, 6-10
  - bicuspidization, 6-12
  - gingivectomy, 6-10
  - gingivoplasty, 6-10
  - metallic implants, 6-12
  - osseous surgery, 6-11
  - periodontal flaps, 6-10
  - periodontal soft tissue grafts, 6-10
  - root amputation, hemisection, surgical dressings, 6-12
- Periodontal scaling, 3-11
  - calculus removal, 3-12
- Periodontal scaling, instruments, 3-9, 6-5
  - root planing instruments, 6-5
- Periodontal surgery instruments, 6-8
  - electrosurgery apparatus, 6-9
  - occlusal equilibration, 6-9
  - periodontal chisels, hoes and files, 6-9
  - periodontal curettes and sickles, 6-8
  - periodontal knives, 6-8
  - periosteal elevators, 6-8
  - routine periodontal procedures, 6-9
- Periodontics, 6-1
  - charting, 6-2
  - contraindications, 6-1
  - examination, 6-2
  - function, 6-1
  - indications, 6-1
  - treatment plan, 6-5
- Periodontic assistance, 6-1
- Physicals, 2-4

- Pin amalgam set, 4-15
  - Pits and fissure sealants, 3-19
  - Polishing teeth, 3-13
  - Precious metals recovery program, 1-7
  - Pre-examination duties, 2-1
    - patient preparation, 2-1
    - instrument/equipment preparation, 2-2
  - Presurgical procedures, 5-21
    - patient scrubbing procedures, 5-21
    - preparing the surgical room, 5-21
    - receiving the patient, 5-21
    - surgical team, scrubbing, gloving, and draping, 5-21
  - Preventive dentistry, 3-1
    - instrument grasp, 3-10
    - oral hygiene instructions, 3-15
    - oral prophylaxis, 3-1
    - periodontal scaling instruments, 3-4, 3-9
    - sealants, 3-19
    - technician, 3-1
    - types, uses, and maintenance of periodontal equipment, 3-4
  - Preparation for oral prophylaxis, 3-1
    - contraindications to, 3-2
  - Prosthetics appliances, maintenance of, 3-19
  - Prosthetics laboratory, 8-33
    - case request, 8-34
    - cases while in the laboratory, 8-34
    - impressions, 8-34
    - infection control, 8-35
    - stone or plaster cast, 8-34
  - Prosthetic assistance, 8-1
    - chairside, 8-27
    - DD Form 2322, 8-29
    - DTR infection control, 8-35
  - Prosthetic equipment, 8-9
    - alcohol torch, 8-10
    - articulator, 8-10
    - bench lathe, 8-10
    - bunsen burner, 8-11
    - cast trimmer, 8-11
    - face bow, 8-12
    - impression trays, 8-12
    - mixing bowl, 8-13
    - pneumatic curing unit, 8-13
    - vacuum adapter, 8-13
    - vibrator, 8-14
  - Prosthetic instruments, 8-14
    - crown remover, 8-14
    - knives, 8-14
    - roach carver, 8-14
    - spatulas, 8-15
  - Prosthetic materials, 8-6
    - acrylic resins, 8-8
    - dental alloys, 8-6
    - dental waxes, 8-8
    - gypsum products, 8-7
    - impression materials, 8-6
    - other prosthetic materials, 8-9
  - Post-operative procedures, 5-25
    - common postsurgical complications, 5-27
    - control of bleeding, 5-25
    - postsurgical instructions, 5-25
    - suture removal, 5-27
  - Pulpectomy and root canal treatment, 7-5
    - appointments, 7-5
    - endodontic materials, 7-5
    - instruments and accessories, 7-6
- R**
- Radiation safety, 1-2
    - assistant protection, 1-2
    - patient protection, 1-2
    - X-ray film log, 1-2
  - Radiology, postmortem, 10-12
  - Recording dental treatment, 2-7
    - current status form, 2-19
    - dental exam form, 2-21
    - forensic examination, 2-8
    - instructions for completing the EZ603-A, 2-22
  - Removable prosthetic prostheses, 8-4
    - complete dentures, 8-5
  - Report of Medical Examination, (SF88), 2-23
  - Reserve Dental Assessment and Certification, NAVMED 6600/12, 2-27
    - overdentures, 8-6
    - removable partial dentures, 8-5
  - Rubber dam instruments, 4-7
    - application, 4-10
- S**
- Scaling instruments, 3-12, 6-5
  - Screening evaluation, Type 4, 2-4
  - Screening examination, 3-4
  - Scrub assistant, 5-20
  - Sealants, 3-19
  - Separation, retirement, and special programs, 2-4
  - Sensitivity, 3-18
  - Sequestrectomy, 5-5
  - Sonic scaler, 3-9
  - Standard abbreviations and acronyms, 2-6
  - Supply procedures, 4-27
  - Surgical air drill, 5-18
  - Surgical instruments, 5-5

Surgical procedures, 5-24  
instrument setup and materials,  
5-25  
rules of aseptic technique, 5-24

## **T**

Terminology and classification of cavities,  
4-21  
Toothbrushes, electric, 3-16  
Toothbrushing, effective, 3-16  
evaluation, 3-18  
Tooth surfaces, 2-6  
Traumatic wound repair, 5-5

## **U**

Ultrasonic scaler, 3-4  
maintenance, 3-7

## **V**

Vacuum-formed templates, fabricating, 8-22, 8-23

## **X**

X-ray chair, 1-28  
X-ray film log, 1-2  
X-ray, patient preparation, 1-7  
X-ray tubehead and controls, 1-28

## **Z**

Zones and positions, 4-15



---

---

# *Assignment Questions*

---

---

**Information:** The text pages that you are to study are provided at the beginning of the assignment questions.



# ASSIGNMENT 1

Textbook Assignment: "Dental Radiology," chapter 1, pages 1-1 through 1-42.

---

- 1-1. Which of the following scientists first discovered X-rays?
1. Wilhelm Konrad Roentgen
  2. Doctor H. G. Gama
  3. Doctor Otto Proton
  4. Raymond Cathode
- 1-2. What is the basic difference between X-rays and other electromagnetic rays?
1. Electromagnetic rays travel in wave motion
  2. X-rays are invisible
  3. X-rays are visible
  4. Their wavelengths differ
- 1-3. Which of the following is NOT a characteristic or property of X-rays?
1. They travel in straight lines
  2. They travel at the speed of sound
  3. They cause irritation to living cells
  4. They cause certain substances to fluoresce
- 1-4. Which of the following factors control the density of an X-ray image?
1. Kilovoltage (kVp)
  2. Milliamperage (mA)
  3. Target film distance (TFD)
  4. All of the above
- 1-5. Which of the following personnel are authorized to order and diagnostically interpret dental radiographs?
1. Dental X-ray technicians
  2. Front desk personnel
  3. Dental officers
  4. Dental technicians
- 1-6. When taking radiographs, always drape the patient with a lead apron.
1. True
  2. False
- 1-7. What speed of film is most commonly used for dental radiographs?
1. Fast
  2. Slow
  3. Mega
  4. Average
- 1-8. The environmental film badge should be placed behind the lead-lined barrier at least what number of feet from the tube head?
1. 10
  2. 6
  3. 8
  4. 4
- 1-9. Which of the following is NOT a safety precaution for taking radiographs?
1. Always stand behind a lead screen during an exposure
  2. Never stand in the path of the central X-ray beam during exposure
  3. Never hold the tube head or the tube head cylinder of the X-ray machine during exposure
  4. Hold the film packet in the patient's mouth during exposure if necessary
- 1-10. In the dental treatment facility, which of the following types of dental X-ray units are most commonly used?
1. Ceiling-mounted
  2. Floor-mounted
  3. Wall-mounted
  4. Portable

- 1-11. The lead diaphragm restricts the X-ray beam to what size?
1. 2 inches
  2. 2.6 inches
  3. 2.75 inches
  4. 3 inches
- 1-12. What is the first task each day that a radiology technician should perform?
1. Turn on the automatic processor
  2. Set the kilovoltage (kVp) on the X-ray machine
  3. Turn on the X-ray machine and perform the operational check
  4. Take the positioning devices out of the germicidal agent
- 1-13. The time setting on the X-ray machine is measured by using which of the following methods?
1. Minutes or impulses
  2. Minutes or milliamperes
  3. Fractions of a second or milliamperes
  4. Fractions of a second or impulses
- 1-14. When exposing a radiograph, you should stand behind a lead-lined shield and at least what number of feet from the tube head?
1. 10
  2. 6
  3. 8
  4. 4
- 1-15. Which of the following procedures should be included in the daily maintenance of the X-ray machine?
1. Dusting
  2. Cleaning with a cloth moistened with detergent solution
  3. Both 1 and 2 above
  4. Cleaning with a cloth moistened with solvent
- 1-16. You should attempt to complete all X-ray repairs yourself.
1. True
  2. False
- 1-17. What are the types of X-ray film used for intraoral radiographic examinations?
1. Bitewing, inter-proximal, and periapical
  2. Inter-proximal, periapical and occlusal
  3. Panoramic and periapical
  4. Occlusal and panoramic
- 1-18. Unprocessed intraoral X-ray film should be stored in what type of container?
1. Plastic
  2. Metal
  3. Cardboard
  4. Lead lined
- 1-19. Which of the following X-ray materials should be saved and turned in as part of the Precious Metals Recovery Program (PMRP)?
1. The X-ray packets
  2. The fixer solution
  3. The lead from the X-ray packets
  4. Both 2 and 3 above
- 1-20. When radiographs are ordered for a female patient, what is the first patient preparation procedure to follow?
1. Have the patient remove her eyeglasses
  2. Have the patient remove her earrings
  3. Ask the patient if she has any type of denture
  4. Ask the patient if she is pregnant
- 1-21. To provide images of the crowns, roots, and support structures of the teeth, which of the following radiographs should be taken?
1. Inter-proximal
  2. Periapical
  3. Bitewing
  4. Occlusal
- 1-22. The bisecting angle technique is the preferred method and recommended for routine use when taking periapical radiographs.
1. True
  2. False
- 1-23. The paralleling device consists of which of the following parts?
1. A locator ring
  2. An indicator rod
  3. A bite-block
  4. All of the above

- 1-24. When assembling the paralleling device, the printed side of the film packet should be in what position?
1. Facing the plastic support in the film positioning slot
  2. Away from the plastic support in the film positioning slot
  3. Facing you, toward the top of the bite-block
  4. Away from you, toward the top of the bite-block
- 1-25. The assembled positioning device for the right maxillary quadrant can also be used in what other area of the mouth?
1. The mandibular right quadrant
  2. The mandibular left quadrant
  3. The maxillary left quadrant
  4. The maxillary right quadrant
- 1-26. What number of periapical radiographs make up a full-mouth series?
1. 7
  2. 9
  3. 14
  4. 18
- 1-27. When taking dental radiographs, which of the following milliamperage settings should be used as the normal setting?
1. 8 mA
  2. 10 mA
  3. 12 mA
  4. 15 mA
- 1-28. When taking a radiograph on an edentulous area, you should decrease the kVp setting by what number of degrees?
1. 1
  2. 2
  3. 5
  4. 7
- 1-29. When taking radiographs on a child, what kVp setting should normally be used?
1. 60
  2. 70
  3. 80
  4. 90
- 1-30. If the film packet is centered on the midline and parallel with the long axis, what area of the mouth is being X-rayed?
1. Maxillary cuspid area
  2. Maxillary incisor area
  3. Mandibular incisor area
  4. Both 2 and 3 above
- 1-31. When exposing the mandibular molar area, what is the position of the film packet?
1. Centered on the first molar
  2. Centered on the second molars
  3. Parallel with the short axis of the molars
  4. On the anterior edge including the mesial half of the cuspid
- 1-32. When a patient has a low palatal vault, which of the following special film placement procedures should you use?
1. Bend the film packet
  2. Place a cotton roll on the upper surface of the bite-block
  3. Place one cotton roll on each side of the bite-block
  4. Place a cotton roll on the lower surface of the bite-block
- 1-33. When taking radiographs, which of the following factors should you consider before using the bisecting-angle technique?
1. There are no paralleling devices available
  2. The patient cannot close mouth on the bite-block
  3. The patient has a rubber dam in place
  4. All of the above
- 1-34. Placing the film packet into the patient's mouth using the bisecting-angle technique should be accomplished by which of the following methods?
1. Using hemostats
  2. Sliding the film into position
  3. Using your thumb and index finger
  4. Having the patient assist in the placement of the film packet

- 1-35. When exposing a maxillary radiograph using the bisecting angle technique, in what manner should the patient hold the film in place?
1. Using the thumb of the hand opposite the tooth being radiographed
  2. Using the thumb of the hand on the same side as the tooth being radiographed
  3. Using the index finger of the hand on the same side as the tooth being radiographed
  4. Holding the X-ray holding device with the hand opposite the tooth being radiographed
- 1-36. What is vertical angulation?
1. The side-to-side positioning of the tube head
  2. The side-to-down positioning of the tube head
  3. The up-and-down positioning of the tube head
  4. The perpendicular positioning of the tube head
- 1-37. When it is parallel to the floor, what is the angulation of the tube head?
1. Zero degrees
  2. Minus degrees
  3. Plus degrees
  4. Both 2 and 3 above
- 1-38. What is the cause of elongated radiographic images?
1. Too much vertical angulation
  2. Too much horizontal angulation
  3. Too little vertical angulation
  4. Too little horizontal angulation
- 1-39. When using the bisecting-angle technique on a patient with a shallow vault, you should change the vertical angulation by how many degrees?
1. - 3 °
  2. - 5 °
  3. + 3 °
  4. + 5 °
- 1-40. The position of the patient's mid-sagittal plane must be perpendicular to the floor when exposing a periapical radiograph using the bisecting-angle technique.
1. True
  2. False
- 1-41. What landmark is used when exposing the maxillary bicuspid area?
1. The tip of the nose
  2. Beside the ala of the nose
  3. Below the pupil of the eye
  4. Below the outer angle of the eye and below the zygomatic bone
- 1-42. When exposing the mandibular bicuspid area using the bisecting-angle technique, what landmark should you use?
1. Below the pupil of the eye and 1/4 inch above the lower border of the mandible
  2. The tip of the chin and 1/4 inch above the lower border of the mandible
  3. Beside the ala of the nose and below the zygomatic bone
  4. Below the outer angle of the eye and below the zygomatic bone
- 1-43. Which type of radiograph records the coronal and cervical portions of both the maxillary and mandibular teeth?
1. Periapical
  2. Occlusal
  3. Interproximal
  4. Both 2 and 3 above
- 1-44. When you are using the paralleling device technique to expose inter-proximal radiographs, the film should be positioned in the patient's mouth so that the anterior edge of the film touches what area?
1. Mesial surface of the mandibular cuspid
  2. Mesial surface of the maxillary bicuspid
  3. Distal surface of the mandibular cuspid
  4. Distal surface of the maxillary bicuspid
- 1-45. When exposing interproximal radiographs using the bisecting-angle technique, what is the vertical angulation of the tube head?
1. -10° to -5°
  2. - 5° to 0°
  3. 0° to + 5°
  4. + 5° to +10°
- 1-46. What type of radiographic examination is conducted to depict fractures of the jaw or gross pathological conditions?
1. Bitewing
  2. Occlusal
  3. Periapical
  4. Interproximal

- 1-47. The occlusal film packet contains two X-ray films.
1. True
  2. False
- 1-48. What X-ray machine settings should you use when exposing a maxillary occlusal radiograph on an adult?
1. 10 mA, 87 kVp, and 60 impulses
  2. 12 mA, 90 kVp, and 60 impulses
  3. 10 mA, 90 kVp, and 60 impulses
  4. 12 mA, 87 kVp, and 40 impulses
- 1-49. What vertical angulation setting should you use when exposing a maxillary anterior occlusal radiograph?
1. + 50°
  2. + 55°
  3. + 60°
  4. + 65°
- 1-50. When exposing a maxillary posterior occlusal radiograph, you should use what vertical angulation setting?
1. + 75°
  2. + 70°
  3. + 65°
  4. + 60°
- 1-51. When exposing a mandibular anterior occlusal radiograph, what vertical angulation should you use?
1. -10°
  2. - 5°
  3. 0°
  4. + 5°
- 1-52. Which of the following surfaces located in the darkroom should you disinfect daily?
1. Counters
  2. Doorknobs
  3. Light switches
  4. All of the above
- 1-53. Automatic film processors with daylight loaders should be used to develop all radiographs in facilities that have darkrooms.
1. True
  2. False
- 1-54. Which of the following methods should you use to decontaminate a fabric light shield sleeve?
1. Gas sterilization
  2. Steam sterilization
  3. Dry heat sterilization
  4. Dispose of the fabric light shield sleeve
- 1-55. You should change the plastic wrap covering on the tube head at what minimum frequency?
1. Daily
  2. Twice a day
  3. Every hour
  4. After each patient
- 1-56. A safelight is the only safe source of illumination used in the darkroom when processing radiographs.
1. True
  2. False
- 1-57. When checking for light leaks in the darkroom, you should leave the penny on the X-ray film for at least what number of minutes?
1. One
  2. Five
  3. Three
  4. Seven
- 1-58. Which of the following methods is most commonly used to process dental radiographs in the Navy?
1. Laser processing
  2. Manual processing
  3. Computer processing
  4. Automatic processing
- 1-59. After turning on the automatic processing unit, it should take what number of minutes to reach the proper operating temperature?
1. 5 to 10 minutes
  2. 10 to 15 minutes
  3. 15 to 20 minutes
  4. 25 to 30 minutes

- 1-60. You should wait what number of seconds between films before inserting another film into the automatic processor?
1. 10
  2. 12
  3. 15
  4. 30
- 1-61. The developer and fixer solutions in the automatic processor should be changed at what minimum frequencies?
1. Daily
  2. Weekly
  3. Biweekly
  4. Every 3 to 4 weeks
- 1-62. The processing solutions used in the automatic processor are the same as those used in the manual processing procedure.
1. True
  2. False
- 1-63. The cleaning of the roller transports and the solution tanks in the automatic processor are accomplished at what minimum intervals?
1. Twice a day
  2. Daily
  3. Weekly
  4. Monthly
- 1-64. When the green light on the control panel of a small automatic processor is alternating between flickering and full on, what does this indicate?
1. Optimum 74° to 76°F temperature is being maintained
  2. The processing solutions are ready to be changed
  3. The temperature of the water has reached 80°F
  4. The processor is ready to be secured

- A. Herringbone image
- B. Reticulation
- C. Stained
- D. Fogged

Figure 1 -A

**IN ANSWERING QUESTIONS 1-65 THROUGH 1-69, SELECT THE FAULTY RADIOGRAPH TERM FROM FIGURE 1-A THAT MATCHES THE DESCRIPTION GIVEN AS THE QUESTION. RESPONSES MAY BE USED MORE THAN ONCE.**

- 1-65. The film was held too close to the safelight.
1. A
  2. B
  3. C
  4. D
- 1-66. The wrong side of the film packet was exposed.
1. A
  2. B
  3. C
  4. D
- 1-67. The film was exposed to stray radiation.
1. A
  2. B
  3. C
  4. D
- 1-68. The film was taken from a warm developer to a cold rinse.
1. A
  2. B
  3. C
  4. D
- 1-69. The film was processed in dirty solutions.
1. A
  2. B
  3. C
  4. D
- 1-70. When mounting radiographs, the raised dimple should be facing you.
1. True
  2. False
- 1-71. Which teeth could be identified radiographically by a large white region caused by the bone of the nasal septum?
1. Mandibular incisors
  2. Mandibular cuspids and bicuspid
  3. Maxillary incisors
  4. Maxillary incisors and bicuspid



1-72. Which of the following radiographs should be taken to provide an extraoral image of both dental arches and the temporomandibular joints?

1. Inter-proximal
2. Panoramic
3. Occlusal
4. Bitewing

1-73. When performing the operational checks on a panoramic X-ray machine, remove the lead cap of the collimator.

1. True
2. False

1-74. To prevent overheating of the panoramic X-ray head, you should wait at least what number of minutes between exposures?

1. 5
2. 6
3. 7
4. 8

1-75. You should use a soft dry cloth and wipe the metal surfaces of the panoramic X-ray machine at least how often?

1. Daily
2. Weekly
3. Twice a week
4. After each patient

# ASSIGNMENT 2

Textbook Assignment: "Dental Examinations," chapter 2, pages 2-1 through 2-27.

---

- 2-1. Which of the following procedures is one of the basic professional services provided on an annual basis to Sailors by the Navy dental team?
1. Dental examination
  2. Medical screening
  3. Prosthetic treatment
  4. Orthodontic treatment
- 2-2. When seating the patient for a dental exam, where should you position the dental light to avoid shining the light in the patient's eyes?
1. Above the patient's mouth
  2. Beneath the patient's chin
  3. Above the patient's forehead
  4. Beneath the patient's chest
- 2-3. Which of the following dental instruments and/or materials should be included in a basic dental examination instrument setup?
1. A mouth mirror and explorer
  2. A periodontal probe and cotton forceps
  3. A tongue depressor, cotton rolls, and gauze
  4. All of the above
- 2-4. Dental examinations are classified by what total number of examination types?
1. One
  2. Two
  3. Three
  4. Four
- 2-5. What type of examination is a comprehensive hard and soft tissue examination routinely done with study models?
1. Type 1
  2. Type 2
  3. Type 3
  4. Type 4
- 2-6. Which of the following personnel may perform a type 4 dental screening evaluation?
1. A dental officer
  2. A dental hygienist
  3. A qualified dental assistant
  4. All of the above
- 2-7. What is the primary purpose for conducting annual dental examinations?
1. To qualify personnel for special pay
  2. To qualify personnel for special duty
  3. To qualify personnel for special programs
  4. To access the readiness status of active duty personnel
- 2-8. What form should you use to document the findings of a dental examination for overseas screening?
1. NAVMED 1050/3
  2. NAVMED 1300/1
  3. NAVMED 6000/2
  4. NAVMED 6600/12
- 2-9. A member's commanding officer can approve a member for overseas assignment even when the dental officer recommends disapproval.
1. True
  2. False
- 2-10. All active duty members and reservists should have medical examinations at which of the following events or intervals?
1. Annually after age 60
  2. Every 5 years through age 50
  3. Upon entry to enlisted or commissioned active duty
  4. All of the above
- 2-11. What dental classification indicates that the patient's dental condition, if not treated or followed up, could have the potential, but is not expected to, result in dental emergencies within the next 12 months?
1. Class 1
  2. Class 2
  3. Class 3
  4. Class 4

- 2-12. When identifying and locating caries or existing restorations, how should you refer to an 8-MID designation?
1. Distal, incisal, mesial aspects of a left maxillary central incisor
  2. Distal, incisal, mesial aspects of a left mandibular incisor
  3. Mesial, incisal, distal aspects of a right maxillary central incisor
  4. Mesial, incisal, distal aspects of a right mandibular incisor
- 2-13. When recording the use of copal varnish in the dental treatment record, which of the following abbreviations should you use?
1. CV
  2. Cop
  3. Copal
  4. Cop Var
- 2-14. What abbreviation should you use when recording that the patient was informed of examination findings and treatment plan?
1. PTINF
  2. PTINFTX
  3. PTINFTXPL
  4. Pt info tx plan
- 2-15. When charting the top section of the Forensic Examination form, what symbol should you use to indicate missing teeth or teeth not visible in the patient's mouth?
1. O
  2. //
  3. X
  4. =
- 2-16. Which of the following terms is often used when referring to a double occlusal restoration?
1. Ace
  2. Duce
  3. Snake eyes
  4. Double ace
- 2-17. Nonmetallic restorations are made of which of the following types of materials?
1. Acrylic resin
  2. Glass Ionomer
  3. Fissure sealant
  4. All of the above
- 2-18. A nonmetallic permanent restoration is annotated by drawing an outline of the restoration showing size, location, shape, and inscribing vertical lines within the outline.
1. True
  2. False
- 2-19. When charting a Forensic Examination form, what method, if any, should you use to describe the differences between gold and chrome alloy restorations?
1. Indicate in the "Remarks" section that the restoration is chrome alloy
  2. Inscribe horizontal lines in the chrome alloy only
  3. Inscribe horizontal lines in the chrome alloy and vertical lines in the gold restoration
  4. None
- 2-20. When charting, how should you indicate that gold material was used in a fixed partial denture (FPD)?
1. Inscribe vertical lines
  2. Inscribe horizontal lines
  3. Inscribe diagonal parallel lines
  4. Outline each aspect of the FPD only
- 2-21. What procedure should you use to chart the presence of supernumerary teeth?
1. Insert a "D" in the location on the tooth number line
  2. Insert a "S" in the location on the tooth number line
  3. Draw an outline of the tooth in its approximate location
  4. Both 2 and 3 above
- 2-22. The Forensic Dental Examination form is completed using black ink.
1. True
  2. False
- 2-23. The Remarks section of the Forensic Dental Examination form is used to differentiate between which of the following types of dental materials?
1. Sealants
  2. Temporaries
  3. Composites
  4. All of the above

- 2-24. What number of Angle classifications could be used on the Forensic Examination form?
1. One
  2. Two
  3. Three
  4. Four
- 2-25. On the Forensic Examination form, what method should you use to indicate that a patient does NOT have a soft tissue condition?
1. Write "none" in the Soft Tissue Remarks section
  2. Write "none" in the Hard Tissue Remarks section
  3. Write "no existing conditions" in the Soft Tissue Remarks section
  4. Leave blank if a condition does not exist
- 2-26. Where in the occlusion section of the Forensic Examination Form should you document and record any other occlusal condition not listed?
1. Section A
  2. Section B
  3. Remarks
  4. Hard Tissue Remarks
- 2-27. Which of the following non-pathologic findings should you annotate in the Hard Tissue Remarks section on the Forensic Examination form?
1. Tori
  2. Rotated teeth
  3. Intrinsic staining
  4. All of the above
- 2-28. What procedure should you use when a patient requires the completion of a new Current Status form?
1. Complete box 1 of the Current Status form only
  2. Complete boxes 1 and 2 of the Current Status form
  3. Transfer the information from the previous forms to the new Current Status form
  4. None, a patient's Current Status form should never need to be replaced
- 2-29. Which of the following conditions should be annotated in pencil in box 1 of the Current Status form?
1. Carious lesions
  2. Periradicular lesions
  3. Indications for root canal treatment
  4. All of the above
- 2-30. The same charting symbols are used in boxes 1 and 2 on the Current Status form.
1. True
  2. False
- 2-31. What does an even line drawn on the root of the tooth indicate?
1. Fractured tooth
  2. Underfilled root canal
  3. Resorption of the root
  4. Periapical radiolucency
- 2-32. You should be able to chart the information for the SF-88 by using what box of the Current Status form?
1. 1
  2. 2
  3. Both 1 and 2 above
  4. 4
- 2-33. Pencil entries are authorized for use in box 2 of the Current Status form.
1. True
  2. False

- 2-34. What method, if any, should you use to indicate the materials used for existing restorations annotated in box 2 of the Current Status form?
1. Indicate in the "remarks" section the materials used
  2. Indicate in the "remarks" section if the material used was an alloy
  3. Indicate in the "remarks" section if the material used was made out of gold
  4. None; there are not any remarks made to indicate materials used
- 2-35. What new dental form provides a record of initial accession exam and all subsequent periodic, annual, recall, and separation exams?
1. SF 88
  2. SF 603
  3. EZ 603
  4. EZ 600
- 2-36. What part of the S.O.A.P includes the reason for the visit and a statement of the chief complaint?
1. Subjective
  2. Objective SF 603
  3. Assessment
  4. Plan
- 2-37. What part of the S.O.A.P includes the health questionnaire review findings?
1. Subjective
  2. Objective
  3. Assessment
  4. Plan
- 2-38. Which part of the S.O.A.P. includes the patient's treatment needs?
1. Subjective
  2. Objective
  3. Assessment
  4. Plan
- 2-39. Which of the following references should you use to complete the Dental Examination form?
1. MANMED, Chapter 6
  2. MANMED, Chapter 16
  3. BUMEDINST 6100.1
  4. NAVMEDCOM 6600.1
- 2-40. The back of the EZ 603 Form may be overprinted with a command specific format.
1. True
  2. False
- 2-41. Which of the following forms should you use to document dental treatment completed from the treatment plan, dental emergencies, and any other narrative dental findings?
1. SF 88
  2. SF 513
  3. EZ 600
  4. EZ 603A
- 2-42. What color ink should you use for the medical alert entry on the EZ 603A Form?
1. Red
  2. Blue
  3. Black
  4. Green
- 2-43. What form should you use to record the dental examination completed in conjunction with a medical physical?
1. SF 88
  2. SF 513
  3. SF 600
  4. EZ 600
- 2-44. Which of the following entries should you annotate in the space marked "Remarks and Additional Dental Defects and Diseases" on the report of the Medical Examination form?
1. Dental classification
  2. Type of dental exam
  3. Qualified "YES" or "NO"
  4. All of the above
- 2-45. What form should you use to refer a patient to another specialist or to medical for further evaluation or treatment?
1. SF 88
  2. SF 513
  3. SF 515
  4. EZ 600

2-46. Which section on the Consultation Sheet should you leave blank for the person receiving the form to document his or her findings?

1. Reason for request
2. Provisional diagnosis
3. Consultation report
4. Place of consultation

2-47. Voluntary Training Unit personnel or Selected Reserve personnel could require which of the following forms to be completed in conjunction with their Type 1 or Type 2 dental exam?

1. SF 513
2. SF 600
3. NAVMED 6600/12
4. NAVMED 6150/10

2-48. The Naval Reserve Type 1 or Type 2 dental examination should be performed at a minimum of what event or time period?

1. Every year
2. Every 5 years
3. With any required physical examination
4. Both 2 and 3 above

2-49. The dental chair should be placed in which of the following positions to dismiss the patient?

1. Arm raised, lowest, down right position
2. Arm raised, lowest, upright position
3. Arm lowered, lowest, down right position
4. Arm lowered, lowest, upright position

2-50. When patients complete their dental examination, you should direct them to make future dental appointments at which of the following departments?

1. Front desk
2. Operative
3. Oral Surgery
4. Oral Diagnosis

## ASSIGNMENT 3

Textbook Assignment: "Preventive Dentistry," chapter 3, pages 3-1 through 3-20; and "Operative Dentistry," chapter 4, pages 4-1 through 4-27.

- 
- |                                                                                                                                                                                                                                                                                                            |                                                                                                                                                                                                                                                                       |
|------------------------------------------------------------------------------------------------------------------------------------------------------------------------------------------------------------------------------------------------------------------------------------------------------------|-----------------------------------------------------------------------------------------------------------------------------------------------------------------------------------------------------------------------------------------------------------------------|
| <p>3-1. The formulation, supervision, and execution of the Preventive Denistry Program is found in what SECNAV instruction?</p> <ol style="list-style-type: none"><li>1. 6600.1</li><li>2. 6600.2</li><li>3. 6600.3</li><li>4. 6600.5</li></ol>                                                            | <p>3-7. The water supply pressure of an ultrasonic scaling unit has a maximum range of how many psi?</p> <ol style="list-style-type: none"><li>1. 60</li><li>2. 40</li><li>3. 25</li><li>4. 15</li></ol>                                                              |
| <p>3-2. Which of the following meanings best describes the term prophylaxis?</p> <ol style="list-style-type: none"><li>1. Prevention of disease</li><li>2. Prevention of calculus</li><li>3. Prevention of bone loss</li><li>4. Prevention of stain</li></ol>                                              | <p>3-8. What ultrasonic tip is most commonly used for supra and subgingival calculus deposits?</p> <ol style="list-style-type: none"><li>1. Beaver-tail</li><li>2. Chisel</li><li>3. Universal</li><li>4. Periodontal probe</li></ol>                                 |
| <p>3-3. Patients with subgingival calculus will have an appointment with which of the following dental personnel?</p> <ol style="list-style-type: none"><li>1. Expanded duty preventive dentistry technician</li><li>2. Dental hygienist</li><li>3. Dentist</li><li>4. Both 2 and 3 above</li></ol>        | <p>3-9. The working end of the instrument tip of an ultrasonic scaler should be adapted to what degree angle to the long axis of the tooth?</p> <ol style="list-style-type: none"><li>1. 0 to 5</li><li>2. 10 to 15</li><li>3. 15 to 20</li><li>4. 20 to 25</li></ol> |
| <p>3-4. When positioning a patient for an oral prophylaxis, at what degree should the back of the patient's chair be angled?</p> <ol style="list-style-type: none"><li>1. 15</li><li>2. 20</li><li>3. 25</li><li>4. 35</li></ol>                                                                           | <p>3-10. The air polishing unit uses which of the following materials to operate?</p> <ol style="list-style-type: none"><li>1. Air</li><li>2. Water</li><li>3. Sodium bicarbonate</li><li>4. All of the above</li></ol>                                               |
| <p>3-5. What phase, if any, is included in the screening examination of a scaling procedure?</p> <ol style="list-style-type: none"><li>1. Periodontal charting</li><li>2. Examination of patient's personal tooth brush</li><li>3. Examination of the teeth and gingival tissues</li><li>4. None</li></ol> | <p>3-11. Which of the following areas should be avoided while using the air polishing unit?</p> <ol style="list-style-type: none"><li>1. Enamel</li><li>2. Soft tissue</li><li>3. Heavy stained teeth</li><li>4. Middle one-third of the tooth</li></ol>              |
| <p>3-6. Cavitation aids in the mechanical removal of what two substances by the vibrating tip?</p> <ol style="list-style-type: none"><li>1. Plaque and carries</li><li>2. Calculus and carries</li><li>3. Plaque and calculus</li><li>4. Calculus and gingivitis</li></ol>                                 | <p>3-12. Which of the following sonic scaler tips is recommended for patients who experience sensitivity?</p> <ol style="list-style-type: none"><li>1. Sickle</li><li>2. Perio</li><li>3. Beaver</li><li>4. Universal</li></ol>                                       |

- 3-13. Fogging of the mouth mirror can be prevented by which, if any, of the following methods?
1. Using a disinfection solution
  2. Having the patient breathe through the mouth
  3. Running the mirror under cold water
  4. None of the above
- 3-14. Which of the following is NOT an instrument grasp?
1. Pen
  2. Palm
  3. Finger
  4. Modified pen
- 3-15. What teeth of the mouth are scaled last using a systematic routine?
1. Maxillary anterior
  2. Mandibular anterior
  3. Left maxillary posterior
  4. Right maxillary posterior
- 3-16. Dental technicians are only allowed to remove calculus in what areas of the mouth?
1. Sublingual
  2. Submandibular
  3. Subgingival
  4. Supragingival
- 3-17. Which of the following methods is the easiest way to detect supragingival calculus?
1. Visually
  2. Tactile
  3. Disclosing agent
  4. Disinfection agent
- 3-18. How many basic scaling strokes are there?
1. One
  2. Two
  3. Three
  4. Four
- 3-19. Which scaling stroke is made at a 45° angle to the long axis of the tooth?
1. Oblique
  2. Vertical
  3. Horizontal
  4. Exploratory
- 3-20. Tooth polishing removes what types of materials from the teeth?
1. Overhangs
  2. Plaque and stains
  3. Plaque and calculus
  4. All of the above
- 3-21. At what speed should a handpiece with a prophylaxis attachment run?
1. Slow
  2. Medium
  3. Fast
  4. Both 2 and 3 above
- 3-22. When polishing teeth, what type of motion should a rubber cup be in to keep contact with the tooth?
1. Bouncing
  2. Constant
  3. Vertical
  4. Horizontal
- 3-23. After a fluoride treatment, patients should not rinse, drink, eat, or smoke for at least how many minutes?
1. 1 0
  2. 2 0
  3. 3 0
  4. 4 0
- 3-24. To prevent dental disease, at least how often during a 24-hour period should bacterial plaque be removed?
1. Once
  2. Twice
  3. Three times
  4. Four times
- 3-25. Which of the following toothbrushing techniques is effective for a patient to perform?
1. Electric
  2. Overhand
  3. Modified Bass
  4. Modified Tooth
- 3-26. To properly floss, about how many inches of floss should you cut off?
1. 1 2
  2. 1 8
  3. 2 4
  4. 3 6



- 3-27. What device is used to direct floss in between abutments and beneath pontics?
1. Toothpick
  2. Oral irrigator
  3. Floss threader
  4. Interdental proximal brush
- 3-28. To what surfaces on a tooth will pit and fissure sealants bond?
1. Facial and lingual
  2. Mesial and distal
  3. Cusp and mamelons
  4. Depressions and grooves
- 3-29. Sealants are highly effective in preventing pit and fissure caries in which of the following teeth?
1. Premolars and molars
  2. Premolars and incisors
  3. Incisors and molars
  4. All of the above
- 3-30. A rubber dam is the only method of isolation to be used for the application of pit and fissure sealants.
1. True
  2. False
- 3-31. What percent of phosphoric acid solution is used to etch teeth for pit and fissure sealants?
1. 10 to 20
  2. 20 to 30
  3. 30 to 50
  4. 90 to 100
- 3-32. What type of appearance will the area of a tooth have that has been etched, washed, and dried?
1. Smooth
  2. Frosted
  3. Pitted
  4. Dark
- 3-33. Which of the following is the most common reason for sealant failure?
1. Expired material
  2. Insufficient curing time
  3. Contamination of the material
  4. Contamination of the etched surface
- 3-34. Operative dentistry is concerned with the prevention and treatment of defects of what tooth surfaces?
1. Enamel and cementum
  2. Enamel and dentin
  3. Dentin and cementum
  4. Cementum only
- 3-35. Which of the following instruments is used primarily to remove debris from tooth cavities?
1. Hoes
  2. Chisels
  3. Hatchets
  4. Spoon excavators
- 3-36. An even-numbered gingival margin trimmer is designed for use on which of the following tooth surfaces?
1. Mesial
  2. Distal
  3. Facial
  4. Lingual
- 3-37. An odd-numbered gingival margin trimmer is designated for use on which of the following tooth surfaces?
1. Mesial
  2. Distal
  3. Facial
  4. Lingual
- 3-38. What type of working end does an amalgam carrier have for transportation?
1. Solid
  2. Layered
  3. Pointed
  4. Hollow
- 3-39. An amalgam condenser is often referred to as which of the following instruments?
1. Carvers
  2. Burnishers
  3. Pluggers
  4. Carriers

- 3-40. Which of the following instruments is designed for carving proximal tooth surfaces?
1. Tanner #5
  2. #1/2 Hollenback
  3. Frahm 2/3
  4. Cleoid-discoid
- 3-41. Which of the following advantages will occur to composite restorations when using a plastic instrument?
1. Will not discolor
  2. Will not bend
  3. Will not melt
  4. Will not break
- 3-42. What number spatula is used to mix small quantities of cement?
1. 313
  2. 322
  3. 324
  4. 324A
- 3-43. What length needle measured in inches is normally used for mandibular injections?
1. 1 1/4
  2. 1 3/4
  3. 1 7/8
  4. 1 13/16
- 3-44. The working end of a rubber dam punch is designed with which of the following mechanisms?
1. Plunger and spindle
  2. Plunger and wheel
  3. Wheel and spindle
  4. Spindle and clamp
- 3-45. A "W" prefix on a rubber dam clamp indicates which of the following designs?
1. Without clamp
  2. Without wrapper
  3. Without slipping
  4. Without wings
- 3-46. Which of the following rubber dam frames is the most popular?
1. "A" frame
  2. Young
  3. Wizard
  4. Woodbury
- 3-47. What type of material is always tied around a rubber dam clamp before placement in the mouth?
1. Floss
  2. Dental chain
  3. Rubber latex
  4. Clamp retriever
- 3-48. Which of the following types of matrix bands is most commonly used in restorative dentistry?
1. Wide #2
  2. Junior #13
  3. Precontoured
  4. Straight #1
- 3-49. Extensions on the Wide #2 matrix bands are known by which of the following terms?
1. Bumps
  2. Aprons
  3. Wings
  4. Circles
- 3-50. Which of the following is the most commonly used matrix retainer?
1. Universal #1
  2. Universal adult
  3. Universal straight
  4. Universal contra-angled
- 3-51. Wood or clear plastic wedges measure about how long in length?
1. 1 inch
  2. 1/2 inch
  3. 3/4 inch
  4. 1/4 inch
- 3-52. The operator's zone for a right handed dentist is located between which of the following positions?
1. 1 and 3 o'clock
  2. 2 and 4 o'clock
  3. 5 and 8 o'clock
  4. 8 and 11 o'clock
- 3-53. The assistant's zone for a right handed dentist is located between which of the following positions?
1. 1 and 3 o'clock
  2. 2 and 4 o'clock
  3. 5 and 8 o'clock
  4. 8 and 11 o'clock

- 3-54. The transfer zone is located between which of the following positions?
1. 8 to 11 o'clock
  2. 2 to 4 o'clock
  3. 3 to 6 o'clock
  4. 4 to 8 o'clock
- 3-55. The static zone is located between which of the following positions?
1. 8 to 11 o'clock
  2. 11 to 1 o'clock
  3. 11 to 2 o'clock
  4. 4 to 8 o'clock
- 3-56. How many inches should the dentist's eyes be from the treatment site if the patient is properly positioned?
1. 5 to 12
  2. 14 to 16
  3. 18 to 36
  4. None of the above
- 3-57. In what zone will the instrument exchange between the dentist and the assistant take place?
1. Operator's
  2. Assistant's
  3. Transfer
  4. Static
- 3-58. Dental materials are exchanged between the dentist and the assistant in what zone?
1. Operator's
  2. Assistant's
  3. Transfer
  4. Static
- 3-59. The needle end of a carpule is sealed with a rubber membrane held in place by what type of material?
1. Metal band
  2. Rubber band
  3. Copper band
  4. Plastic band
- 3-60. If you must recap a needle, what technique, if any, should be used?
1. One-handed scoop
  2. Two-handed scoop
  3. Twist and turn scoop
  4. None
- 3-61. What device is used to remove blood, pus, saliva, and debris from the oral cavity?
1. Low-volume ejector
  2. High-volume ejector
  3. High-volume evacuator
  4. High-volume aspirator
- 3-62. What type of cavity is present when three or more surfaces are involved?
1. Large
  2. Small
  3. Medium
  4. Complex
- 3-63. When the dentist has finished removing the tooth structure in a cavity preparation, what type of feeling will the dentin have when felt by an explorer?
1. Firm
  2. Loose
  3. Brittle
  4. Semi-hard
- 3-64. What is the last cutting step in the preparation of the cavity?
1. Finishing the tooth walls
  2. Finishing the dentin walls
  3. Finishing the enamel walls
  4. Finishing the occlusal walls
- 3-65. Stubborn particles of debris may be removed from a cavity preparation by which of the following materials?
1. Alcohol
  2. 2 x 2 gauze
  3. 4 x 4 gauze
  4. Small cotton pellet
- 3-66. What two materials are used in a cavity preparation to protect the pulp?
1. Bases and resins
  2. Fluoride and amalgam
  3. Bases and cavity liners
  4. Cavity liners and amalgam
- 3-67. What material is used to seal the dentinal tubules to help prevent microleakage in a cavity preparation?
1. Bases
  2. Cements
  3. Amalgam
  4. Cavity varnish

- 3-68. When the dentist is making the final adjustment to the matrix, which of the following steps should the dental assistant be preparing?
1. Changing the bur in the hand piece
  2. Placing the precapsulated amalgam in the amalgamator
  3. Charting the completed restoration in the dental record
  4. All of the above
- 3-69. What instrument will the dentist use to bring any excess mercury from the amalgam to the top of the restoration?
1. Carver
  2. Hatchet
  3. Burnisher
  4. Mouth mirror
- 3-70. What BUMED instruction contains information on the Mercury Control Program?
1. 6260.30
  2. 6260.20
  3. 6360.30
  4. 6360.20
- 3-71. Which of the following materials may be used to remove any roughness or overhang of an amalgam restoration in the proximal area?
1. Dental tape
  2. Dental floss
  3. Metal filing strip
  4. Plastic filing strip
- 3-72. Which of the following composite resins is available for use in operative dentistry?
1. Hybrid
  2. Microfilled
  3. Macrofilled
  4. All of the above
- 3-73. What composite shade will appear if the tooth becomes dehydrated?
1. Darker
  2. Lighter
  3. Transparent
  4. Chalky white
- 3-74. What type of matrix may be placed on the tooth before the acid etching procedure begins?
1. Wood
  2. Metal
  3. Rubber
  4. Celluloid
- 3-75. Glass ionomer cement will bond directly with which of the following tooth surfaces?
1. Enamel
  2. Dentin
  3. Cementum
  4. All of the above

# ASSIGNMENT 4

Textbook Assignment: "Oral Surgery Assistance," chapter 5, pages 5-1 through 5-27; and "Periodontic Assistance," chapter 6-1 through 6-17.

---

- 4-1. Which of the following terms is used to describe the extraction of teeth in oral surgery?
1. Exodontics
  2. Endodontics
  3. Extrodontics
  4. Yankodontics
- 4-2. Which of the following Standard Forms should be used when informed consent is required?
1. 515
  2. 522
  3. 532
  4. 542
- 4-3. To control pain and anxiety, which of the following basic levels of anesthesia are administered?
1. Local, unconscious sedation, and general
  2. Conscious sedation, general, and infiltration
  3. General, local, and gas
  4. General, local, and conscious sedation
- 4-4. Which of the following oral surgery procedures are the three types of tooth extractions?
1. Simple, uncomplicated, impacted
  2. Exostosis, simple, complicated
  3. Impacted, simple, complicated
  4. Complicated, simplex, impacted
- 4-5. Which of the following types of extraction involves removal of a tooth that is partially or completely covered by bone and soft tissue?
1. Simple
  2. Impacted
  3. Complicated
  4. Uncomplicated
- 4-6. Which of the following types of extraction involves removal of a tooth or root that does not require bone removal or sectioning?
1. Simple
  2. Impacted
  3. Complicated
  4. Uncomplicated
- 4-7. Which of the following types of extraction involves removal of a tooth or root that requires surgical sectioning and/or bone removal?
1. Simple
  2. Impacted
  3. Complicated
  4. Uncomplicated
- 4-8. What type of oral surgery procedure involves the contouring of the alveolar structures?
1. Exostosis
  2. Frenectomy
  3. Osteotomy
  4. Alveoloplasty
- 4-9. What oral surgery procedure will be performed on a patient who has a fractured mandible or maxilla?
1. Exostosis
  2. Frenectomy
  3. Osteotomy
  4. Alveoloplasty
- 4-10. What oral surgery procedure will involve the surgical removal of bony growths projecting past the normal contour of a bony surface?
1. Exostosis
  2. Frenectomy
  3. Osteotomy
  4. Alveoloplasty

- 4-11. What oral surgery procedure involves the removal of a malattached facial or lingual frenum?
1. Exostosis
  2. Frenectomy
  3. Osteotomy
  4. Alveoloplasty
- 4-12. What Standard Form does a dentist submit to an oral histopathology center for a submission of an oral biopsy?
1. 505
  2. 510
  3. 513
  4. 515
- 4-13. Which of the following oral surgery procedures involves the removal of devitalized portions of bone that have separated from the adjacent bone?
1. Implant
  2. Sequestrectomy
  3. Incision and drainage
  4. Foreign body removal
- 4-14. Which of the following conditions occurs when a blood clot does not form or dislodges from a tooth socket?
1. Exostosis
  2. Alveoloplasty
  3. Alveolar osteitis
  4. Granulation osteitis
- 4-15. Which of the following tongue and cheek retractors is commonly used in oral surgery procedures?
1. Fraizer
  2. East west
  3. Minnesota
  4. Curved Kelly
- 4-16. In addition to beaver style, which of the following surgical scalpel handles is commonly used in oral surgery procedures?
1. # 3
  2. #10
  3. #11
  4. #12
- 4-17. Which of the following silk suture materials is most commonly used for the oral mucosa?
1. 1-0
  2. 2-0
  3. 3-0
  4. 4-0
- 4-18. Tissue forceps have two small sharp pointed extensions that form which of the following shapes when in the closed position?
1. W
  2. X
  3. Y
  4. Z
- 4-19. What type of surgical instrument is sharp and spoon-shaped and used to clean out infected cavities in bone and remove debris from the tooth sockets?
1. Malar
  2. Rongeur
  3. Chisels
  4. Curettes
- 4-20. What type of surgical forceps is used to trim projecting, uneven, or overhanging bone?
1. #65
  2. #286
  3. Rongeur
  4. Hawkbill
- 4-21. What type of surgical elevator is used to separate a bone or tooth from the fibrous membrane?
1. Spade
  2. Minnesota
  3. Periosteal
  4. Straight root
- 4-22. What type of straight root elevator has the smallest working end?
1. 7 3
  2. 9 2
  3. 34 S
  4. 301

- 4-23. In which direction are the beaks of maxillary forceps angled from the curvature of the handles?
1. Away
  2. Same
  3. Vertical
  4. Horizontal
- 4-24. In what direction are the beaks of mandibular forceps angled from the curvature of the handles?
1. Same
  2. Away
  3. Vertical
  4. Horizontal
- 4-25. What letter-shaped forceps are used on the mandibular arch?
1. L and I
  2. C and S
  3. C and L
  4. S, I, and Z
- 4-26. What letter-shaped forceps are used on the maxillary arch?
1. L and I
  2. C and S
  3. C and L
  4. S, I and 2
- 4-27. What type of surgical equipment is used to protect the dentist and the patient from the long shaft of surgical burs?
1. Bur rings
  2. Bur guards
  3. Bur holders
  4. Bur wrappers
- 4-28. On what type of surgical stand will the circulating assistant place the surgery tray?
1. Oval
  2. Nayo
  3. Tayo
  4. Mayo
- 4-29. When performing surgery on the maxillary arch, what degree angle should the patient's alaragus line be to the floor?
1. 35
  2. 45
  3. 55
  4. 65
- 4-30. At least how many minutes should it take to complete a surgical scrub of a patient's face?
1. 1
  2. 2
  3. 3
  4. 4
- 4-31. You should scrub at least how many inches above your elbow when performing a surgical scrub of your hands?
1. 1
  2. 2
  3. 3
  4. 4
- 4-32. When performing gloving procedures, what member of the surgical team opens the packages of disposable sterile gloves?
1. Dentist
  2. Scrub assistant
  3. Surgical assistant
  4. Circulating assistant
- 4-33. When following the rules of the aseptic technique, in what position should you always keep your hands?
1. Above your head
  2. Above your waist
  3. Above your heart
  4. Above your shoulders
- 4-34. To control bleeding, what is the minimum amount of minutes a pressure pack may remain in place?
1. 10
  2. 20
  3. 30
  4. 40

- 4-35. If adequate healing has taken place, nylon or silk sutures may be removed after how many minimum days following surgery?
1. 1
  2. 2
  3. 3
  4. 4
- 4-36. Which of the following supportive structures is/are part of the periodontium?
1. Gingiva
  2. Alveolar bone
  3. Periodontal ligaments
  4. All of the above
- 4-37. Damage to the periodontium is called what type of disease?
1. Gingival
  2. Periapical
  3. Periodontal
  4. Periodontalism
- 4-38. The primary function of periodontal treatment is the elimination of what type of periodontal condition?
1. Pockets
  2. Calculus
  3. Gingivitis
  4. Malposed teeth
- 4-39. An inflammatory disease confined to the gingiva is termed as what type of periodontal condition?
1. Bone loss
  2. Gingivitis
  3. Periodontitis
  4. Marginal periodontitis
- 4-40. Inflammatory diseases that damage the deep supporting structures of the periodontium are classified as what type of periodontal condition?
1. Bone loss
  2. Gingivitis
  3. Periodontitis
  4. Marginal periodontitis
- 4-41. For successful periodontal treatment, a patient must be willing to accept which of the following conditions?
1. Treatment
  2. Requirements
  3. Good oral hygiene
  4. All of the above
- 4-42. Periodontal treatment is contraindicated if a patient displays which of the following responses?
1. Negative attitude
  2. Positive attitude
  3. Good flossing technique
  4. Good brushing technique
- 4-43. On what NAVMED form are the results of a periodontal examination charted?
1. 6600/1
  2. 6600/2
  3. 6630/3
  4. 6630/4
- 4-44. What are the most important findings in the periodontal examination?
1. Probing depths
  2. Mobility of teeth
  3. Amount of bleeding
  4. Brushing and flossing techniques
- 4-45. What color pencils are used on the front section of the Periodontal Chart?
1. Blue and red only
  2. Black and yellow
  3. Blue, red, and orange
  4. Black, blue, and red
- 4-46. When performing a periodontal examination, how many total measurements on each tooth will a dentist make when measuring for pocket depth?
1. 1
  2. 2
  3. 6
  4. 8



- 4-47. How many total classes are used to describe and record mobility?
1. 1
  2. 2
  3. 3
  4. 4
- 4-48. When using a periodontal probe, an angled shank places the working end at about what degree of an angle in relation to the handle?
1. 15
  2. 45
  3. 55
  4. 65
- 4-49. The scored millimeter markings on a periodontal probe can range from what minimum to what maximum increments?
1. 1 to 8
  2. 2 to 8
  3. 1 to 9
  4. 1 to 10
- 4-50. A furcation probe is designed to help determine the extent of what type of bone loss?
1. Apical
  2. Vertical
  3. Horizontal
  4. Interradicular
- 4-51. Which of the following actions is the objective of scaling calculus from the tooth surface?
1. Shaving
  2. Removing
  3. Releasing
  4. Peeling
- 4-52. Sickle scalers with straight shanks are designed to adapt to which of the following teeth in the mouth?
1. Anterior
  2. Posterior
  3. Both 1 and 2 above
  4. Distal-facial
- 4-53. Sickle scalers with contra-angled shanks are designed to adapt to which of the following teeth in the mouth?
1. Anterior
  2. Posterior
  3. Both 1 and 2 above
  4. Distal-facial
- 4-54. What are the two basic types of curettes?
1. Sickle and jacquette
  2. Universal and McCall's
  3. Universal and Columbia
  4. Universal and area specific
- 4-55. Which of the following materials is/are used to make special scalers for cleaning the abutments of dental implants?
1. Plastic only
  2. Nonmetallic only
  3. Both 1 and 2 above
  4. Gutta-percha
- 4-56. A periosteal elevator is designed to retract what type of tissues?
1. Hard
  2. Delicate
  3. Oral mucosa
  4. Periodontal
- 4-57. Periodontal knives are designed to make initial incisions for which of the following types of periodontal procedures?
1. Gingivoplasty and gingivectomy
  2. Osseous and root amputations
  3. Periodontal flaps
  4. Hemisection
- 4-58. Periodontal surgery curettes and sickles are designed to remove what type of tissue?
1. Hard
  2. Delicate
  3. Gingival
  4. Granulation and fibrous

- 4-59. To recontour the bone during periodontal surgery, the dentist may use which of the following periodontal surgery instruments?
1. Rongeurs and files
  2. Rongeurs and curettes
  3. Chisels, hoes, and files
  4. Chisels, curettes, and sickles
- 4-60. Which, if any, of the following advantages occurs when using the electrosurgery apparatus?
1. Painless surgery
  2. Control of bleeding
  3. Control of tissue removal
  4. None of the above
- 4-61. Which of the following are the two types of occlusal equilibration?
1. Complete and limited
  2. Finished and partial
  3. Uncompleted and unlimited
  4. Unrestricted and unlimited
- 4-62. When the dentist is performing an occlusal adjustment, which of the following materials is/are used to wipe off the marks and keep the teeth dry?
1. Sterile gloves
  2. Gauze sponges
  3. Cotton pellets
  4. All of the above
- 4-63. What type of sensitivity is reduced or eliminated when performing root desensitization procedures?
1. Nerve
  2. Enamel
  3. Cementum
  4. Dentinal
- 4-64. A periodontal flap is a technique used in an attempt to correct what type of defect?
1. Bone
  2. Osseous
  3. Gingival
  4. Tuberosity
- 4-65. Osseous lesions will appear interproximally as what shaped defect?
1. Flat
  2. Grape
  3. Saucer
  4. Triangular
- 4-66. What type of treatment is required before a root amputation?
1. Operative
  2. Endodontic
  3. Oral Surgery
  4. Prosthodontic
- 4-67. Most periodontal dressings will stay in place for how many maximum amount of days before removal?
1. 1
  2. 2
  3. 3
  4. 7
- 4-68. What type of appearance will have a sharp cutting edge that does not reflect light?
1. Line
  2. Glare
  3. Double line
  4. Rounded line
- 4-69. What type of appearance will have a dull edge that reflects light?
1. Line
  2. Glare
  3. Double line
  4. Square line
- 4-70. What type of sharpening stone, if any, is fairly course, cuts rapidly, and is used primarily for initial sharpening of very dull instruments?
1. Arkansas
  2. White
  3. Ruby
  4. None

4-71. What type of sharpening stone, if any, has a fine grit and is used to attain a sharp edge?

1. Arkansas
2. White
3. Ruby
4. None

4-72. Which of the following number of cutting edges require sharpening on a Kirkland knife?

1. 1
2. 2
3. 3
4. 4

4-73. Which of the following number of cutting edges require(s) sharpening on McCall curettes?

1. 1
2. 2
3. 3
4. 4

4-74. Which of the following number of cutting edges require(s) sharpening on sickle scalers?

1. 1
2. 2
3. 3
4. 4

4-75. Which of the following number of cutting edges require(s) sharpening on a hoe scaler?

1. 1
2. 2
3. 3
4. 4

# ASSIGNMENT 5

Textbook Assignment: "Endodontic Assistance," chapter 7, pages 7-1 through 7-16; and "Prosthodontic Assistance," chapter 8, pages 8-1 through 8-35.

- 
- 5-1. Endodontic treatment is also known as what type of therapy?
1. Pulp
  2. Nerve
  3. Root canal
  4. Apicoectomy
- 5-2. What is the primary purpose of endodontics?
1. To relieve pain
  2. To extract teeth
  3. Preserve the pulp and periapical tissues
  4. Treatment of diseases of the pulp and periapical tissues
- 5-3. If injured pulpal tissue undergoes necrosis, which of the following situations occur?
1. Pulp dies
  2. Pulp lives
  3. Pulp is transplanted
  4. Pulp is irritated
- 5-4. Which, if any, of the following is NOT a cause of an injured dental pulp?
1. Traumatic blows
  2. Thermal irritation
  3. Chemical irritation
  4. None of the above
- 5-5. The diagnosis of pulp and periapical conditions occur in what phase of treatment?
1. During the treatment only
  2. After the treatment only
  3. Both 1 and 2 above
  4. Before the treatment
- 5-6. Signs of discolored teeth, crown fracture, and gross caries can be found during which of the following procedures?
1. Dental history exam
  2. Clinical examination
  3. Thermal sensitivity test
  4. Percussion test
- 5-7. The presence of a dark area on a radiograph surrounding the apex of the root is also referred to by what other term?
1. Dental caries
  2. Periodontal abscess
  3. Type I fracture
  4. Radiolucency
- 5-8. The sensation of a slight tingling or warm feeling is felt during which of the following diagnostic tests?
1. Cold test
  2. Percussion
  3. Pulp testing
  4. Selective anesthesia
- 5-9. During a cold test, if the pulp is inflamed, the patient will experience what type of sensation to the cold?
1. Sharp
  2. Tingling
  3. Lingering
  4. Violent pain
- 5-10. If a patient experiences no response to a heat or cold test, the pulp is considered to have which of the following conditions?
1. Vital
  2. Mobile
  3. Inflamed
  4. Necrotic
- 5-11. A percussion test determines which of the following conditions?
1. Periapical inflammation
  2. Vitality
  3. Pulpitis
  4. Mobility
- 5-12. What type of application is used for palpation?
1. Anesthesia
  2. Pulp tester
  3. Mouth mirror
  4. Finger pressure

- 5-13. Which of the following tests involves the movement of tooth between the handles of two instruments?
1. Mobility
  2. Palpation
  3. Percussion
  4. Transillumination
- 5-14. Transillumination is most effective on which of the following teeth?
1. Anterior
  2. Posterior
  3. Deciduous
  4. Permanent
- 5-15. Placing a pulp cap over a layer of remaining dentin is referred to by what term?
1. Pulpotomy cap
  2. Direct pulp cap
  3. Partial pulp cap
  4. Indirect pulp cap
- 5-16. What type of therapy consists of internal debridement, cleaning, shaping, and permanent filling?
1. Pulpotomy
  2. Pulpectomy
  3. Root canal
  4. Apicoectomy
- 5-17. The surgical removal of the pulp chamber is known by which of the following terms?
1. Pulpectomy
  2. Pulpotomy
  3. Apicoectomy
  4. Incision and drainage
- 5-18. What is the procedure called when the entire pulp is removed?
1. Completed Pulpotomy
  2. Pulpal removal
  3. Pulpectomy
  4. Apicoectomy
- 5-19. What type of acute abscess requires an incision and drainage to eliminate infection along with endodontic treatment?
1. Periradicular
  2. Periodontal
  3. Pulpal
  4. Periapical
- 5-20. A broken instrument lodged in the root canal preventing a complete filling will require what type of treatment?
1. Instrumentectomy
  2. Apicoectomy
  3. Pulpotomy
  4. Pulpectomy
- 5-21. What method is used to seal the apical end of the root canal in conjunction with an apicoectomy?
1. Periapical curettage
  2. Calcified root canal filling
  3. Root amputation
  4. Retrograde filling
- 5-22. Paper points are used in endodontics for which of the following reasons?
1. To deliver medications to the canal
  2. To dry out the root canals
  3. To measure working distance
  4. To remove the pulp
- 5-23. Which of the following is NOT an advantage for using gutta-percha points for root canal restorative materials?
1. Poor heat conductor
  2. High thermal expansion
  3. Radiopaque
  4. Shrinks when used with a solvent
- 5-24. Endodontic explorers are used for which of the following reasons?
1. Locate canal openings
  2. Lateral condensation
  3. Enlarge pulp canal
  4. Pulp removal
- 5-25. What is the major difference between endodontic and cotton forceps?
1. Size
  2. Made of rubber
  3. Ends are grooved
  4. Angle of the working end
- 5-26. What symbol is used to identify barbed broaches?
1. Six-pointed star
  2. Eight-pointed star
  3. Ten-pointed star
  4. Six-rings

- 5-27. Which of the following instruments is used to enlarge the pulp canal?
1. Broaches
  2. Endodontic explorer
  3. Paper points
  4. Reamers
- 5-28. Which of the following are types of root canal files?
1. G and H
  2. H and F
  3. H and K
  4. K and J
- 5-29. What is the number of the Gates-Glidden drill that is rarely used?
1. One
  2. Two
  3. Three
  4. Four
- 5-30. What are the two types of endodontic condensers?
1. Plugger/woodsen
  2. Woodsen/vertical condenser
  3. Plugger/spreader
  4. Spreader/woodsen
- 5-31. Which of the following materials prevents injury to the apex of the root and periapical tissues?
1. Rubber dam
  2. Lentulo spiral
  3. Stops
  4. K files
- 5-32. What type of rubber dam frame saves valuable time when exposing radiographs?
1. Metal
  2. Young's
  3. U-shaped
  4. Radiolucent
- 5-33. Which of the following solutions is most frequently used for irrigation of the root canal?
1. Sterile saline
  2. Hydrogen peroxide
  3. Root canal solution
  4. Sodium hypochlorite
- 5-34. The length of an endodontic treated tooth is measured using which of the following rulers?
1. Standard
  2. Endodontic millimeter
  3. Endodontic centimeter
  4. Endodontic inch
- 5-35. How are rubber stops placed on files and reamers?
1. Right angle
  2. Oblique angle
  3. Vertical angle
  4. Horizontal angle
- 5-36. What portion of the master cone is coated with cement?
1. Apical first
  2. Apical second
  3. Apical third
  4. Apical fourth
- 5-37. The excess length of the gutta-percha is removed by which of the following instruments?
1. Scalpel
  2. Heated file
  3. Iris scissors
  4. Heated instrument
- 5-38. Prosthodontic treatment is concerned primarily with replacing missing teeth with what type of substitute?
1. Plastic
  2. Permanent
  3. Artificial
  4. Non-permanent
- 5-39. Interacoronar restorations fit on what portion of a tooth?
1. Around
  2. Bottom
  3. Into
  4. Onto
- 5-40. Extracornar restorations fit on what portion of a tooth?
1. Around
  2. Bottom
  3. Into
  4. Onto

- 5-41. Artificial crowns cover what coronal portion of the tooth?
1. Half
  2. Quarter
  3. One third
  4. More than half
- 5-42. The part of the post that protrudes from the root canal is called what type casting?
1. Veneer
  2. Anchor
  3. Core
  4. Fixed
- 5-43. A pontic suspended from only one retainer is held in place by which of the following methods?
1. Hanging
  2. Connecting
  3. Suspension
  4. Cantilevered
- 5-44. A rigid, temporary restoration that replaces missing teeth is classified as what type of prosthesis?
1. Interim fixed partial denture
  2. Fixed partial denture
  3. Partial denture
  4. Fixed splint
- 5-45. What type of removable prosthesis replaces all of the natural teeth in an arch?
1. Round-house
  2. Complete denture
  3. Maryland bridge
  4. Partial denture
- 5-46. What type of partial denture is made for insertion immediately following the surgical removal of natural teeth?
1. Surgical
  2. Temporary
  3. Removable
  4. Immediate
- 5-47. Which of the following dental alloys is NOT a classification type?
1. Precious
  2. Semiprecious
  3. Seminoble
  4. Nonprecious
- 5-48. Alginate is also known as which of the following impression materials?
1. Irreversible hydrocolloid
  2. Reversible hydrocolloid
  3. Synthetic hydrocolloid
  4. Silicone hydrocolloid
- 5-49. What specific time period will Type-I fast set alginate gel?
1. 1 to 2 minutes
  2. 2 to 3 minutes
  3. 3 to 4 minutes
  4. 4 to 5 minutes
- 5-50. Which of the following consistency types is NOT a rubber impression material?
1. Light bodied
  2. Medium bodied
  3. Regular bodied
  4. Heavy bodied
- 5-51. Which, if any, of the following material types is NOT an impression material?
1. Polysulfides
  2. Silicones
  3. Polyethers
  4. Collodion
- 5-52. Dental plaster will have a final set completed within approximately how many minutes?
1. 15
  2. 30
  3. 45
  4. 60
- 5-53. A dental stone mixture has an initial setting time of how many minimum and maximum minutes?
1. 29 to 36
  2. 22 to 29
  3. 15 to 22
  4. 8 to 15
- 5-54. What type of dental wax is used on impression trays?
1. Sticky
  2. Utility
  3. Baseplate
  4. Bite registration

- 5-55. What type of acrylic is used to make customized impression trays?
1. Tray
  2. Repair
  3. Orthodontic
  4. Crown and bridge
- 5-56. Separating media prevents which of the following actions?
1. Tooth distortion
  2. Tooth separation
  3. One material from bonding to another material
  4. One material from separating to another material
- 5-57. Tray adhesive ensures that impression material accomplishes which of the following results when taking impressions?
1. Material stays in the tray when removed from the mouth
  2. Material stays in the mouth when the tray is removed
  3. Material separates when removed from the tray.
  4. Tray separates when removed from the material
- 5-58. The alcohol torch is used for which of the following procedures?
1. Smoothing wax surfaces
  2. Setting teeth
  3. Waxing
  4. All of the above
- 5-59. Which type of alcohol is the best choice fuel for the alcohol torch?
1. Isopropyl
  2. Methyl
  3. Denatured
  4. Rubbing
- 5-60. The dental cast trimmer is used to perform which of the following procedures?
1. Cutting cast in half
  2. Cutting off teeth
  3. Trimming teeth
  4. Trim and contour
- 5-61. The two basic types of impression trays available for use are which of the following?
1. Maxillary and mandibular
  2. Stock and custom
  3. Disposable and rimlock
  4. Rubber and plastic
- 5-62. The mixing bowl is used to mix which of following dental materials?
1. Rubber base
  2. Alginate only
  3. Dental stone only
  4. Both 2 and 3 above
- 5-63. The pneumatic curing unit has a normal curing time of (a) how many minutes and (b) at what psi?
1. (a) 60 (b) 50
  2. (a) 45 (b) 35
  3. (a) 30 (b) 20
  4. (a) 20 (b) 10
- 5-64. The vacuum adapter is used for the rapid fabrication of which of the following prosthetic appliances?
1. Custom trays
  2. Maryland bridges
  3. Complete dentures
  4. Fixed partial dentures
- 5-65. Which, if any, of the following materials does a dental vibrator move when pouring a cast?
1. Rubber base and alginate
  2. Dental plaster and stone
  3. Treatment liners and resins
  4. None of the above
- 5-66. An impression tray should have how many millimeters of space between the tray, teeth, and soft tissues when tried in?
1. 1 to 2
  2. 2 to 3
  3. 3 to 4
  4. 4 to 5
- 5-67. Where should your index finger be placed on the tray when breaking the seal formed by the alginate material on a maxillary impression?
1. Along the posterior border
  2. Along the facial border
  3. Along the lingual border
  4. Along the lateral border



- 5-68. When mixing dental stone for a cast, in which order should the materials be mixed?
1. Gypsum to powder
  2. Powder to gypsum
  3. Water to powder
  4. Powder to water
- 5-69. At least how many minutes should a first pour cast set before making the cast base?
1. 4 5
  2. 3 0
  3. 1 5
  4. 5
- 5-70. When trimming a dental cast, which area should be ground down first?
1. Top
  2. Side
  3. Bottom
  4. Back
- 5-71. A custom tray is made on which of the following types of cast?
1. Final
  2. Diagnostic
  3. Preliminary
  4. Prefabricated
- 5-72. When preparing a cast for a mouthguard, what maximum mm thickness should the cast base NOT exceed?
1. 8
  2. 2
  3. 6
  4. 4
- 5-73. How many inches should the splint material sag on a heated vacuum-forming machine?
1. 1 1/2 to 2
  2. 2 1/2 to 3
  3. 3 to 3 1/2
  4. 4 to 4 1/2
- 5-74. When performing a denture base repair, how many coats of tin foil substitute are painted on the dental cast?
1. One
  2. Two
  3. Three
  4. Four
- 5-75. Which of the following DD forms is used for dental laboratory work?
1. 2232
  2. 3222
  3. 2332
  4. 2322

# ASSIGNMENT 6

Textbook Assignment: "Dental Treatment Room Emergencies," chapter 9, pages 9-1 through 9-8; and "Forensic Dentistry," chapter 10, pages 10-1 through 10-26.

- 
- 6-1. Which of the following, if any, additional safety features should be included with dental safety patient glasses?
1. Tinted lenses
  2. Side shields
  3. Safety glasses straps
  4. None of the above
- 6-2. The normal body temperature of an adult ranges from which of the following degrees Fahrenheit?
1. 94 to 99
  2. 96 to 98
  3. 97 to 99
  4. 98 to 101
- 6-3. An adult's normal pulse rate per minute can range from which of the following beats per minute?
1. 40 to 60
  2. 60 to 80
  3. 80 to 100
  4. 100 to 120
- 6-4. What artery should you use to take a patient's pulse?
1. Temporal
  2. Facial
  3. Carotid
  4. Brachial
- 6-5. The minimum blood pressure occurs when the heart contracts.
1. True
  2. False
- 6-6. The maximum blood pressure occurs when the heart relaxes.
1. True
  2. False
- 6-7. What is the normal blood pressure range for the systolic reading?
1. 60 to 90
  2. 70 to 100
  3. 80 to 110
  4. 90 to 140
- 6-8. What is the normal blood pressure range for the diastolic reading?
1. 60 to 90
  2. 70 to 100
  3. 80 to 110
  4. 90 to 140
- 6-9. What is the normal cycle of an adult's range of respiration?
1. 8 to 12
  2. 12 to 15
  3. 15 to 18
  4. 18 to 20
- 6-10. An oxygen tank that provides approximately 78 liters of oxygen per minute for one-half hour has what cylinder size?
1. B
  2. C
  3. D
  4. E
- 6-11. A victim of respiratory and cardiac arrest must receive treatment within how many maximum minutes to prevent irreversible brain damage?
1. 5 to 7
  2. 2 to 3
  3. 3 to 5
  4. 4 to 6
- 6-12. What do the ABC's of CPR stand for?
1. Airway, Breath, Circumstances
  2. Airway, Bleeding, Circulation
  3. Airway, Breathing, Circulation
  4. Arteries, Bleeding, Condition
- 6-13. What person, if any, in the dental clinic is not required to be certified in the healthcare provider course for CPR?
1. Dentist
  2. Dental technicians
  3. X-ray technicians
  4. None of the above

- 6-14. What CPR certification course teaches non-healthcare personnel?
1. Heartsaver course
  2. CPR "E" course
  3. CPR "A" course
  4. Healthcare provider course
- 6-15. The hand-operated resuscitator allows the operator to do which of the following actions?
1. Perform proper chest compressions
  2. Perform abdominal thrust
  3. Rescue breath for a patient without mouth-to-mouth contact
  4. Both 2 and 3 above
- 6-16. At least how many rescuers are recommended to operate a hand-held resuscitator?
1. 1
  2. 2
  3. 3
  4. Both 2 and 3 above
- 6-17. Oxygen tanks are always painted what color?
1. Brown
  2. Blue
  3. Green
  4. Red
- 6-18. What is the normal flow rate in liters per minute when oxygen is administered?
1. 5
  2. 6
  3. 7
  4. 8
- 6-19. Which of the following safety precautions for oxygen supply is false?
1. Close all valves when the cylinder is not in use
  2. Always stand to the side of the cylinder
  3. No smoking in any area where oxygen is stored or in use
  4. Always secure cylinder(s) on their side in a proper storage rack
- 6-20. What is the treatment for angina pectoris?
1. Chest compressions and rescuing breathing
  2. Place patient in a 45-degree angle (sitting up)
  3. Administer 100 percent oxygen and one nitroglycerin tablet sublingually
  4. Both 2 and 3 above
- 6-21. What is the maximum amount of nitroglycerin tablets a patient may receive in a 15-minute period?
1. 6
  2. 2
  3. 3
  4. 5
- 6-22. A patient who shows the signs of restlessness, anxiety, weakness, anxiousness, dull expression, and disorientation is suffering from which of the following conditions?
1. Shock
  2. Hypoglycemia
  3. Hyperventilation
  4. Syncope
- 6-23. A patient who shows the signs of cyanosis, wheezing, coughing, and difficulty in breathing is suffering from what, if any, medical emergency?
1. Seizures
  2. Shock
  3. Asthma attack
  4. Hyperventilation
- 6-24. When treating syncope, you should place the patient's feet in what position?
1. Six o'clock
  2. 15° angle down
  3. Trendelenburg style
  4. 15° angle up
- 6-25. Anaphylactic shock usually occurs what period of time after the victim has been exposed?
1. Seconds
  2. Minutes
  3. Hours
  4. Days
- 6-26. After a patient has been anesthetized or premedicated with a drug, you should perform which of the following actions?
1. Perform basic life support
  2. Activate the clinic's emergency response team
  3. Place patient in Trendelenburg's position
  4. Observe patient and watch for signs of an adverse reaction

- 6-27. Forensic dentistry is defined as the branch of forensic medicine that applies to which of the following entities?
1. Dental knowledge to the Federal court system
  2. Dental knowledge to civil and criminal problems
  3. Dental knowledge to bite mark analysis
  4. Dental knowledge of insurance companies
- 6-28. The primary reason the Navy has been directed to establish forensic dental identification capability is to assure which of the following requirements?
1. To assist in the identification of human remains
  2. For any inheritance of the deceased's next of kin
  3. For any claim of insurance held by the victim
  4. To comply with State and Federal laws
- 6-29. Without positive identification, any inheritance and last will and testament could be delayed for how long?
1. Indefinitely
  2. Until the person is declared legally dead
  3. Up to 7 years
  4. Both 2 and 3 above
- 6-30. A graphic example of the psychological aspect of the need for forensic identification to the next of kin was experienced in which, if any, of the following situations?
1. Legal issues
  2. Medical issues
  3. Vietnam "missing in action"
  4. None of the above
- 6-31. Which of the following body characteristics is the most commonly used method to identify an individual?
1. Scars
  2. Tattoos
  3. Deformities
  4. Visual recognition
- 6-32. For many reasons, tattoos should be used as a primary means for positive identification.
1. True
  2. False
- 6-33. In the military, what type of personal item is used to specifically assist in identifying an individual?
1. Government credit card
  2. Command name tags
  3. Passports
  4. Dog tags
- 6-34. In a court of law, which of the following proofs of identity provides an acceptable positive identity of a deceased individual?
1. Skeletal remains
  2. Distinctive jewelry
  3. Drivers' license
  4. Tattoos
- 6-35. Of all the methods of ID, which of the following is the best known?
1. DNA analysis
  2. Fingerprints
  3. Personal effects
  4. Dental identification
- 6-36. Fingerprint ID is always acceptable in a court of law.
1. True
  2. False
- 6-37. DNA analysis is also known by which of the following terms?
1. DNA identification
  2. DNA evidence
  3. DNA marking
  4. DNA fingerprinting
- 6-38. Dental identification is a definitive means of positive identification of unknown human remains.
1. True
  2. False
- 6-39. Dental evidence tends to survive much better than which of the following other evidences?
1. Facial characteristics
  2. Soft tissue
  3. Fingerprints
  4. All of the above

- 6-40. Teeth that are unprotected by the soft tissues of the cheeks and lips, in rare instances, can be destroyed by fire if the minimum temperature exceeds which of the following degrees Fahrenheit?
1. 250
  2. 500
  3. 750
  4. 1000
- 6-41. Silver amalgam will resist temperatures up to what maximum degree Fahrenheit?
1. 1600
  2. 1700
  3. 1800
  4. 1900
- 6-42. Given sufficient data, it is possible that two sets of teeth can be identical.
1. True
  2. False
- 6-43. In an antemortem database, radiographs are considered what type of evidence?
1. Error free
  2. Material
  3. Hard
  4. Soft
- 6-44. Which of the following problems may delay the final determination of an identification?
1. Illegible dental records
  2. Adequate dental radiographs
  3. Adequate charting
  4. All of the above
- 6-45. When does postmortem identification occur?
1. During an annual examination
  2. During a separation examination
  3. After death
  4. Before death
- 6-46. When evaluating the post and antemortem records, discrepancies may be classified in what, if any, two broad categories?
1. Relative and comparison
  2. Relative and absolute
  3. Absolute and comparison
  4. None
- 6-47. Antemortem dental records detail dental conditions during which of the following times?
1. Before death
  2. After death
  3. Both 1 and 2 above
  4. At any time
- 6-48. Relative discrepancies between the antemortem and the postmortem dental exam findings can be explained by which of the following methods?
1. Exact match
  2. Human error
  3. Radiographic comparison
  4. Continued dental treatment
- 6-49. Which of the following items would best represent the person if the remains cannot be those of the individual under consideration?
1. Radiographic comparison
  2. Absolute inconsistencies
  3. Relative discrepancies
  4. Exact match
- 6-50. What type of comparison would the postmortem and antemortem radiographs show if a tooth restoration was the same in both?
1. Similarity
  2. Relative discrepancy
  3. Absolute inconsistency
  4. Exact match
- 6-51. What is the final and most important step in the dental ID process?
1. Classification
  2. DNA analysis
  3. Comparisons
  4. Charting
- A. Positive identification  
 B. Positive identification by charting only  
 C. Consistent with  
 D. Exclusion  
 E. Unidentified

**Figure 6-A.—Classification of the dental identification.**

**IN ANSWERING QUESTIONS 2-52 THROUGH 2-56, SELECT FROM FIGURE 6-A THE CLASSIFICATION USED TO ESTABLISH IDENTITY. YOU WILL USE ALL THE CLASSIFICATIONS IN FIGURE 6-A ONLY ONCE.**

- 6-52. The remains cannot be those of the suspect individual.
1. B
  2. C
  3. D
  4. E
- 6-53. The ID is based solely on the written dental record.
1. A
  2. B
  3. C
  4. D
- 6-54. No sufficient evidence to determine the identity of the individual.
1. B
  2. C
  3. D
  4. E
- 6-55. The forensic dentist is positive they have determined the ID of the individual.
1. A
  2. B
  3. C
  4. D
- 6-56. A good probability that the remains are those of the suspect person.
1. A
  2. B
  3. C
  4. D
- 6-57. Which of the following elements is part of the command/support?
1. Photographic
  2. Personal effects
  3. Medical radiology
  4. Graves registration
- 6-58. Which of the following elements is part of identification?
1. Dental
  2. Mortuary affairs
  3. Recovery/transportation
  4. Security
- 6-59. The dental team leader performs the same tasks as which of the following?
1. Dental registrar
  2. Public affairs officer
  3. Operations chief
  4. Oral surgeon
- 6-60. Which of the following dental team members will expose the maxilla and mandible for an examination?
1. Radiologist
  2. Oral surgeon
  3. Dental technician
  4. Dental team leader
- 6-61. Who protects all dental evidence coming into and going out of the dental area?
1. Security
  2. Dental registrar
  3. Dental team leader
  4. Inprocessing officer
- 6-62. Problems with access to dental structures arise most commonly from which of the following circumstances?
1. Plane crash victims
  2. Intact full body remains
  3. Partial body remains
  4. Chemical exposure victims
- 6-63. At least how many minutes is normally required to expose a complete series of postmortem remains?
1. 2 0
  2. 2 5
  3. 3 0
  4. 6 0
- 6-64. What type of x-ray developer is used to process forensic radiographs?
1. Large
  2. Small
  3. Manual
  4. Any type

- 6-65. When mounting forensic periapical or bitewing X-rays, which direction should the raised dot face?
1. Facing in
  2. Facing out
  3. Both 1 and 2 above
  4. Facing sideways
- 6-66. For film accountability, what does a green opaque film in the mount represent?
1. No radiograph is available for a particular area
  2. A faulty X-ray machine
  3. Not enough kVps
  4. Developer problems
- 6-67. What is the first step you do when you are performing a dental postmortem examination?
1. Dental X-rays
  2. Dental charting
  3. Entering victim in computer system
  4. Gentle cleaning of the dental remains
- 6-68. Postmortem charting should be done using which of the following item (s)?
1. Pen
  2. #2 pencil only
  3. Special postmortem blue pencil
  4. Both 2 and 3 above
- 6-69. At least how many members of the antemortem dental record staff should review each composite dental record?
1. One
  2. Two
  3. Three
  4. Four
- 6-70. What does "CAPMI" stand for
1. Computer Antemortem Program Management Information
  2. Computer and Postmortem Management Intelligence
  3. Computer Assisted Postmortem Identification
  4. Computer Antemortem Program Management Information
- 6-71. What is the last section in the dental forensic ID process?
1. Antemortem/Postmortem Records Comparison
  2. Antemortem Records Comparison
  3. Postmortem Records Comparison
  4. X-ray Comparison
- 6-72. What form summarizes the ID data during the antemortem/postmortem comparison?
1. Antemortem/postmortem summary sheet
  2. Forensic summary sheet
  3. Dental identification summary sheet
  4. CAPMI DOD summary sheet
- 6-73. Who is responsible to sign a forensic identification case out as a positive ID?
1. Identification Center chief
  2. Pathologist Center chief
  3. Dental team leader
  4. Any dentist
- 6-74. The antemortem composite dental record should be placed in the uncompleted file only if the full dentition was recovered.
1. True
  2. False
- 6-75. Most equipment and supplies for forensic operation can be maintained in which of the following types of storage areas?
1. Large box
  2. Mobile dental van
  3. Large supply locker
  4. Medium-size tackle box and canvas bags

